

Surgical Closure of Isolated Patent Ductus Arteriosus in Cenhosoa Antananarivo

Zakarimanana Lucas Randimbirina^{1*}, Harijaona Fanomezantsoa Randrianandrianina¹,
Tsirimalala Rajaobelison¹, Rija Mikhaël Miandrisoa², Hariniaina Ravaoavy³,
Toky Mamin'ny Aina Rajaonahary⁴, Andriamihaja Jean-Claude Rakotoarisoa⁵

¹Department of Cardiovascular Surgery, Faculty of Medicine of Antananarivo, University of Antananarivo, Antananarivo, Madagascar

²Department of Cardiology, Faculty of Medicine of Antananarivo, University of Antananarivo, Antananarivo, Madagascar

³Cardiovascular Disease Unit, Soavinandriana Hospital Center, Antananarivo, Madagascar

⁴Department of Vascular Surgery, Faculty of Medicine of Antananarivo, University of Antananarivo, Antananarivo, Madagascar

⁵Department of Thoracic Surgery, Faculty of Medicine of Antananarivo, University of Antananarivo, Antananarivo, Madagascar

Email: *lucaszakarimanana@gmail.com

How to cite this paper: Randimbirina, Z.L., Randrianandrianina, H.F., Rajaobelison, T., Miandrisoa, R.M., Ravaoavy, H., Rajaonahary, T.M.A. and Rakotoarisoa, A.J.-C. (2023) Surgical Closure of Isolated Patent Ductus Arteriosus in Cenhosoa Antananarivo. *World Journal of Cardiovascular Surgery*, 13, 111-119.

<https://doi.org/10.4236/wjcs.2023.137011>

Received: May 29, 2023

Accepted: July 7, 2023

Published: July 10, 2023

Copyright © 2023 by author(s) and

Scientific Research Publishing Inc.

This work is licensed under the Creative

Commons Attribution International

License (CC BY 4.0).

<http://creativecommons.org/licenses/by/4.0/>



Open Access

Abstract

Introduction: Patent ductus arteriosus (PDA) is a congenital heart disease whose seriousness lies in the risk of pulmonary hypertension, congestive heart failure and death. The aim of this study was to describe the surgical closure of an isolated patent ductus arteriosus (PDA) performed in Soavinandriana Teaching Hospital. **Methods:** This was a retrospective and descriptive study, during thirteen-years-period (January 2004 to December 2016), performed at Cardiac surgery unit of Soavinandriana Teaching Hospital, including all children underwent surgical closures of an isolated PDA. Demographic data, birth weight, clinical signs, diagnostic imaging, time between diagnosis and surgery and hospital left stays were analyzed. **Results:** A total of eighty-six children were recorded, including 21 males (24.42%) and 65 females (75.58%), giving sex ratio of 30%. The average age was 33.91 months. Children were born with a low birth weight in 12.79% of cases. PDA was symptomatic in 81.39%. The most circumstances of discovery were recurrent lung infections (31.40%), dyspnea (24.41%) and failure to thrive (19.76%). Echocardiography showed left ventricular dilatation (63.95%), pulmonary hypertension (73.25%). The ductus was large in 97.67% and the mean diameter was 5 mm. Chest X-ray showed cardiomegaly (97.67%) and increased pulmonary vascularity (86.04%). Mean delay of surgical procedures after diagnosis was 15.16 months. Surgical procedures consisted left posterolateral thoracotomy with a section and suture after clamping the ductus. Earlier postoperatives courses were simple in all children. The mean duration of hospitalization was 8.93 days. **Conclusion:** PDA

was most common large (97%) and symptomatic (81%) in our study. Surgical closure of an isolated PAD was the only surgical procedure of congenital heart cardiopathy available in Antananarivo.

Keywords

Echocardiography, Patent Ductus Arteriosus, Pediatrics, Surgery, Thoracotomy

1. Introduction

Patent ductus arteriosus (PDA) is a cardiac malformation which the ductus does not close in 3 months after birth. It's a usual cardiac malformation in premature birth. PDA is associated with increased mortality and various comorbidities including cardiac failure, need for respiratory support, bronchopulmonary dysplasia, pulmonary or intracranial hemorrhage, and necrotizing enterocolitis [1]. The prevalence of PDA was 81 infants per 10,000 live births and 45.2% in very low birth weight (VLBW) infants [2]. In Africa, PDA was seen in 57% of premature infants [3] and accounts for 25% of congenital heart disease [4]. The surgical management of PDA is still an open surgery by thoracotomy in most of sub-Saharan African countries if interventional cardiology takes more place in Western countries. The surgical closures of an isolated PDA are the only surgical procedures of congenital heart disease performed in Madagascar since 2004. However, there are no previous studies publishing the surgical closures of an isolated PDA in Madagascar. The aim of this study was to describe the surgical closures of an isolated PDA performed in Soavinandriana Teaching Hospital at Antananarivo.

2. Materials and Methods

This study was performed in Soavinandriana Teaching Hospital. It is a referral hospital in Antananarivo, receiving military patients with her families and civilian patients who needed cardiac and vascular surgery. Since 2004, missionary of doctors of the world have been performed surgery of an isolated PDA in Antananarivo Madagascar. Patients have been selected after consulting and performed echocardiography by cardiopaediatric team in Cenhosoa. All children who had an isolated PDA have been referred in Cardiac Surgery Unit for program for surgical closure of the ductus. In otherwise, children who had a complex congenital heart disease or an associated PDA with other cardiac malformation have been sent in France. Since 2016, Malagasy surgeons have been practiced the surgical closure of an isolated PDA without missionary. Performing the surgical closure of PDA solely by the Malagasy team reduces the waiting time for surgery by missionaries. We are currently trying to publish this study on PCA closure surgery performed with missionaries before publishing a study on sur-

gery performed by Malagasy surgeons without missionaries since 2016, which is currently under development. So, we conducted a retrospective and descriptive study after 13 years period (from January 2004 to December 2016) of practice of surgical closure of an isolated PDA in Malagasy children, performed at Soavindriana Teaching Hospital in Antananarivo. All children who underwent a surgical closure of an isolated patent ductus arteriosus during this period were included in this study. Demographic data, birth weight, clinical signs, diagnostic imaging, time between diagnosis and surgery and hospital left stays were analyzed. Data were collected from cardiopediatrician's consultation sheets, echocardiography reports, pre-anesthetic consultation sheets, operative reports and hospitalization records. Data were recorded with Microsoft excel 2016, then analyzed with SPSS 17.0 software. Data are presented as absolute values and frequency, mean and standard deviation and range according to the sample distribution.

3. Results

Eighty-six children were operated for surgical closure of an isolated PDA during our study period. The population of study consisted of 21 boys (24.42%) and 65 girls (75.58%), giving a sex ratio of 30%. The average age was 33.91 ± 1.03 months (ranging from 5 months to 168 months). Seventeen children were born prematurely (19.76%). Mean birth weight was 3.06 ± 0.19 kg. Nine children (10.47%) had low birth weight and two children (2.33%) had very low birth weight (**Table 1**). PDA was symptomatic in 70 cases (81.39%). The most common symptoms were recurrent lung infections (31.40%), dyspnea (24.41%) and failure to thrive (19.76%). PDA was asymptomatic in 18.60% of children whose diagnoses were made after echocardiography because of a heart murmur or cardiomegaly on routine chest X-ray. On clinical examination, cardiac auscultation revealed a systolo-diastolic heart murmur (97.67%) and a loud P2 in the second left intercostal space (73.25%). The electrocardiogram showed a normal trace in 17% of cases, left ventricular hypertrophy in 63% and biventricular hypertrophy in 13%. Echocardiography showed left ventricular dilatation (63.95%) and pulmonary hypertension (73.25%) (**Table 2**). The ductus was large in 78 cases (90.69%), with a mean diameter of 5 mm. Chest X-rays showed cardiomegaly (97%) and increased pulmonary vascularity (86%). The time from diagnosis to surgery was less than 12 months in 55 children (63.95%) (**Table 3**). The average waiting time for surgery was 15.16 months. Postoperative medical treatment often combined oxygenotherapy, antibiotics, analgesics and diuretics. All patients were operated by conventional surgery with a left posterolateral thoracotomy. Surgical procedures consisted of section and suture of the ductus after clamping. The ductus arteriosus was sutured using the Blalock-Taussig procedure with 5 - 0 or 6 - 0 prolene. **Figure 1** showed the sutured ductus arteriosus. Postoperative course was simple in all children. No postoperative deaths were recorded during hospitalization. The average hospital stay was 8.93 ± 0.14 days, ranging from 6 to 15 days.

Table 1. Birth weight and clinical signs of patients.

Birth weight and clinical signs		Frequencies (n = 86)	Percentage (%)
Birth weight (kg)	<1.5	2	2.33
	1.5 to 2.5	9	10.47
	2.5 to 4.3	71	82.55
	>4.3	4	4.65
Symptoms	Recurrent lung infection	27	31.40
	Dyspnea	21	24.41
	Repetitive cough	05	5.81
	Failure to thrive	17	19.76
	No symptom	16	18.60
Clinical findings	Murmur of the ductus	84	97.67
	Loud P2 in 2 nd left intercostal spaces	63	73.25

Table 2. Diagnostic imaging and diameter of ductus.

Diagnostic imaging/Diameter of ductus		Frequencies (n = 86)	Percentage (%)
X-ray	Cardiomegaly	84	97.67
	Increased pulmonary vascularity	74	86.04
	Normal x-ray	2	2.32
Echocardiography	Right ventricular hypertrophy	3	3.49
	Left ventricular hypertrophy	55	63.95
	Left ventricle dilatation	73	84.88
	Pulmonary hypertension	63	73.25
Diameter of ductus (mm)	≤3	8	9.30
	3 - 5	45	52.32
	6 - 9	27	31.39
	≥10	6	6.98

Table 3. Time between diagnosis and surgery and hospitalization left stay.

Time between diagnosis and surgery/Hospitalization left stay		Frequencies (n = 86)	Percentage (%)
Time between diagnosis and surgery (month)	0 - 11	55	63.95
	12 - 23	22	25.58
	24 - 35	3	3.48
	≥36	6	6.97

Continued

Hospitalization left stays (days)	≤7	3	3.48
	8 - 10	79	91.86
	>10	4	4.65

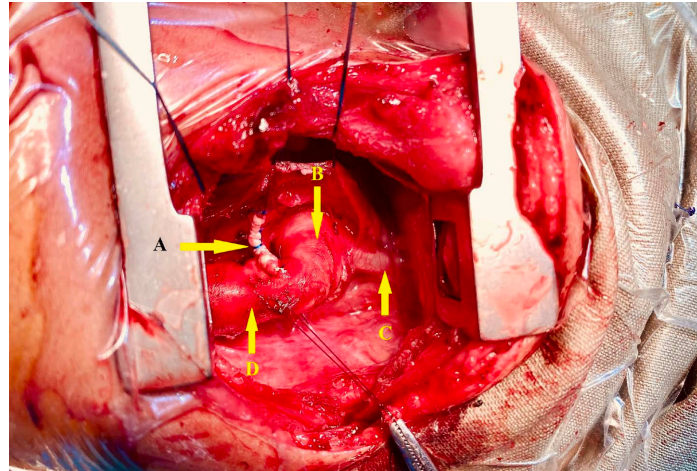


Figure 1. Peroperative image of closure of patent ductus arteriosus (A: sutured ductus arteriosus, B: aortic arch, C: left subclavian artery, D: descending aorta).

4. Discussion

The existence of congenital heart disease is reality in sub-Saharan African countries such as Madagascar. It remains a public health problem accounting for a significant mortality rate. The intersection of poverty, high fertility rates and limited access to care explains high morbidity and mortality rate due to congenital heart disease in low-and-middle-income countries such as sub-Saharan African countries [5]. Surgical management of congenital heart disease remains a challenge in sub-Saharan African countries because number of congenital cardiac surgeries performed in these regions is extremely low. It is estimated that only 3% of children with congenital heart disease can undergo surgery in sub-Saharan African population [6]. The truth prevalence of patent ductus arteriosus in sub-Saharan African population remains unknown. Some African authors have been showed the hospital prevalence of PDA. In Antananarivo, patent ductus arteriosus (14%) is the second isolated congenital heart disease after ventricular septal defect (17%) [7]. Few studies had described surgical closures of PDA in sub-Saharan African studies. But, there is no previous study published the surgical closures of patent ductus arteriosus in Madagascar.

The average age of children underwent surgical closures of PDA in sub-Saharan studies were different according to the study: 33 months in our study, 45 months in the study of Ba PS *et al.* [8], 7 years in the study of Onakpoya UU *et al.* [9] and 4 years in the study of Animasahun BA *et al.* [10]. The higher predominance of female in our population (75%) was still observed in other African studies such as Nyawawa ETM *et al.* (84%) [11], Ba PS *et al.* (63%) [8] and Onakpoya UU *et*

al. (87%) [9]. In recent meta-analysis, there is no sex differences in risk of developing PDA [12]. However, the risk of PDA in children born with prematurity had been often published in the literature [13]. In our study, 19% of children had been born in prematurity. There was an inverse relationship between the birth weight and the incidence of PDA [14]. PDA was diagnosed in 42% of infants with very low birth weight [15]. In our study, 9 children (10%) were born with low birth weight and 2 children (2%) with very low birth weight.

The diagnosis of symptomatic PDA was often discovered during recurrent tract infection such as bronchitis, dyspnea and failure to thrive. In our study PDA were symptomatic in 81% of cases which the commonest symptoms were recurrent lung infection (31%) and failure to thrive (19%). In the study of Onakpoya UU *et al.*, symptomatology was 75% of dyspnea, 75% of respiratory tract infection and 12% of failure to thrive [9]. In study of Ba PS *et al.*, bronchitis (63%) and dyspnea were the most common symptomatology of PDA [8]. Echocardiography is the gold standard imaging to make a confirmative diagnosis of PDA, to measure the transductal diameter, to diagnose an associated congenital heart defect, to estimate the shunt volume and to assess the hemodynamic significance [16]. In our practice, all children must be examined by cardiopaediatrics before underwent confirmation by echocardiography. ECG showed normal trace in 17% of cases, left ventricular hypertrophy in 63% of children and biventricular hypertrophy in 13% of cases. The results contrasted in the study of Tort M *et al.* which 63% of cases showed normal ECG [17].

The ductus is considered small at <1.5 mm, moderate when it ranges between 1.5 and 3 mm, and large if the dimension exceeds 3 mm [1]. The mean diameter of ductus in children population undergoing surgical closures of PDA were variable according study. Large PDA with significant hemodynamic must be close. In our study, the mean diameter of ductus was 5 mm and 37% were exceeded 5 mm. In Animasahun's study, mean diameter of PDA were 3 mm in group which treated by device closure and 8 mm in group which treated by surgical ligation [10]. According to Onakpoya UU *et al.* study, the majority of infants underwent transthoracic open ligation of PDA were presented a ductus with diameter exceeding 5 mm (62%) [9]. However, the study of Ba PS *et al.* showed a near result of our study with the mean diameter of ductus were 6 mm [8]. In the study of Tort M *et al.*, the ductus were large in 76% of patients and moderate in 17% of patients [17].

PDA symptomatic or large ductus with significant hemodynamic must treated in optimal delay to prevent pulmonary hypertension. Surgical closure is considered when medical treatment fails. But, time to make decision for surgical closure was different. In African sub-Saharan countries, the mean delayed between time of diagnosis and surgical closure was variable according study. In our study, mean delayed of surgical procedures after diagnosis was 15 months and 63% of children waited the surgical closures in first year of birth. In the study of Onakpoya UU *et al.*, 18 of children have their surgical closures within a week of diagnosis and 50% waited for 1 - 6 months since diagnosis [9]. In sub-Saharan

African countries, the most common reasons for delay of surgical closures were financial and treatment of ongoing respiratory infection.

In advanced countries, percutaneous treatment takes more place than left thoracotomy since 21st century [18]. But, open surgery with left postero-lateral thoracotomy remain the commonest surgical procedures to close the ductus in most sub-Saharan African countries. The ductus could be treated by ligation or double-clamping and dividing the ductus (earliest procedures). Now, the new procedures in western countries and other sub-Saharan African countries used transcatheter closure with coils or amplatzer duct occluder. In our practice, open surgery with double-clamping and suture of the ductus remain the only surgical procedure used to close all ductus. In Salmane's study, PDA closures were performed with the same surgical procedure of our result in 45% of patients [8]. In Animasahun's study, the surgical closures of PDA were performed by ligation (57%) and by using device PDA closure (42%) [10]. The study of Tort M *et al.* showed highest rate of ligation (89%) [17].

Postoperative course were simple in all children and no death was found during hospital length stay in our study. Postoperative complications were found in 31% of children in Onakpoya's study [9]. No postoperative death was found in the study of Ba PS *et al.* [8]. In the study of Nyawawa ETS *et al.*, the hospital death rate was 5% [11]. Our result could be explained that all cases were an isolated PDA.

Postoperative length stay varied with the type of surgery used to close the ductus. Thoracotomy needed usually more duration of hospitalization than percutaneous treatment. The length of stay was significantly higher in the surgical group (7.9 days) compared in the percutaneous group (1.3 days) ($p < 0.01$) [18]. The mean duration of hospitalization was 8 days in our study. It was longer than in the study of Ba PS *et al.* which the mean duration of hospitalization was 5 days [8]. In Onakpoya's study, postoperative hospital stay was under 5 days in 75% of patients [9]. The mean length of hospital stay was 5 days in the study of Tort M *et al.* [17]. In our practice, patient often discharged at 7 or 8 days in postoperative time after performed a control echocardiography.

5. Limitations

This study has limitations that could be taken into account in future research. The small sample size and monocentric nature of the study mean that we cannot draw any conclusions about the reality of isolated PCA closure surgery in Madagascar. In addition, the absence of systematic screening for asymptomatic forms of patent ductus arteriosus altered the sociodemographic and symptomatological aspects of our study.

6. Conclusion

Surgical closure of isolated PAD was the only surgical procedure of congenital heart diseases available in Antananarivo. PDA was symptomatic and large in most cases. The surgical results were satisfactory in our study.

Conflicts of Interest

The authors declare no conflicts of interest regarding the publication of this paper.

References

- [1] Arlettaz, R. (2017) Echocardiographic Evaluation of Patent Ductus Arteriosus in Preterm Infants. *Frontiers in Pediatrics*, **5**, Article No. 147. <https://doi.org/10.3389/fped.2017.00147>
- [2] Park, J., Yoon, S.J., Han, J., Song, I.G., Lim, J., Shin, J.E., *et al.* (2021) Patent Ductus Arteriosus Treatment Trends and Associated Morbidities in Neonates. *Scientific Reports*, **11**, Article No. 10689. <https://doi.org/10.1038/s41598-021-89868-z>
- [3] Soliman, R.M., Mostafa, F.A., Abdelmassih, A., Sultan, E. and Mosallam, D. (2020) Patent Ductus Arteriosus in Preterm Infants; Experience of a Tertiary Referral Neonatal Intensive Care Unit: Prevalence, Complications, and Management. *Egyptian Pediatric Association Gazette*, **68**, Article No. 34. <https://doi.org/10.1186/s43054-020-00046-8>
- [4] Damorou, F., Matey, K., Douti, N., Bantakpa, S., Goeh-Akue, E., Baragou, R. and Soussou, B. (2007) Persistence du canal artériel: Aspects épidémiologiques, circonstances de dépistage et prise en charge. *Journal de la Recherche Scientifique de l'Université de Lomé*, **9**, No. 2. <https://doi.org/10.4314/jrsul.v9i2.52457>
- [5] Zimmerman, M. and Sable, C. (2020) Congenital Heart Disease in Low- and Middle-Income Countries: Focus on Sub-Saharan Africa. *American Journal of Medical Genetics Part C: Seminars in Medical Genetics*, **184**, 36-46. <https://doi.org/10.1002/ajmg.c.31769>
- [6] Higashi, H., Barendregt, J.J., Kassebaum, N.J., Weiser, T.G., Bickler, S.W. and Vos, T. (2015) The Burden of Selected Congenital Anomalies Amenable to Surgery in Low- and Middle-Income Regions: Cleft Lip and Palate, Congenital Heart Anomalies and Neural Tube Defects. *Archives of Disease in Childhood*, **100**, 233-238. <https://doi.org/10.1136/archdischild-2014-306175>
- [7] Randimbirina, Z., Rajaobelison, T., Andriambarijaona, M.Y., Ravalisoa, M.L. and Rakotoarisoa, A. (2018) Profil épidémiologique, clinique et thérapeutique des cardiopathies congénitales à Antananarivo. *Annales Africaines de Médecine*, **12**, e3100-e3106.
- [8] Ba, P.S., Diatta, S., Gaye, M., Diop, M.S., Diagne, P.A., Dieng, P.A., *et al.* (2017) Surgery of Patent Ductus Arteriosus: 73 Cases in Dakar. *SAS Journal of Surgery*, **3**, 283-285.
- [9] Onakpoya, U.U., Ogunrombi, A.B., Aladesuru, A.O., Okeniyi, J.A., Adenekan, A.T. and Owojuyigbe, A.M. (2015) Trans-Thoracic Open Ligation of the Persistent Ductus Arteriosus in Ile-Ife, Nigeria. *Nigerian Journal of Cardiology*, **12**, 8-12. <https://doi.org/10.4103/0189-7969.148479>
- [10] Animasahun, B.A., Adekunle, M.O., Falase, O., Gidado, M.T., Kusimo, O.Y., Sanusi, M.O. and Johnson, A. (2018) Is Transcatheter Closure Superior to Surgical Ligation of Patent Ductus Arteriosus among Nigerian Children? *African Journal of Paediatric Surgery*, **15**, 100-103. https://doi.org/10.4103/ajps.AJPS_53_17
- [11] Nyawawa, E.T.M., Ussiri, E., Njelekela, M.A., Mpoki, U., Nyangassa, B.J., Wandwi, W.B.C. and Lugazia, E. (2013) Surgical Experience with Closure of an Isolated PDA at Muhimbili Cardiothoracic Unit in Dar es Salaam, Tanzania. *East and Central African Journal of Surgery*, **18**, 127-136.

- [12] Borges-Lujan, M., Gonzalez-Luis, G.E., Roosen, T., Huizing, M.J. and Villamor, E. (2022) Sex Differences in Patent Ductus Arteriosus Incidence and Response to Pharmacological Treatment in Preterm Infants: A Systematic Review, Meta-Analysis and Meta-Regression. *Journal of Personalized Medicine*, **12**, Article No. 1143. <https://doi.org/10.3390/jpm12071143>
- [13] Villamor, E., Borges-Luján, M. and González-Luis, G. (2023) Association of Patent Ductus Arteriosus with Fetal Factors and Endotypes of Prematurity. *Seminars in Perinatology*, **14**, Article ID: 151717. <https://doi.org/10.1016/j.semperi.2023.151717>
- [14] Dice, J.E. and Bhatia, J. (2007) Patent Ductus Arteriosus: An Overview. *The Journal of Pediatric Pharmacology and Therapeutics*, **12**, 138-146. <https://doi.org/10.5863/1551-6776-12.3.138>
- [15] Hagadorn, J.I., Brownell, E.A., Trzaski, J.M., Johnson, K.R., Lainwala, S., Campbell, B.T. and Herbst, K.W. (2016) Trends and Variation in Management and Outcomes of Very Low-Birth-Weight Infants with Patent Ductus Arteriosus. *Pediatric Research*, **80**, 785-792. <https://doi.org/10.1038/pr.2016.166>
- [16] Singh, Y., Fraise, A., Erdevé, O. and Atasay, B. (2020) Echocardiographic Diagnosis and Hemodynamic Evaluation of Patent Ductus Arteriosus in Extremely Low Gestational Age Newborn (ELGAN) Infants. *Frontiers in Pediatrics*, **8**, Article ID: 573627. <https://doi.org/10.3389/fped.2020.573627>
- [17] Tort, M., Ceviz, M., Sevil, F. and Becit, N. (2021) Surgical Treatment for Patent Ductus Arteriosus: Our Experience of 12 Years. *Cureus*, **13**, e14731. <https://doi.org/10.7759/cureus.14731>
- [18] Costa, R.N.D., Pereira, F.L., Ribeiro, M.S., Pedra, S.R., Succi, F., Marques, P., *et al.* (2012) Percutaneous vs. Surgical Treatment of Patent Ductus Arteriosus in Children and Adolescents. *Revista Brasileira de Cardiologia Invasiva*, **20**, 315-323. [https://doi.org/10.1016/S2214-1235\(15\)30071-5](https://doi.org/10.1016/S2214-1235(15)30071-5)