

# Papulosa Nigra Dermatitis Another Factor Associated with Cardio-Vascular Diseases?

Solange Flore Ngamami Mongo<sup>1,2</sup>, Bani Aloise Macaire<sup>3</sup>, Franck Yannis Kouikani<sup>1</sup>, Kivié Mou-Moué Ngolo Letomo<sup>1</sup>, Bayonne S. E. Kombo<sup>2</sup>, Bertrand Fikahem Ellenga Mbolla<sup>1,2</sup>

<sup>1</sup>Department of Cardiology B, University Hospital of Brazzaville, Brazzaville, Republic of Congo

<sup>2</sup>Departement of Medecine, Faculty of Health Sciences, Marien Ngouabi University, Brazzaville, Republic of Congo

<sup>3</sup>General Hospital of Loandjili, Pointe Noire, Republic of Congo

Email: yannisfranck@yahoo.fr

**How to cite this paper:** Mongo, S.F.N., Macaire, B.A., Kouikani, F.Y., Letomo, K.M.-M.N., Kombo, B.S.E. and Mbolla, B.F.E. (2023) Papulosa Nigra Dermatitis Another Factor Associated with Cardio-Vascular Diseases? *World Journal of Cardiovascular Diseases*, 13, 819-826.  
<https://doi.org/10.4236/wjcd.2023.1312070>

**Received:** October 24, 2023

**Accepted:** November 27, 2023

**Published:** November 30, 2023

Copyright © 2023 by author(s) and Scientific Research Publishing Inc. This work is licensed under the Creative Commons Attribution International License (CC BY 4.0).

<http://creativecommons.org/licenses/by/4.0/>



Open Access

## Abstract

**Objectives:** To determine the correlation between dermatosis papulosa nigra (DPN) and cardiovascular disease (CVD). **Patients and Method:** A retrospective study was conducted between April 2022 and March 2023 in cardiology at Loandjili General Hospital. Were included all adult patients older than 18 years of age presenting with DPN, and divided into two groups according to the presence of CVD. Hypertension (HT), endomyocardial fibrosis, dilated and restrictive cardiomyopathy, chronic pulmonary heart, ischemic heart disease, stroke, and valvular heart disease were retained as CVD. Pregnant women, Peutz Jeghers syndrome and all dermatosis with cardiovascular manifestations were excluded. Studied variables were clinico-demographic, hereditary and behavioral. **Results:** A total of 55 patients were selected. There were 40 patients with CVD, 15 patients without CVD, 43 women (78.1%) and 12 men (21.8%). Mean age was  $52 \pm 12.6$  years (extremes: 22 - 85 years). There was a significant difference between age and sex ( $P < 0.05$ ). There were 34 hypertensive patients, 10 patients with diabetes mellitus, 7 strokes, 2 endomyocardial fibrosis and 2 ischemic heart diseases. Periorbital location was representative was frequently found in the group with CVD. Hereditary and behavioral factors were involved in the development of DPN and CVD. There was a significant correlation between DPN and onset in childhood ( $P < 0.05$ ), between hypertension and use of medication ( $P < 0.05$ ), and between onset in childhood ( $P < 0.05$ ) and use of mercury containing soap ( $P < 0.05$ ). **Conclusion:** DPN predominates in young women. The occurrence of CVD depends on DPN location. Hereditary and behavioral factors associated with development of DPN are CVD factor risks.

## Keywords

Papulosa Nigra, Cardiovascular Disease, Correlation, Pointe Noire

## 1. Introduction

Cardiovascular disease (CVD) represents a heavy global burden in terms of annual deaths. As early as 2003, epidemiological data predicted a worldwide mortality rate of 31% for cardiovascular diseases, including ischemic heart disease and cerebrovascular disorders [1].

Established cardiovascular risk factors such as lack of exercise, high blood pressure or high low density lipoprotein, have been proven to increase a person's risk of developing CVD. They are characterized by consistency over time, gradual associative strength, independence and reversibility.

The skin is rightly regarded as the mirror of the internal reflection of body health. In this order of idea, certain conditions such as neurofibromatosis type 1, scleroderma, sarcoidosis, systemic lupus erythematosus, tuberous sclerosis of Bournonville, including Kawasaki disease, have cardiovascular and significant skin manifestations. Papulosa nigra dermatosis (DPN) is a benign tumor on black skin which in our context is frequently founded in people with CVD. However, DPN does not belong to the dermatosis with cardiovascular manifestations. Then we wonder if this is simply a coincidence, or is there a genuine link between DPN and CVD? The incidence of DPN is around 35% in black North Americans, and in sub-Saharan Africa it is estimated at 10% - 30% [2].

In Congo-Brazzaville, no large-scale study of DPN has been carried out.

Thus, we are carrying out this work in order to highlight the existence of a relationship between DPN and CVD in our context.

## 2. Patients and Method

This is a retrospective and analytical study carried out in the cardiology, dermatology, occupational medicine and staff consultation departments at Loandjili General Hospital in Pointe-Noire, Congo-Brazzaville, between April 2022 and March 2023, *i.e.* 12 months.

We used a survey form in which personal history, family history of DPN, and period of onset of dermatosis were mentioned. We retained the records of patients older than 18 years of age. Pain and pruritus lesions were investigated on examination. The use of skin lightening substances such as mercurial soaps, beauty milks containing cetareth 20, tocopherol and trilon B; chronic exposure to ultraviolet radiation, excessive shaving and exfoliation of the eyebrows, and the use of medication were considered as behavioral aspects. The medications listed were anti-hypertensives, anti-inflammatories, oral antidiabetics and insulin. DPN was considered hereditary when it appeared at birth, in childhood, and in adulthood without behavioral links. Patients were divided into two groups according to the presence of CVD.

## 3. Conduct of the Study and Statistical Analysis

Patients meeting the inclusion criteria, after giving their written informed consent, filled the survey sheet and answered to the Berlin questionnaire. A clinical

examination with measurement of the anthropomorphic parameters (weight, height, BMI, abdominal perimeter) and patients' blood pressure was carried out. The data were processed by Epi info fR (CDC Atlanta USA). For the comparison of the percentages, the KHI square test was used. The Student t test was used for the averages. A calculation of the odds ratio (OR) and their confidence interval (CI) was made to look for the factors associated with the DPN. For comparisons, the significance thresholds were  $p < 0.05$ .

## 4. Results

### Epidemiological data

During the study period, 55 records of patients with DPN were included. There were 15 patients (27.23%) without MCV and 40 patients (72.72%) with one or more MCV.

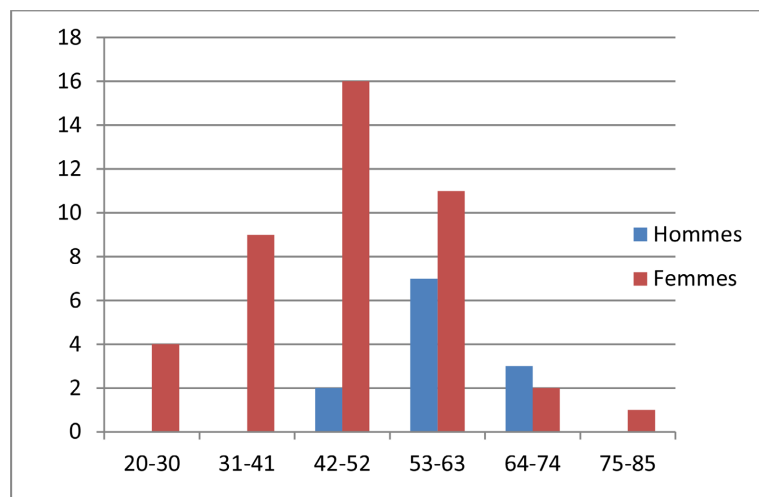
### 4.1. Epidemiological Aspects

There were 43 women (78.18 %) and 12 men (21.82%). The median age was 41, 63 years with extremes of 22 - 85 years. Four women (7.2%) were aged between 20 and 30; nine women (16.36%) were between the ages of 31 and 41. 16 women (29%) and two men (3.6%) were aged between 42 and 52. 11 women (20 %) and seven men (12.72%) were aged between 53 - 63 years. Three men (5.45%) and two women (3.6%) were between the ages of 64 and 74. One woman (1.8%) was between 75 and 85 years of age. The difference was significant between age and sex (2:6.11;  $p: 0.01$ ). **Figure 1** shows the distribution of patients by epidemiological aspects.

### 4.2. Clinical Aspects

17 patients (30.91%) had lesional skin pruritus, three patients (5.45%) had lesional skin pain, and 35 patients (63.63%) had no lesional skin manifestations.

DPN was diffuse in 30 patients (54.55%), circumscribed in 25 (45.45%).



**Figure 1.** Socio-demographic characteristics by gender.

Periorbital localization was observed in 49 patients (89%), including 25 hypertensives (45.45%), 9 with diabetes mellitus (16.36%), 5 with medical history of strokes (9.09%), 4 dilated cardiomyopathies (7.2%). Cervical location concerned 31 patients (56.36%), with 19 hypertensives (34.54%), 5 with diabetes mellitus (9.09%), 4 strokes (7.2%). 35 patients (63.63%) had an anterior thoracic location, including 18 hypertensives (32.72%), 7 with diabetes mellitus (12.72%), 5 strokes (9.09%), 2 dilated cardiomyopathies (3.63%), and respectively endomyocardial fibrosis, chronic pulmonary heart disease and ischemic heart disease. The difference was not significant between DPN location and CVD ( $P > 5\%$ ). **Table 1** summarizes the distribution of patients according to clinical aspects, and **Figures 2-4** correspond to the different DPN localizations.

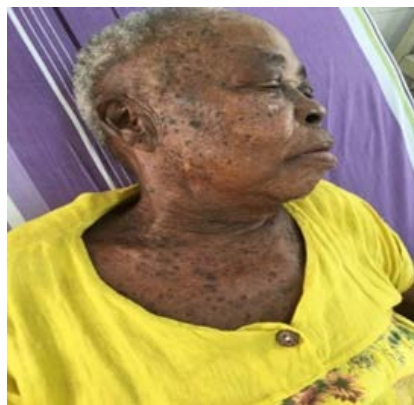### 4.3. Hereditary Aspects

31 patients (56.36%) had a family history of DPN. It appeared in adulthood in 43

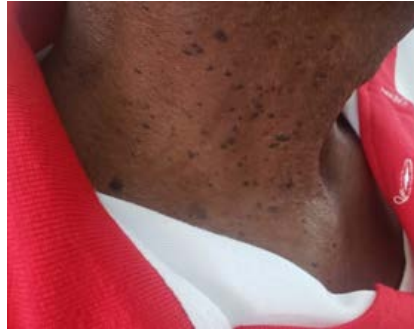**Table 1.** Distribution according to patient medical history and lifestyle habits.

Localisation DPN et MCV	HT	DM	Stroke	DCM	HCM	EMF	ICM	CPHD	VHD	Total
<i>P. orbital</i>	25	9	5	4	1	1	2	1	1	<b>49</b>
Cervical	19	5	4	2	1	0	0	0	0	<b>31</b>
Forehead	7	1	3	2	0	0	0	0	0	<b>13</b>
chin	3	1	2	1	0	0	0	0	0	<b>7</b>
Cheek	5	3	2	1	1	0	0	0	0	<b>12</b>
Thx Ant.	18	7	5	2	1	1	1	0	0	<b>35</b>
Thx Post	6	2	3	2	0	1	1	0	0	<b>15</b>
<b>Total</b>	<b>83</b>	<b>28</b>	<b>24</b>	<b>14</b>	<b>4</b>	<b>3</b>	<b>4</b>	<b>1</b>	<b>1</b>	<b>162</b>

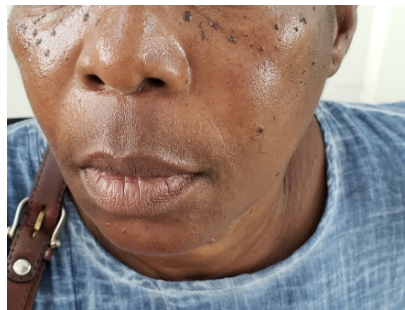CPHD: Chronic pulmonary heart disease; DCM: dilated cardiomyopathy; DM: Diabetes mellitus; EMF: Endomyocardial fibrosis; HCM: Hypertrophic cardiomyopathy; HT: Hypertension; ICM: Ischemic cardiomyopathy; P. orbital: Péri orbital. Thx Ant: Thorax anterior; Thx Post: Thorax posterior; VHD: Valvular heart disease.



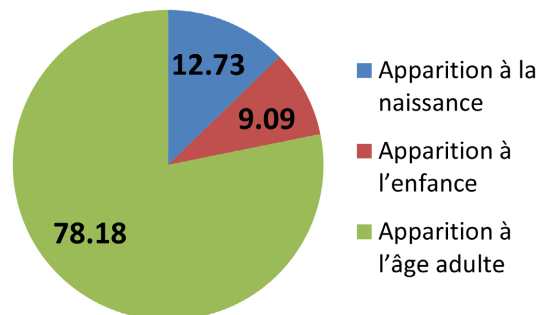
**Figure 2.** Diffuse DPN in an 85-year-old patient. Known polyarterial and atheromatous disease.



**Figure 3.** Cervical DPN in a 44-year-old hypertensive.



**Figure 4.** Periorbital DPN in a hypertensive type II diabetic mellitus patient with a major cerebrovascular event.



**Figure 5.** Distribution of patients by hereditary aspect.

patients (78.18%), at birth in 7 patients (12.73%) and in childhood in 5 patients (9.09%). There was a significant correlation between the family history of DPN and childhood onset ( $\chi^2$ : 4.18;  $p$ : 0.04). **Figure 5** shows the distribution of patients according to hereditary aspects.

#### 4.4. Behavioral Aspects

The use of mercurial soaps was found in 39 patients (70.9%), including 20 hypertensives (36.36%), 6 with diabetes mellitus (10.9%), 5 with medical history of stroke (9.09%) and 3 dilated cardiomyopathies (5.45%). The use of beauty milk and/or scrubs was observed in 34 patients (61.81%), including 21 hypertensives (38.18%), 5 with diabetes mellitus (9.09%) and 5 strokes (9.09%). 48 patients (87.27%) were taking medication, including 27 hypertensives (49.09%), 8 diabetics patient (14.54%), 4 DCM (7.27%), one HCM, one EMF, one ischemic

heart disease, one chronic pulmonary heart disease, and one valvular heart disease. Respectively 33 patients (60%) had sun exposure and eyebrow waxing. There were 18 hypertensives (32.72%), and the other CVDs are listed in **Table 2**, which summarizes the distribution of patients according to behavioral aspects. Statistically, there was a significant difference between hypertension and the use of mercurial soaps ( $\chi^2$ : 4.67; p: 0.03).

## 5. Discussion

DPN or CASTELLANI disease is a benign epithelial tumor measuring around 1 - 5 mm in diameter. It was discovered in Jamaica and Central America by Aldo CASTELLANI in 1925. Its exact etiology is unknown, but it appears to be a variant of seborrheic keratosis, which affects certain ethnic groups with black skin [3]. Genetically, it is linked to a nevoid developmental defect of the pilosebaceous follicle, and to activating punctual mutations of fibroblast growth factors (including PIK3CA and FGFR3) [3]. It predominantly affects young, dark-skinned women, as we previously observed, and Caucasians [2] [4]. The periorbital location is the most representative, as also highlighted in the literature [5]. In our context, this location is also associated with cardiovascular and cerebrovascular disorders. Our study shows that the proliferative and diffuse forms of DPN are associated with CVD. Histopathological and dermatoscopic studies of DPN illustrate that it is a tumor characterized as an acanthotic and keratotic seborrheic variant [3] [6]. Tumors, whether benign or malignant, are controlled by growth codes. An Indian study on methionine shows that this essential amino acid in humans regulates the control program for cell growth, particularly that of cancer cells. It acts as a growth signal for cells, and triggers a whole metabolic program for cell proliferation in the event of excessive production [7]. The same Indian study also shows that vitamin B12 acts as a coenzyme in methionine synthesis. It is in the form of the enzyme methyl B12 that a methyl group is added to homocysteine to form methionine. The methyl donor is methyl tetrahydrofolate. Homocysteine is another amino acid intermediate in methionine metabolism. The level of homocysteine in plasma depends on a number of factors, including folate and vitamin

**Table 2.** Distribution of patients according to behavioral aspects.

Behaviour	CVD	HT	DM	STROKE	DCM	HCM	EMF	CPI	ICM	VHD	Total
Use of mercury soap		20	6	5	3	1	1	1	1	1	39
Medication intake		27	8	4	4	1	1	1	1	1	48
Use of body lotion		21	5	5	1	1	1	0	0	0	34
Eyebrow waxing and excessive scrubbing		18	6	3	2	1	1	2	0	0	33
Solar exposition		18	5	3	2	1	0	2	1	1	33
<b>Total</b>		<b>104</b>	<b>30</b>	<b>20</b>	<b>12</b>	<b>5</b>	<b>4</b>	<b>6</b>	<b>3</b>	<b>3</b>	<b>187</b>

Photo-exposed areas were at greater risk of developing DPN, with an OR = 28.8.

B6 and B12 status. Genetic polymorphisms in methylene tetrahydrofolate reductase play a crucial role in the development of CVD, and any genetic or acquired deficiency in one of these enzymes or cofactors leads to reduced cellular catabolism of homocysteine, resulting in hyperhomocysteinemia. For over 30 years, homocysteine has been considered a cause of atherosclerosis, and it has been demonstrated that there is an indisputable relationship between hyperhomocysteinemia and myocardial infarction, stroke, hypertension, inflammatory diseases, dementia or venous thromboembolic disease [8]. The hypothesis of the relational existence between DPN and the onset of CVD can be evoked by this pathophysiological mechanism. Due to a technical failure, we were unable to obtain biological analyses of methionine, vitamin B12 or homocysteine in order to establish this link. Frankly, the mechanism that gives rise to chronic pulmonary heart, HCM, valvulopathies and EMF during DPN is not yet clearly elucidated, and can be considered a genuine coincidence, but the one that triggers pruritus and/or localized pain can be explained embryologically by the common ectodermal origin between the skin and the nervous system. Thus, pruritus due to cutaneous dryness can be provoked or, above all, maintained by the use of mercurial soaps, or by drugs such as inhibitors of the renin-angiotensin-aldosterone system, or even anti-inflammatory drugs. As mentioned earlier, DPN is hereditary. This hereditary predisposition is the most common factor in the development of both DPN and CVD in women of a certain age, whose mothers are DPN and CVD carriers [5] [9]. The progressive onset of DPN may explain its late onset in adulthood or during aging. It may also account for other forms of DPN without CVD. Skin depigmentation (through the use of mercurial soaps, beauty milks and aggressive scrubs) underlines the role of these cosmetic products in the development of CVD [10]. Indeed, the use of mercurial soaps, as well as excessive and aggressive exfoliation with unsuitable products, can accentuate reactive hyper-seborrhea, while stimulating the appearance of hyper-pigmented spots. According to Perret JL *et al.* [11], these substances can cross the cutaneous-mucosal barrier and enter the system, causing nephro angio-sclerosis, hypertension or diabetes mellitus. Exposure to the sun predisposes to the appearance of DPN, and to melanin production. The lesions are located preferentially in photo-exposed areas, and thus suggest the etiopathogenic role of the sun's ultraviolet rays in the onset of DPN, as highlighted in the literature [2]. Sun exposure does not normally cause CVD. It does, however, generate arterial vasodilation through the secretion of vitamin D and nitric oxide (NO), a powerful vasodilator [13]. Eyebrow hair removal is not hypertensogenic, but it can promote the development of painful ingrown hairs after shaving. Paradoxically, we note that the association of DPN with sun exposure and eyebrow waxing increases CVD. This implies that DPN can be considered as one of the factors associated with CVD in our context.

## 6. Conclusion

DPN mainly affects young black women. We found a significant correlation be-

tween DPN and the occurrence of CVD. Presence and location of DPN can influence the occurrence of CVD. Hereditary and behavioral aspects play a role both in occurrence of DPN and CVD.

### Conflicts of Interest

The authors declare no conflicts of interest regarding the publication of this paper.

### References

- [1] Blacher, J. (2009) *Epidémiologie cardio-vasculaire et pression centrale*. Masson, Paris, 15-24.
- [2] Odom, R.B., Davidsohn, I.J., William, D., Henry, J.B. and Berger, T.G. (2006) *Clinical Diagnosis by Laboratory Methods*. In: James, W.D., Elston, D.M., Treat, J.R. and Rosenbach, M.A., Eds., *Andrews' Diseases of the Skin: Clinical Dermatology*, Elsevier, Amsterdam.
- [3] Niang, S.O., Kane, A., Diallo, M., Choutah, F., *et al.* (2007) Dermatoses papulosa nigra à Dakar, Sénégal. *International Journal of Dermatology*, **46**, 45-47. <https://doi.org/10.1111/j.1365-4632.2007.03465.x>
- [4] Xiao, A., Muse, M.E. and Etefagh, L. (2023) *Dermatose papuleuse nire*. Statpearls Publishing, St. Petersburg.
- [5] Karadag, A.S., Ozkanli, S., Mansuroglu, C., Ozlu, E., *et al.* (2015) Efficacité du traitement au laser à colorant pulsé chez une femme de race blanche atteinte de dermatose papulosa nigra. *Indian Journal of Dermatology*, **60**, 321. <https://doi.org/10.4103/0019-5154.156447>
- [6] Kaloga, M., Yoboue, Y.P., Ecras, E.S., Gbery, I.P., *et al.* (2016) Aspects épidémiologiques, cliniques et thérapeutiques du dermatose papulosa nigra DPN. *Annales de Dermatologie et de Vénérologie*, **143**, S55-S56. [https://doi.org/10.1016/S0151-9638\(16\)30234-4](https://doi.org/10.1016/S0151-9638(16)30234-4)
- [7] Bhatt, R.M., Patrao, N., Monteiro, R., *et al.* (2017) A Clinical, Dermoscopic, and Histopathological Study of Dermatoses Papulosa Nigra (DPN)—An Indian Perspective. *International Journal of Dermatology*, **59**, 957-960. <https://doi.org/10.1111/ijd.13633>
- [8] Walvekar, A.S., *et al.* (2018) Methionine Coordinates a Hierarchically Organized Anabolic Program Enabling Proliferation. *Molecular Biology on the Cell*, **29**, 3063-3200.
- [9] de Jaeger, C., Fraoucene, N., Voronska, E. and Cherin, P. (2010) Role of Homocysteine in Pathology. *Medicine & Longevity*, **2**, 73-86. <https://doi.org/10.1016/j.mlong.2010.03.002>
- [10] Grimes, P.E., Arora, S., Moins, R.H. and Kenney, J.A. (1983) Dermatose à papulosa nigra. *Peau*, **32**, 385-386.
- [11] Obengui, G.A. and Ibara, J.R. (2005) Motifs de consultation liés à l'usage des dépigmentants chez 104 utilisatrices à Brazzaville. *Bulletin de la Société de pathologie exotique*, **96**, 401-402.
- [12] Perret, J.L., Sane, M., Gning, S., Ba, K. and Rohou, G. (2001) Freinage hypothalamo-hypophysio-surrénalien lié à l'usage de cosmétiques dépigmentants au Sénégal. *Bulletin de la Société de pathologie exotique*, **94**, 249-252.
- [13] Phan, O. and Burnier, M. (2007) Vitamine D et hypertension artérielle: Quel lien? *Revue Médicale Suisse*, **3**, 2022-2026.