

# Dyspnea in a 26-Year-Old Woman with Fatal Left Atrial Myxoma

Ibrahima Sory Sylla<sup>1,2\*</sup>, Mamadou Aliou Baldé<sup>1,2</sup>, Mamadou Bassirou Bah<sup>1,2</sup>, Sana Samoura<sup>2,3</sup>, Souleymane Diakit<sup>2</sup>, Alpha Koné<sup>2,3</sup>, Ibrahima Sory Barry<sup>1,2</sup>, Mariame Béavogui<sup>1,2</sup>, Djibril Sylla<sup>2,4</sup>, Elhadj Yaya Baldé<sup>1,2</sup>, Mamadi Condé<sup>1</sup>, Mamadou Dadhi Baldé<sup>1,2</sup>

<sup>1</sup>Department of Cardiology, Ignace Deen National Hospital, Conakry, Guinea

<sup>2</sup>Faculty of Health Sciences and Techniques, Gamal Abdel Nasser University of Conakry, Conakry, Guinea

<sup>3</sup>Department of Cardiology, Sino-Guinean Hospital, Conakry, Guinea

<sup>4</sup>Department of Internal Medicine CHU, Conakry, Guinea

Email: \*ibsosyl@yahoo.fr

**How to cite this paper:** Sylla, I.S., Baldé, M.A., Bah, M.B., Samoura, S., Diakit, S., Koné, A., Barry, I.S., Béavogui, M., Sylla, D., Baldé, E.Y., Condé, M. and Baldé, M.D. (2023) Dyspnea in a 26-Year-Old Woman with Fatal Left Atrial Myxoma. *World Journal of Cardiovascular Diseases*, 13, 309-312.

<https://doi.org/10.4236/wjcd.2023.136028>

**Received:** May 3, 2023

**Accepted:** June 27, 2023

**Published:** June 30, 2023

Copyright © 2023 by author(s) and Scientific Research Publishing Inc. This work is licensed under the Creative Commons Attribution International License (CC BY 4.0).

<http://creativecommons.org/licenses/by/4.0/>



Open Access

## Abstract

Cardiac myxoma is one of the primary intracardiac tumours. We report the case of a left atrial myxoma in a 26-year-old female patient admitted for investigation of dyspnoea. Echocardiography led to the diagnosis of a giant hypermobile myxoma prolapsing into the left ventricle. The patient died before being evacuated for surgical treatment.

## Keywords

Myxoma, Left Atrium, Echocardiography

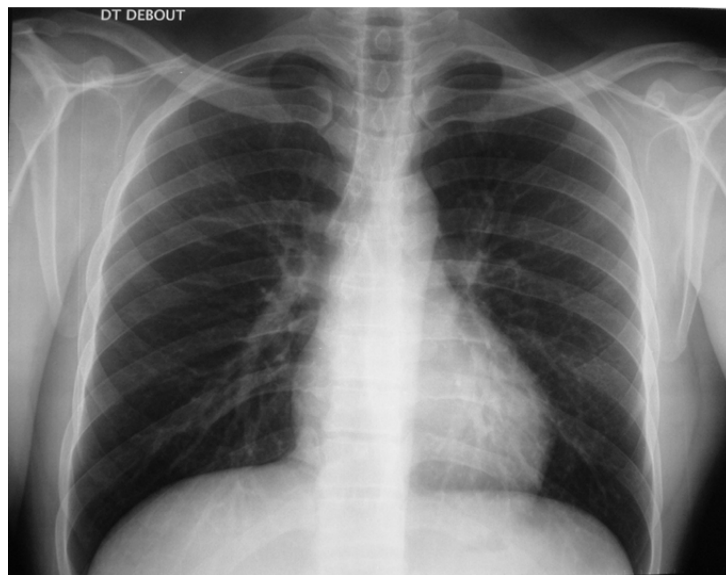
## 1. Introduction

Cardiac myxoma is one of the primary intracardiac tumours. It accounts for 0.5 per million population per year [1]. It is a histologically benign tumour with a high risk of embolism due to its friable and gelatinous nature [2]. Its clinical presentation is usually insidious and may reveal itself as mitral stenosis. Its diagnosis is most often echocardiographic. The treatment of myxoma consists of surgical resection of the mass. The risk of late recurrence after surgery is estimated at 2% [3] [4]. In Africa, no data are available; all studies are based on case reports. We report the case of a 26-year-old woman admitted for investigation of progressively progressive dyspnoea revealing a left atrial myxoma with a fatal outcome.

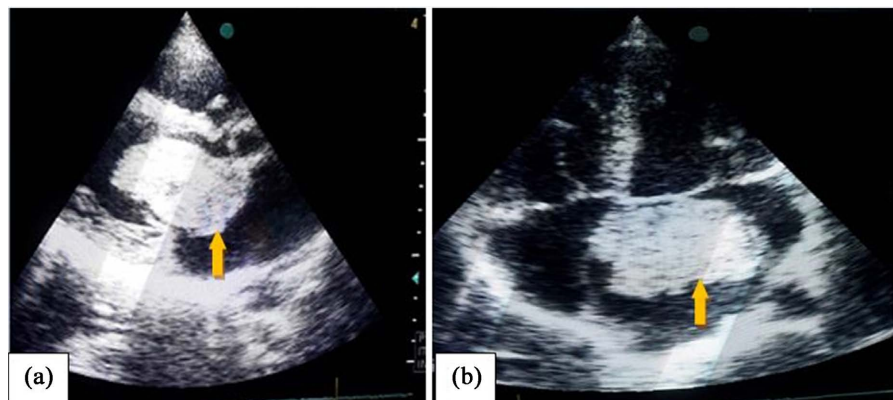
## 2. Clinical Case

The patient was 26 years old, with no previous cardiological history but a long

asthma history. She was referred to us for an investigation of exertional dyspnea. Her symptoms were frustrating, with no palpitations, no chest pain and no fever. On admission, blood pressure was 110/65 mmHg, heart rate 100 bpm, respiratory rate 24 cycles per minute, temperature 36.7°C. Cardiac auscultation found regular heart sounds with a burst of B1 with no heart murmur nor peripheral signs of right and left heart failure. The electrocardiogram (ECG) showed a regular sinus rhythm at 95 bpm, left atrial hypertrophy, and no specific repolarization disorder. The frontal chest X-ray showed a normal-sized cardiac silhouette and good parenchymal transparency (Figure 1). Transthoracic echocardiography (TTE) revealed a substantial cardiac tumour encompassing almost the entire left atrium, prolapsing into the left ventricle through the mitral valve in diastole (Figure 2). Left atrial dilatation was 25 cm<sup>2</sup>, and good biventricular systolic



**Figure 1.** Front chest X-ray showing a normal-sized heart with good transparency of the pulmonary parenchyma.



**Figure 2.** (a) Transthoracic cardiac ultrasound, parasternal long axis section showing left atrial myxoma prolapsing into the LV in diastole (arrow); (b) Apical 4-chamber section in systole showing left atrial myxoma inserting into the inter-atrial septum (arrow) and occupying the entirety of the OG.

function was noted. An unstricted mitral pseudo-stenosis was measured. Pulmonary pressures were estimated to be 36 mmHg on tricuspid insufficiency flow.

The biological work-up showed normocytic normochromic anaemia at 11.5 g/dL without the biological inflammatory syndrome. The rest of the work-up was without abnormalities.

The diagnosis of a left atrial myxoma was made. The management consisted of the evacuation of the patient abroad for the removal of the tumour. We lost the patient during the evacuation process. The exact cause of death was not known, as the family had refused an autopsy.

### 3. Discussion

Left atrial myxoma is a cardiac tumour with a low prevalence. The first autopsy description dates from 1845, and the first clinical diagnosis was reported in 1952 [5]. Primary cardiac tumours represent less than 0.2% of all neoplasia, three-quarters of these tumours are benign, and half are myxomas. The female sex is most often affected [6], as in our patient's case. Its insidious symptomatology makes diagnosis difficult. Thus, the myxoma is sometimes seen incidentally during a cardiac ultrasound. Although histologically benign, its location and complications can be life-threatening. Intracardiac myxoma is a pathology characterized by a very high clinical polymorphism that can delay diagnosis, although embolic events represent 10% of cases [7]. This was the case with our patient, who had been seen and treated in several peripheral centres for asthma. However, the diagnosis was quickly made on transthoracic echocardiography showing a large mass occupying almost the entire OG and prolapsing into the LV in diastole. Management consisted of surgical intervention. Our patient died before benefiting from this surgery due to the weakness of the technical platform on the one hand and the cumbersome medical evacuation process on the other. This clinical case reminds us that the surgical management of a myxoma is urgent due to the risk of embolism and the non-negligible risk of sudden death due to the myxoma becoming embedded in the mitral annulus.

### 4. Conclusion

Myxoma of the atrium is a rare but not exceptional entity. Diagnosis is most often made by echocardiography. Its management must be urgent to avoid the risk of sudden death.

### Family Consent

The consent of the family has been obtained for the publication of this clinical case.

### Authors' Contributions

All authors contributed to the development of this case, and we have their full

approval for the publication of this article.

### Conflicts of Interest

The authors declare no conflicts of interest regarding the publication of this paper.

### References

- [1] Gregory, S.A., O'Byrne III, W.T. and Fan, P. (2004) Infected Cardiac Myxoma. *Echocardiography*, **21**, 65-67. <https://doi.org/10.1111/j.0742-2822.2004.02177.x>
- [2] Swartz, M., Lutz, C.J., Chandan, V.S., Landas, S. and Fink, G.W. (2006) Atrial Myxomas: Pathologic Types, Tumor Location, and Presenting Symptoms. *Journal of Cardiac Surgery*, **21**, 435-440. <https://doi.org/10.1111/j.1540-8191.2006.00265.x>
- [3] Kosuga, T., Fukunaga, S., Kawara, T., et al. (2002) Surgery for Primary Cardiac Tumors: Clinical Experience and Surgical Results in 60 Patients. *The Journal of Cardiovascular Surgery*, **43**, 581-587.
- [4] Lefranc, V., Valantian, M. and Ray, P. (2017) Myxome de l'oreillette gauche révélé par une ischémie aiguë de membre. *Annales françaises de médecine d'urgence*, **7**, 135-136. <https://doi.org/10.1007/s13341-017-0724-6>
- [5] Li, J., Lin, F., Hsu, R. and Chu, S. (1996) Video-Assisted Cardioscopic Resection of Recurrent Left Ventricular Myxoma. *The Journal of Thoracic and Cardiovascular Surgery*, **112**, 1673-1674. [https://doi.org/10.1016/S0022-5223\(96\)70030-2](https://doi.org/10.1016/S0022-5223(96)70030-2)
- [6] Reynen, K. (1996) Cardiac Myxomas. *The New England Journal of Medicine*, **333**, 1610-1617. <https://doi.org/10.1056/NEJM199512143332407>
- [7] Pinede, L., Duhaut, P. and Loire, R. (2001) Clinical Presentation of Left Atrial Cardiac Myxoma. A Series of 112 Consecutive Cases. *Medicine (Baltimore)*, **80**, 159-172. <https://doi.org/10.1097/00005792-200105000-00002>