

# Ischemic Stroke Revealing Infective Endocarditis in a Young Subject: About a Clinical Case

Coumba Thiam<sup>1</sup>, Boubacar Sonfo<sup>1\*</sup>, Massama Konaté<sup>2</sup>, Mahan Ameri Abba Diall<sup>3</sup>, Asmaou Keita<sup>3</sup>, Mariam Sako<sup>4</sup>, Youssouf Camara<sup>1</sup>, Hamidou Oumar Bâ<sup>5</sup>, Ibrahima Sangaré<sup>5</sup>, Mamadou Touré<sup>5</sup>, Samba Sidibé<sup>4</sup>, Massama Camara<sup>1</sup>, Simo Moyo<sup>3</sup>, Souleymane Coulibaly<sup>4</sup>, Ichaka Menta<sup>5</sup>

<sup>1</sup>Cardiology Department of Kati University Hospital, Kati, Mali

<sup>2</sup>Internal Medicine Department of Mali Hospital, Bamako, Mali

<sup>3</sup>Cardiology Department of the Mother-Child University Hospital, Bamako, Mali

<sup>4</sup>Cardiology Department CHU Point G, Bamako, Mali

<sup>5</sup>Cardiology Department of the CHU Gabriel Touré, Bamako, Mali

Email: \*sonfo20032001@yahoo.fr

**How to cite this paper:** Thiam, C., Sonfo, B., Konaté, M., Diall, M.A.A., Keita, A., Sako, M., Camara, Y., Bâ, H.O., Sangaré, I., Touré, M., Sidibé, S., Camara, M., Moyo, S., Coulibaly, S. and Menta, I. (2022) Ischemic Stroke Revealing Infective Endocarditis in a Young Subject: About a Clinical Case. *World Journal of Cardiovascular Diseases*, 12, 209-215.

<https://doi.org/10.4236/wjcd.2022.124021>

**Received:** March 8, 2022

**Accepted:** April 24, 2022

**Published:** April 27, 2022

Copyright © 2022 by author(s) and Scientific Research Publishing Inc.

This work is licensed under the Creative Commons Attribution-NonCommercial International License (CC BY-NC 4.0).

<http://creativecommons.org/licenses/by-nc/4.0/>



Open Access

## Abstract

**Introduction:** Neurological complications are possible during infective endocarditis. They are often life-threatening and can be a source of sequelae.

**Case Presentation:** We report the case of an 11-year-old patient admitted to the cardiology department of the CHU-ME “LUXEMBOURG” in Bamako for functional impotence of the left hemibody, accompanied by fever and NYHA stage II dyspnea. The clinical examination on admission shows the poor general condition, normal consciousness, and sensory-motor deficit of the pyramidal type of the left hemibody. The cardiovascular examination notes a systolic murmur at the mitral focus, hepato-jugular reflux, hepatomegaly, and slight edema in the lower limbs. Brain CT showed localized hypodensity in favor of an ischemic stroke. The electrocardiogram shows a sinus rhythm. Transthoracic Doppler echocardiography revealed mitral insufficiency with vegetation of 17 × 14 mm on the anterior mitral valve, with left ventricular ejection fraction estimated at 75%. Dual antibiotic therapy associated with conventional treatment for heart failure was initiated. The clinical evolution was marked by the persistence of the deficit of the left upper limb, the cardiac Doppler echography of control after 6 weeks of treatment found the same vegetation. A discussion with the heart team with a view to a surgical cure has been initiated for the rest of the treatment. **Conclusion:** A motor deficit associated with fever related to an ischemic vascular accident should lead to a search for infective endocarditis on cardiac Doppler ultrasound.

---

## Keywords

Ischemic Stroke-Infectious Endocarditis-Young Subject

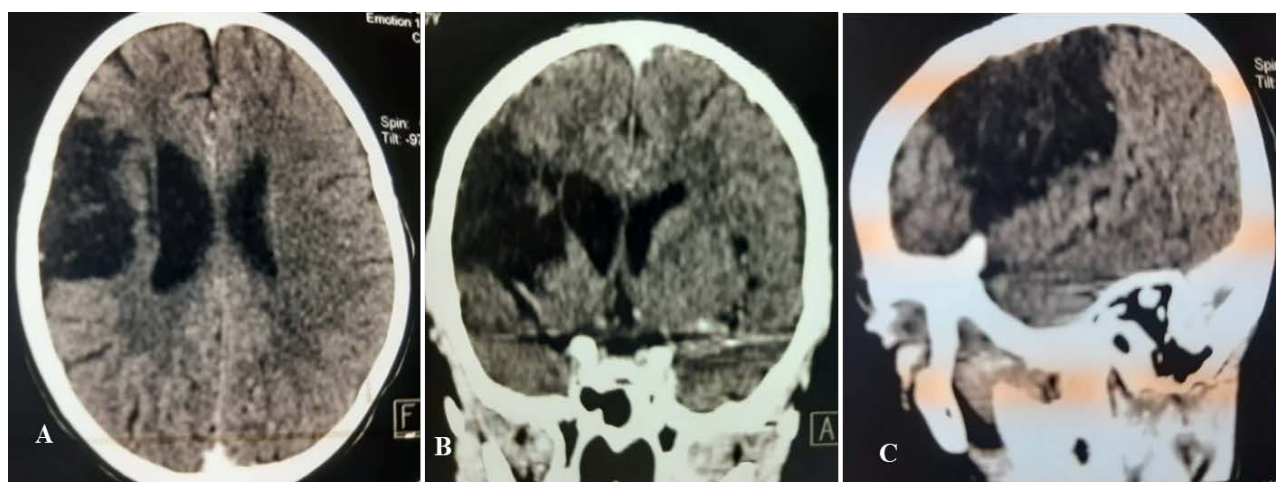
---

### 1. Introduction

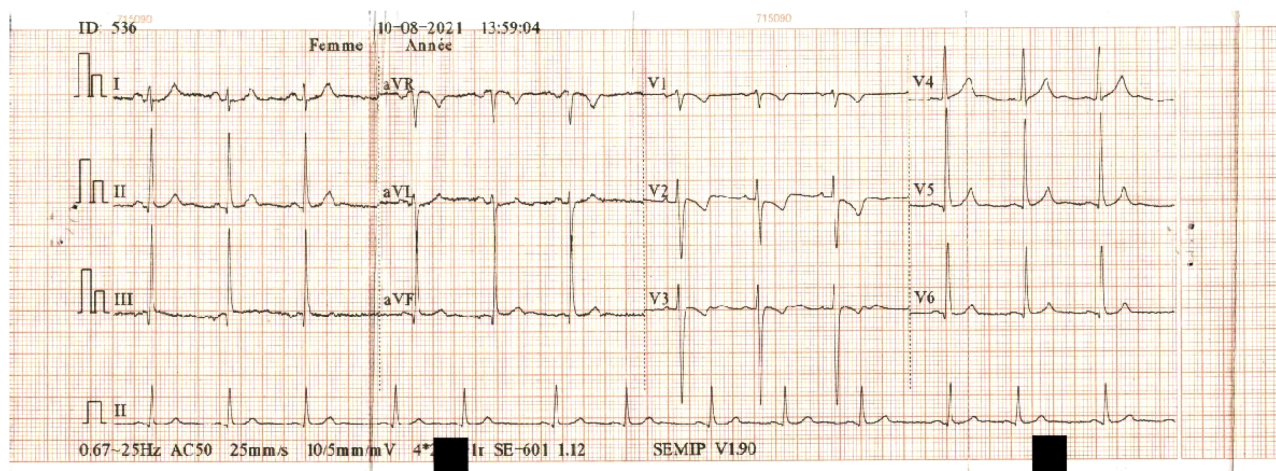
Ischemic cerebrovascular accidents (AVCI) are the third leading cause of death and the leading cause of major disability worldwide. Symptomatic ischemic stroke is reported in 10% to 35% of infective endocarditis [1]. The admission of patients with infective endocarditis (IE) is generally linked to the occurrence of complications, the most frequent of which are congestive heart failure due to valvular lesions, septic shock, particularly when staphylococcus aureus is involved, and neurological complications, responsible for disturbances of consciousness. Neurological complications during infective endocarditis are frequent with an incidence of 50% in the absence of early treatment [2]. They are often life-threatening and can be a source of sequelae. In addition, they are likely to radically modify patient management [3]. They occur before any antibiotic therapy in more than 70% of patients [4] [5]. They usually occur in the context of left IE, isolated right IE not being complicated by a cerebral embolic event [6]. Ischemic stroke (AVCI) by embolism of vegetation constitutes one of the main complications and can thus hide underlying infectious endocarditis [2]. We report a case of infective endocarditis revealed by an ischemic stroke in a young subject.

### 2. Observation

This is an 11-year-old patient with a history of repeated angina in abused childhood, admitted to the cardiology department of the CHU-ME "LUXEMBOURG" in Bamako for functional impotence of the left hemibody of Sudden onset, accompanied by a fever of 38.5°C and NYHA stage II dyspnea. The clinical examination on admission found a patient in poor general condition, with normal colored conjunctivae, normal consciousness, and sensory-motor deficit of the pyramidal type of the left hemibody. On the cardiovascular plan, the sounds of the heart are regularly fast, we noted the presence of a systolic murmur of intensity 4/6 at the mitral focus, perceived peripheral pulses, and fine crackles on pulmonary auscultation, presence of reflux hepato-jugular, hepatomegaly, and slight edema of the lower limbs. Cerebral CT showed a range of right cortical-subcortical parietal and caudo-capsular hypodensity testifying to an ischemic stroke with the formation of a porencephalic cavity in the superficial and deep territory of the right Sylvian and anterior junctional territory (Figure 1). On the biological level, the blood count noted hypochromic normocytic anemia at 10 g/dl, a CRP at 5 mg/l, ASLO was negative, and blood culture and HIV serology were negative. The ECG shows a regular sinus rhythm at 75 BPM, repolarization disorder (Figure 2), the transthoracic ultrasound performed on admission showed a remodeled mitral

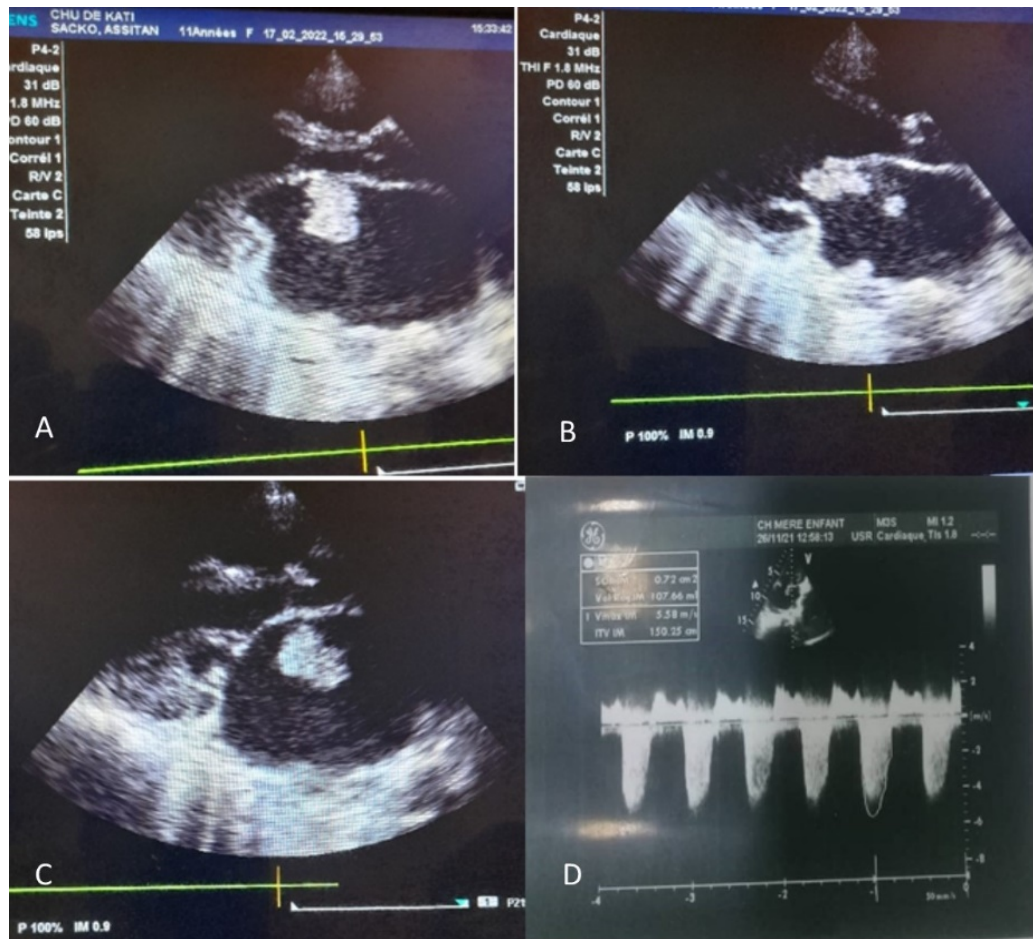


**Figure 1.** Brain CT in axial section (A); coronal (B) and sagittal reconstruction (C) without contrast product objectifying a ischemic stroke with formation of a porencephalic cavity of the superficial and deep territory of the right sylvian and of the homolateral anterior junctional territory.

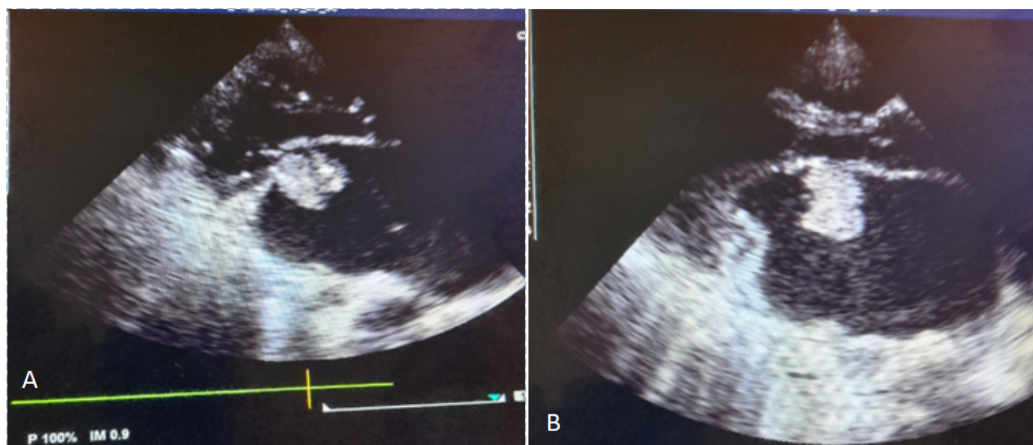


**Figure 2.** Sinus rhythm, repolarization disorder.

valve, mitral insufficiency (SOR = 0.72 cm<sup>2</sup>; VR IM = 107.66 ml; Vmax = 5.55 m/s), vegetation of 17 × 14 mm on the large mitral valve, LVEF = 75% (**Figure 3**). Infectious mitral valve endocarditis complicated by ischemic stroke was retained. The patient was put on probabilistic dual antibiotic therapy based on amoxicillin for a period of 6 weeks and gentamicin for 14 days, treatment of heart failure including a diuretic, an enzyme-converting enzyme inhibitor and a Beta blocker. Clinical evolution is marked by apyrexia 24 hours after the start of treatment, a regression of the signs of heart failure after 72 days of treatment; the motor deficit has improved with the persistence of the mono paresis of the left arm. The follow-up cardiac Doppler ultrasound after 6 weeks of treatment found the same vegetation (**Figure 4**). Surgical intervention was proposed, after the discussion within the heart team, in the absence of financial means, a medical follow-up is in progress while waiting for the conditions to be met for the surgical treatment.



**Figure 3.** Transthoracic ultrasound, long axis parasternal. Mass attached to the large mitral valve ((A), (B), (C)). Mitral regurgitation grade III (D).



**Figure 4.** Transthoracic ultrasound, long axis parasternal. Mass attached to the large mitral valve ((A), (B)), after antibiotic therapy.

### 3. Discussion

Complications of infective endocarditis affecting the central nervous system are embolic ischemic vascular accidents, cerebral hemorrhages, meningitis and brain

abscesses. These complications mainly result from the embolism of vegetation in the cerebral circulation: depending on the nature of the embolism (septic or not), the lesion will be suppurative, inflammatory or purely ischemic [7]. Symptomatic ischemic stroke is reported in 10% to 35% of infective endocarditis [1] [8]. Ischemic stroke is the most common neurological complication. Ischemic strokes are the consequence of the migration of valvular vegetations which are septic thrombi. The predictive factors are above all the size of the vegetation and the existence of endocarditis due to staphylococcus. Studies based on clinical or imaging (brain scan) detection of cerebral embolic events have shown that the embolic risk increased significantly when the size of the vegetation was greater than 10 mm. The embolic risk also depends on the chronology. It decreases after initiation of curative antibiotic therapy and becomes weak after 2 weeks of treatment, regardless of the size of the adenoids [9]. Faced with a clinical picture of motor deficit associated with fever and a heart murmur in a young subject, the discovery of an ischemic stroke on the cerebral scanner should lead to the performance of a transthoracic Doppler ultrasound in search of infective endocarditis. Fanomezantsoa Noella Ravelosaona in a study reports the case of a 44-year-old patient hospitalized for left hemiplegia, afebrile, with a history of repeated angina in childhood and poorly treated, presence of a systolic murmur of intensity 3/6 at the level of the mitral focus, the appearance of a fever of 39°C to 40°C on Day 5 of hospitalization, blood culture and HIV serology carried out were negative, the cerebral scanner on Day 7 of hospitalization showed a large hypodensity affecting the white and gray matter of the territory of the right total Sylvian artery, which led them to request a Doppler echocardiography, which objectified the presence of a small valve calcified remodeled mitral with vegetations of 12 × 16 mm and 6.37 × 9.07 mm. The hypothesis was infective endocarditis of the small mitral valve complicated by a wide ischemic stroke of the right total Sylvian artery. Bi-antibiotic therapy was indicated, and the evolution was marked by apyrexia 24 hours after treatment. Follow-up Doppler echocardiography after 4 weeks of treatment showed total disappearance of the adenoids, but clinically persistent motor deficit [10]. Our case is an 11-year-old child, admitted for sudden functional impotence of the left hemibody, accompanied by fever and NYHA stage II dyspnea, fine crackles on pulmonary auscultation, presence of hepato-jugular reflux, hepatomegaly, slight edema of the lower limbs, a grade 4/6 systolic murmur at the mitral hearth on cardiac auscultation, led us to perform a Cerebral CT which objectified a DALY on the territory of the right Sylvian artery, the same location was observed in the Fanomezantsoa Noella Ravelosaona study, but the case in the Fanomezantsoa study was an adult, clinically he had no signs of heart failure [10]. The result of the cerebral CT led us to perform a transthoracic ultrasound, which found a remodeled mitral valve, grade III mitral insufficiency, and vegetation of 17 × 14 mm on the anterior mitral valve. Some studies have shown that the incidence of cerebral emboli was more frequent in cases of left mitral than aortic endocarditis [11] [12], the same

location was found in our patient. Therapeutically, in the absence of germs in the blood culture, the patient was put on a probabilistic dual antibiotic therapy based on amoxicillin for a period of 6 weeks and gentamicin for 14 days, the fever improved but the ultrasound trans thoracic control finds the same vegetation. Unlike the study by Fanomezantsoa Noella Ravelosaona, control Doppler echocardiography after 4 weeks of treatment showed total disappearance of the vegetations [10]. Given the size of the vegetation and the risk of recurrence of stroke, surgery was proposed, after discussion within the heart team, in the absence of financial means, medical follow-up is in progress while waiting for the conditions to improve for surgical management.

#### 4. Conclusion

A sudden motor deficit in a febrile context linked to an ischemic cerebrovascular accident should lead to the search for infective endocarditis on echocardiography. Support is provided by the heart team.

#### Conflicts of Interest

The authors declare no conflicts of interest regarding the publication of this paper.

#### References

- [1] Murdoch, D.R., Corey, G.R., Hoen, B., Miro, J.M., Jr Fowler, V.G., Bayer, A.S., *et al.* (2009) Clinical Presentation, Etiology, and Outcome of Infective Endocarditis in the 21st Century. *Archives of Internal Medicine*, **169**, 463-473. <https://doi.org/10.1001/archinternmed.2008.603>
- [2] Sonnevile, R., Klein, I., Bouadma, L., Mourvillier, B., Regnier, B. and Wolff, M. (2009) Complications neurologiques des endocardites infectieuses. *Réanimation*, **18**, 547-555. <https://doi.org/10.1016/j.reaurg.2009.06.010>
- [3] Mourvillier, B., Trouillet, J.L., Timsit, J.F., Baudot, J., Chastre, J., Regnier, B., *et al.* (2004) Infective Endocarditis in the Intensive Care Unit: Clinical Spectrum and Prognostic Factors in 228 Consecutive Patients. *Intensive Care Medicine*, **30**, 2046-2052. <https://doi.org/10.1007/s00134-004-2436-9>
- [4] Heiro, M., Nikoskelainen, J., Engblom, E., Kotilainen, E., Marttila, R. and Kotilainen, P. (2000) Neurologic Manifestations of Infective Endocarditis: A 17-Year Experience in a Teaching Hospital in Finland. *Archives of Internal Medicine*, **160**, 2781-2787. <https://doi.org/10.1001/archinte.160.18.2781>
- [5] Salgado, A.V., Furlan, A.J., Keys, T.F., Nichols, T.R. and Beck, G.J. (1989) Neurologic Complications of Endocarditis: A 12-Year Experience. *Neurology*, **39**, 173-178. <https://doi.org/10.1212/WNL.39.2.173>
- [6] Chambers, H.F., Miller, R.T. and Newman, M.D. (1988) Right-Sided Staphylococcus Aureus Endocarditis in Intravenous Drug Abusers: Two-Week Combination Therapy. *Annals of Internal Medicine*, **109**, 619-624. <https://doi.org/10.7326/0003-4819-109-8-619>
- [7] Francioli, P. (2004) Complications of Infective Endocarditis. In: Lippincott-Raven, Ed., *Infections of the Central Nervous System*, Philadelphia, 523-553.
- [8] Ruttman, E., Willeit, J., Ulmer, H., Chevtchik, O., Hofer, D., Poewe, W., *et al.*

- (2006) Neurological Outcome of Septic Cardioembolic Stroke after Infective Endocarditis. *Stroke*, **37**, 2094-2099. <https://doi.org/10.1161/01.STR.0000229894.28591.3f>
- [9] Habib, G., Lancellotti, P., Antunes, M.J. *et al.* (2015) 2015 ESC Guidelines for the Management of Infective Endocarditis: The Task Force for the Management of Infective Endocarditis of the European Society of Cardiology (ESC) Endorsed by: European Association for Cardio-Thoracic Surgery (EACTS), the European Association of Nuclear Medicine (EANM). *European Heart Journal*, **36**, 3075-3128. <https://doi.org/10.1093/eurheartj/ehv319>
- [10] Ravelosaona, F.N., Razafimahefa, J., Randrianasolo, R.O., Rakotoarimanana, S. and Tehindrazanarivelo, D.A. (2016) Accident vasculaire cérébral ischémique large chez un sujet jeune révélateur d'une endocardite infectieuse: à propos d'un cas. *Pan African Medical Journal*, **25**, Article ID: 10347. <https://doi.org/10.11604/pamj.2016.25.31.10347>
- [11] Anderson, D.J., Goldstein, L.B., Wilkinson, W.E., Corey, G.R., Cabell, C.H., Sanders, L.L., *et al.* (2003) Stroke Location, Characterization, Severity, and Outcome in Mitral vs Aortic Valve Endocarditis. *Neurology*, **61**, 1341-1346. <https://doi.org/10.1212/01.WNL.0000094359.47929.E4>
- [12] Vilacosta, I., Graupner, C., San-Roman, J.A., Sarria, C., Ronderos, R., Fernandez, C., *et al.* (2002) Risk of Embolization after Institution of Antibiotic Therapy for Infective Endocarditis. *Journal of the American College of Cardiology*, **39**, 1489-1495. [https://doi.org/10.1016/S0735-1097\(02\)01790-4](https://doi.org/10.1016/S0735-1097(02)01790-4)