

# Double Discordance with Pulmonary Stenosis: About a Clinical Case

Asmaou Keita Maiga<sup>1</sup>, Boubacar Sonfo<sup>2\*</sup>, Daffé Sanoussi<sup>1</sup>, Fofana Daouda<sup>1</sup>, Diallo Souleymane<sup>1</sup>, Terra Abdoul Wahab<sup>1</sup>, Thiam Coumba<sup>2</sup>, Ba Hamidou<sup>3</sup>, Touré Mamadou<sup>1</sup>, Camara Youssouf<sup>2</sup>, Mamadou Bocary Diarra<sup>1</sup>

<sup>1</sup>Cardiology Department CHU Mère - Enfant, Bamako, Mali

<sup>2</sup>Cardiology Department of CHU Kati, Bamako, Mali

<sup>3</sup>Cardiology Department CHU Gabriel Touré, Bamako, Mali

Email: \*sonfo20032001@yahoo.fr

**How to cite this paper:** Maiga, A.K., Sonfo, B., Sanoussi, D., Daouda, F., Souleymane, D., Wahab, T.A., Coumba, T., Hamidou, B., Mamadou, T., Youssouf, C. and Diarra, M.B. (2020) Double Discordance with Pulmonary Stenosis: About a Clinical Case. *World Journal of Cardiovascular Diseases*, 10, 825-830.

<https://doi.org/10.4236/wjcd.2020.1012078>

**Received:** November 24, 2020

**Accepted:** December 27, 2020

**Published:** December 30, 2020

Copyright © 2020 by author(s) and Scientific Research Publishing Inc. This work is licensed under the Creative Commons Attribution International License (CC BY 4.0).

<http://creativecommons.org/licenses/by/4.0/>



Open Access

## Abstract

**Introduction:** Double discordance or corrected transposition of the great vessels is a rare congenital heart disease. It is an atrioventricular and ventriculo-arterial mismatch. It is a complex and unusual form of congenital heart disease. Often asymptomatic, in its isolated form, bradycardia, murmur and cyanosis can be a mode of revelation. **Case presentation:** We report the case of an 11-year-old child, asymptomatic at birth, after he started to have dyspnea on exertion, recurrent bronchitis, motivating a cardiological consultation. On cardiac physical examination, the heart sounds regular, not rapid at 81 BPM with a grade 3-4/6 systolic murmur at the 4th left EIC (Intercostal space). EKG (electrocardiogram) shows PR interval at 0.20 seconds. Cardiac ultrasound reveals atrioventricular discordance, vascular malposition, anterior aorta, the two vessels placed side by side, minimal pulmonary insufficiency, a small leak at the levels of the mitral and tricuspid valves, dystrophic pulmonary valves with an average gradient of 91 mmHg, max at 158 mmHg. Regular follow-up has been recommended through the performance of a clinical examination and cardiac ultrasound. **Conclusion:** The double discordance can be asymptomatic, and survival can be long in the isolated forms, but the evolution is not always benign, especially in the associated forms. It depends on the function of the systemic right ventricle and associated abnormalities.

## Keywords

Double Discordance, CHU ME, Luxembourg, Bamako

## 1. Introduction

Double discordance or corrected transposition of the great vessels is a rare congenital heart disease. It is an atrioventricular and ventriculo-arterial mismatch. It is a complex and unusual form of congenital heart disease. Often asymptomatic, in its isolated form, bradycardia, heart murmur and cyanosis can be a mode of revelation. It represents less than 1% of congenital heart disease. The isolated form of this heart disease represents only 10% to 20% of all corrected transposition of the great vessels (GCTV). This heart disease seems to be more common in Asia than in the rest of the world [1] [2] [3]. Given the complexity and rarity of the pathology, which is at the same time asymptomatic, we were motivated to report this case.

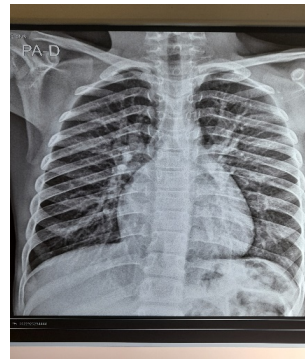
## 2. Ethical Considerations

The parents declared that they had given their consent for the use of the child's data that they were informed of the confidentiality of the information and would only be released for scientific purposes.

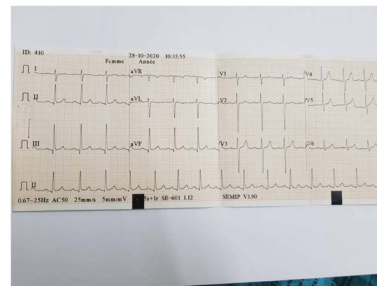
## 3. Observation

This is an 11 year old male patient, born on 12/28/2009, fifth child of a family of 7 children, from a term pregnancy, vaginal delivery, no concept of consanguinity with parents. The family history is unremarkable. The onset of symptoms dates back to birth, with the onset of dyspnea on breastfeeding effort, recurrent bronchitis, all of which prompted a consultation at the Gabriel Touré Hospital and then mother-child university hospital center (CHU). On physical examination the weight was 23 kgs with a height of 126 cm, a blood pressure of 120/90mmHg, a heart rate at 81 BPM (beats per minute) with SPO<sub>2</sub> (oxygen saturation): 99%. The general condition was good, the conjunctiva normal colored, the heart sounds are regular, not rapid with a systolic murmur 3-4/6 at the 4<sup>th</sup> intercostal space(EIC), the peripheral pulses perceived, the lungs are free, the calves flexible, absence of peripheral signs of heart failure. At the end of the clinical examination, paraclinical examinations were carried out: the chest x-ray found cardiomegaly, large bilateral hilum (**Figure 1**), the electrocardiogram (EKG) shows a regular sinus rhythm, ventricular rate at 93 BPM, normal QRS axis, PR interval: 200 ms, absence of arrhythmia, normal repolarization (**Figure 2**), the cardiac ultrasound performed returned with situs solitus, levocardia, absence of pulmonary or systemic venous return anomaly, atrioventricular discordance, the atria are of normal size, good bi-ventricular function, vascular malposition, anterior aorta, the two large vessels placed side by side, aortic valves of normal appearance, aortic ring = 17.5 mm, pulmonary ring = 16 - 17.5 mm, APR = 14 - 16 mm, APD = 16 mm, APG = 15 mm, dystrophic pulmonary valves with average gradient at 91 mmHg, max at 158 mmHg, small pulmonary insufficiency (PI) with speed at 1.9 m/s, ductus arteriosus closed, small leak on left and right AV valves, coronary not visualized, aortic arch normal, absence of pericardial effu-

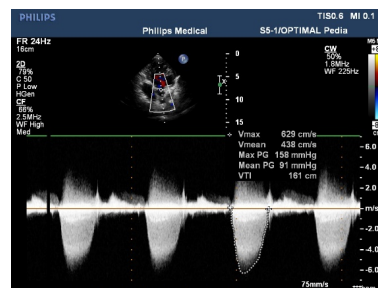
sion, in total a double discordance with pulmonary stenosis (**Figure 3** and **Figure 4**). The biological assessment shows hemoglobin = 14.4 g/dl, white blood cells =  $5.64 \times 10^3/\text{mm}^3$ , red blood cells =  $5.41 \times 10^6/\text{mm}^3$ , Rhesus group = A positive, HIV = negative, hematocrit = 42.7%, Platelets:  $309 \times 10^3/\text{mm}^3$ , TP-INR = 1.11, Glycemia = 5.31 mmol/l, Creatinine =  $43,000 \mu\text{mole/l}$ , CRP-US = 0.2 mg/l, TCA: 0.85, Uricemia = 3.40 mmol/l, Creatine clearance: 144.72 ml/min, Ag Hbs = negative, Ag Hbc = negative. The patient was put on antibiotic therapy during the episodes of bronchitis. Cardiovascular surgeons were approached to assess the possibility of surgical repair, after several case discussion sessions between cardiac surgeons and cardiologist, regular follow-up has been recommended by performing a clinical examination and cardiac ultrasound. The double discordance can be asymptomatic as in our case, but the course is not always benign, especially in the associated forms. It depends on the function of the systemic right ventricle and associated abnormalities.



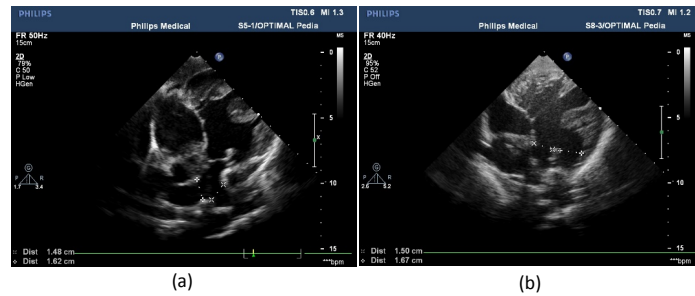
**Figure 1.** Cardiomegaly, large bilateral hilum.



**Figure 2.** Normal electrocardiogram.



**Figure 3.** Dystrophic pulmonary valves with average gradient at 91 mmHg, max at 158 mmHg.



**Figure 4.** (a) Pulmonary artery comes out of the left ventricle. (b) under costal (the two large vessels placed side by side).

#### 4. Discussion

Double discordance is a complex congenital disease which accounts for 1% of congenital heart disease [4]. Anatomically, double discordance is characterized by an aberrant connection between a right atrium (left) with a non trabeculated ventricle of left morphology (right), from this anterior right ventricle comes a vessel which is said to be in two, the pulmonary artery. From the left ventricle, posterior of right morphology (trabeculated), a large non-dividing vessel (the aorta) emerges [5]. The situs is most often solitus, as in our case, but the situs can be in versus. Dextrocardia can be found in 20% of cases and represents a reason for discovery. In 90% of cases of double discordance, there are associated abnormalities such as interventricular communication (60%), pulmonary valve or subvalvular stenosis (50%), complete atrioventricular blocks (2%) and abnormalities of the tricuspid valve in a systemic position (tricuspid insufficiency, Ebstein's disease) [6]. In our case, the double discordance was associated with pulmonary valvular dystrophy with a mean gradient of 91 mmHg, max at 158 mmHg. The discovery is most often made during the neonatal period by the installation of a respiratory distress syndrome associated with eating difficulties, or in childhood, in front of a heart murmur secondary to an associated malformation. In the forms associated with wide interventricular communication, the clinical picture will be dominated by signs of heart failure from an early age, if pulmonary stenosis is present, cyanosis will gradually set in. The absence of associated abnormalities allows prolonged survival into adulthood [7]. Several cases of double discordance have been described in the literature. M. Oukhouyamohamedamine in his thesis on the corrected transposition of large vessels carried out in 2012. Their study involves a series of 5 cases, the symptoms began in one of the patients 10 days after birth with the onset of respiratory distress syndrome associated with eating difficulties, the cardiac ultrasound performed to show: an atrioventricular discordance with ventricular inversion, the ventricle of right morphology is located on the left and the ventricle of left morphology is located on the right, a large sub pulmonary CIV (inter ventricular communication) extending to the admission septum, non-restrictive, bidirectional shunt, with a shunt in exclusively right-left systole and in left-right diastole, overriding of the tricuspid valve with tricuspid chords inserting on the septal

crest, minimal tricuspid leakage, hyper tight coarctation with systemic duct, the cerclage of the pulmonary artery with coarctation treatment and section suture of the canal was performed [8]. This is not the case in our patient, who is asymptomatic. The second case is an infant so the clinical examination found an added left latero basal murmur, the cardiac ultrasound returned with a situs solitus, a left ventricle on the right and the right ventricle on the left, a LTVG and a large shunt inter ventricular communication (CIV) from the right ventricle to the left ventricle with pulmonary hypertension, significant dilation of the right ventricle with significant mitral insufficiency Vmax 4 m/s, presence of a 6 mm ductus arteriosus, the patient was put on medical treatment [8]. The third case is a 10-year-old child whose heart exam revealed a subtle murmur of tricuspid insufficiency. The chest x-ray showed cardiomegaly, the cardiac ultrasound objectified a situs solitus, a mitro-aortic discordance, a right ventricle that is on the left dilated, a left ventricle on the right, pulmonary artery on the right and posterior, aorta on the left and anterior, no right or left obstacle, the interatrial and interventricular septa intact, no canal, it is a LTVG without associated lesions, no heart failure, the child is asymptomatic [8]. This last patient presents a situation similar to ours, the only difference being that our case presents a pulmonary stenosis, in spite of this lesion associated with the double discordance, he remained asymptomatic. We can say that our case was fortunate to have a satisfactory balance of pulmonary and systemic circulation.

## 5. Conclusion

The double discordance is a complex congenital heart disease which can be asymptomatic as in our case, survival can be long in the isolated forms, but the evolution is not always benign, especially in the associated forms. It depends on the function of the systemic right ventricle and associated abnormalities.

## Conflicts of Interest

The authors declare no conflicts of interest regarding the publication of this paper.

## References

- [1] Wallis, G.A., Debich Spicer, D. and Anderson, R.H. (2011) Congenitally Corrected Transposition. *Orphanet Journal of Rare Diseases*, **6**, 22. <https://doi.org/10.1186/1750-1172-6-22>
- [2] Ferencz, C., Rubin, J.D., Mc Carter, R.J., Brenner, J.I., Neill, C.A., Perry, L.W., Hepner, S.I. and Downing, J.W. (1985) Congenital Heart Disease: Prevalence at Live Birth. *American Journal of Epidemiology*, **121**, 31-36. <https://doi.org/10.1093/oxfordjournals.aje.a113979>
- [3] Samanek, M. and Voriskova, M. (1999) Congenital Heart Disease among 815,569 Children Born between 1980 and their 15 Year Survival: A Prospective Bohemia Survival Study. *Pediatric Cardiology*, **20**, 411-417. <https://doi.org/10.1007/s002469900502>

- [4] Warnes, C.A., Williams, R.G., Bashore, T.M., Child, J.S., Connolly, H.M., Dearani, J.A., *et al.* (2008) ACC/AHA Guidelines for Management of Adults with Congenital Heart Disease. *Journal of the American College of Cardiology*, **52**, e1-e121. <https://doi.org/10.1016/j.jacc.2008.10.002>
- [5] Fredouille, C. and Develay Morice, J. (2003) The Practical Fetal Heart Montpellier: Sauramps Medical Editions. <https://stcccv-tunisie.com>
- [6] Hornung, T.S. and Calder, L. (2010) Congenitally Corrected Transposition of the Great Arteries. *Heart*, **96**, 1154-1161. <https://doi.org/10.1136/hrt.2008.150532>
- [7] Beauchesne, L.M., Warnes, C.A., Connolly, H.M., Ammash, N.M., Tajik, A.J., Danielson, G.K., *et al.* (2002) Outcome of the Unoperated Adult Who Presents with Congenitally Corrected Transposition of Great Arteries. *Journal of the American College of Cardiology*, **40**, 285-290. [https://doi.org/10.1016/S0735-1097\(02\)01952-6](https://doi.org/10.1016/S0735-1097(02)01952-6)
- [8] Oukhouya Mohamed Amine, M. (2012) Corrected Transposition of the Great Vessels. Thesis of Medicine and Pharmacy of Fez. <https://scolarite.fmp-usmba.ac.ma>