

# Simultaneous Occurrence of Myofascial Pain Referred to Tooth and Endodontic Lesions in Patient with Toothache: A Case Report

Takashi Uchida<sup>1</sup>, Chiaki Komine<sup>2</sup>, Takashi Iida<sup>1</sup>, Masakazu Okubo<sup>1</sup>, Osamu Komiyama<sup>1</sup>

<sup>1</sup>Orofacial and Head Pain Clinic, Nihon University Hospital at Matsudo, Chiba, Japan

<sup>2</sup>Department of Oral Health Science, Division of Laboratory Medicine for Dentistry, Nihon University School of Dentistry at Matsudo, Chiba, Japan

Email: uchida.takashi@nihon-u.ac.jp

**How to cite this paper:** Uchida, T., Komine, C., Iida, T., Okubo, M. and Komiyama, O. (2020) Simultaneous Occurrence of Myofascial Pain Referred to Tooth and Endodontic Lesions in Patient with Toothache: A Case Report. *Open Journal of Stomatology*, 10, 230-240

<https://doi.org/10.4236/ojst.2020.108022>

**Received:** July 20, 2020

**Accepted:** August 10, 2020

**Published:** August 13, 2020

Copyright © 2020 by author(s) and Scientific Research Publishing Inc. This work is licensed under the Creative Commons Attribution International License (CC BY 4.0).

<http://creativecommons.org/licenses/by/4.0/>



Open Access

## Abstract

Toothache is almost always caused by odontogenic toothache, but diagnosis is more difficult in the case of nonodontogenic toothache. We report a case of simultaneous occurrence of odontogenic and nonodontogenic toothache. This manuscript presents a case report for a 35-year-old woman who visited our Orofacial and Head Pain Clinic with the chief complaint of continuous dull pain in left maxillary molar teeth region. It was concluded to be a case of simultaneous odontogenic toothache and nonodontogenic toothache. It was successfully treated by an endodontist and an orofacial pain specialist. The endodontist performed root canal treatment against odontogenic toothache caused by apical periodontitis using a dental operating microscope. The presence of a trigger point (TP) resulting in tooth pain was inferred. A trigger point injection (TPI) was administered by orofacial pain specialist, and toothache relief was confirmed. Myofascial pain was diagnosed definitively. After confirming that the toothache had resolved at multiple TPIs, a crown prosthesis was placed. Following the application of crown prosthesis, we were concerned but did not find recurrence of toothache from myofascial pain due to increased occlusal force. This case suggests that there is no single cause of chronic pain and that multiple causes must be considered for diagnosis, suggesting the need for treatment by multiple specialists.

## Keywords

Myofascial Pain, Odontogenic Toothache, Nonodontogenic Toothache, Referred Pain

## 1. Introduction

Toothache, the most common type of orofacial pain, is often attributable to dental pulp or periodontal tissue. Since patients complaining of oral pain present with various symptoms, clinicians encounter cases in which making an accurate diagnosis is difficult [1]. A diagnosis can be especially difficult in cases in which patients present with symptoms of nonodontogenic toothache similar to odontogenic toothache [2], and even more difficult in cases involving referred pain. Myofascial pain referred to tooth (MPRT) in the masseter muscle, one cause of nonodontogenic toothache, is observed in 11% of patients with myofascial pain [3]. Since endodontic procedures or tooth removal may be performed before an accurate diagnosis is made, clinicians should always consider the possibility that pain may not originate in the teeth [4]. On the other hand, nonodontogenic toothache can occur together with odontogenic toothache [4] [5]. Such cases are even more difficult to diagnose due to the multiple causes of the pain. Beyond this, therapeutic effects are not readily achieved and it takes considerable time to eliminate toothache. We report a case of successful treatment of a residual pulp in a calcified root canal by an endodontist with root canal treatment using a microscope and combined treatment with trigger point injection (TPI) by an orofacial pain specialist.

## 2. Case Report

### 2.1. History

A 35-year-old woman visited our hospital with the chief complaint of continuous dull pain in the region of the left maxillary molar teeth. Seven years before year X, the patient had received an initial root canal treatment for the left maxillary second molar tooth (tooth 27). However, the toothache had persisted, and the root canal treatment was subsequently repeated. The pain did not dissipate, but it had lessened and had been left untreated. At one month before her initial visiting our hospital in year X, the patient began experiencing a continuous spontaneous dull pain similar to the previous pain in the left maxillary molar region, although the exact pain site was not identified. The patient visited an otolaryngologist, where no evidence of maxillary sinusitis was found. She then consulted our Orofacial and Head Pain Clinic in year X.

### 2.2. Clinical Examination Diagnosis and Treatment

The findings did not include facial inflammation such as swelling or visually identifiable facial asymmetry. The patient complained of tenderness in the anterior and middle parts of the bilateral temporalis on muscular palpation and also complained of referred pain in the left temporalis on palpation, although we could not determine whether the pain was familiar. Intraoral examination suggested good oral hygiene. The periodontal tissue appeared to be in good condition. Tooth 27, exhibiting CR restoration on the occlusal surface, responded to percussion. While the patient complained of tenderness in the gingiva of the

buccal apical region, we could not determine whether the pain was familiar. We found an amalgam filling on tooth 26, and no prosthetic restoration on tooth 25. Neither tooth 25 nor tooth 26 responded to percussion but showed vital reaction in response to an electric pulp test. Panoramic radiography showed a dome-shaped radiopaque shadow at the bottom of the left maxillary sinus (**Figure 1**).

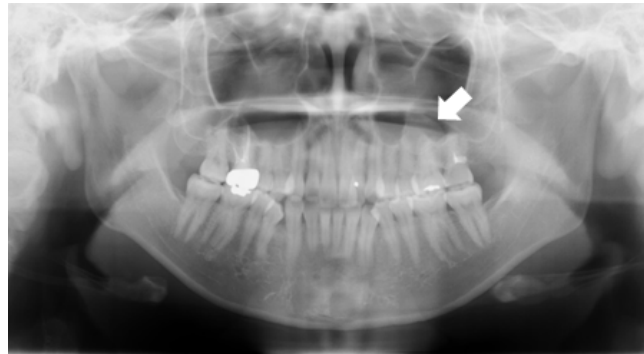
Oral radiography indicated radiopaque shadows at the palatal root and around the distal buccal root canal orifice of tooth 27, but no transmission image in the apical region (**Figure 2**).

Computed tomography (CT) showed a dome-shaped low density area at the bottom of the left maxillary sinus, but no pathologic evidence at the apical region of tooth 27 (**Figure 3**).

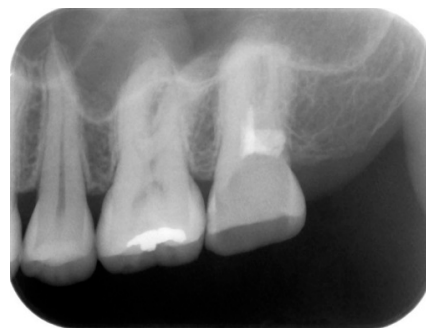### 2.3. Diagnosis and Treatment

First diagnosis: mucocele of maxillary sinus at the bottom of the left maxillary sinus

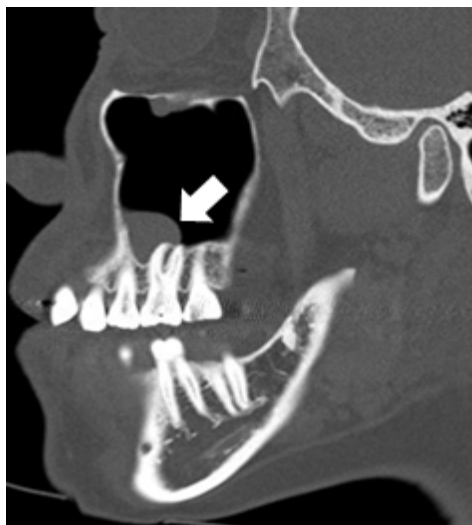
Radiographic interpretation raised the suspicion of a mucocele of maxillary sinus. We requested a detailed examination from our hospital's department of oral surgery. The results indicated the presence of thickened mucosa at the bottom of the maxillary sinus, but mild and no inflammatory findings in the maxillary sinus. We concluded that mucus cysts were a less likely cause of the pain.



**Figure 1.** Panoramic radiographs at the initial examination. White arrow shows a dome-shaped radiopaque shadow at the bottom of the left maxillary sinus.



**Figure 2.** Oral radiograph at the initial examination. Oral radiography indicated radiopaque shadows at the palatal root and around the distal buccal root canal orifice of tooth 27, but no transmission image in the apical region.



**Figure 3.** Computed tomography (CT) photograph of the left side maxillary sinus. White arrow shows a dome-shaped low density area at the bottom of the left maxillary sinus, but no pathologic evidence at the apical region of tooth 27. The presence of thickened mucosa at the bottom of the maxillary sinus, but mild and no inflammatory findings in the maxillary sinus.

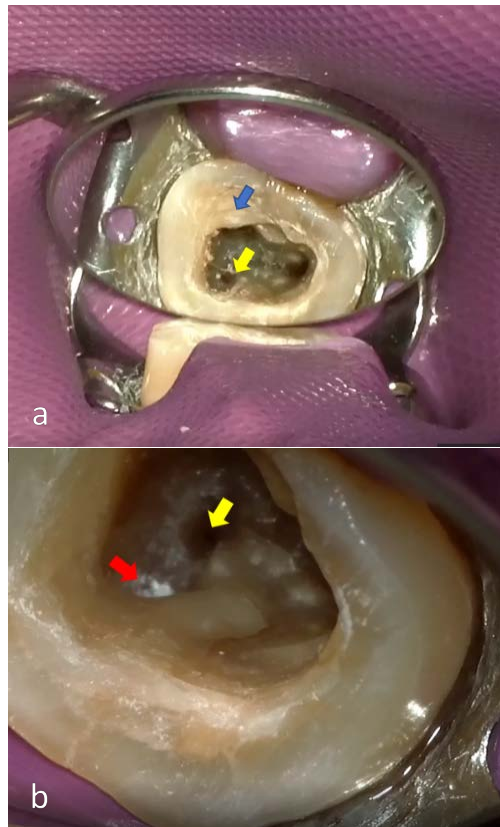
#### Second diagnosis: chronic apical periodontitis of tooth 27

The medical history of the illness indicated repeated root canal treatment over an extended period. Radiography indicated poor root canal filling treatment. Based on this, we considered the possibility of odontogenic toothache caused by apical periodontitis and referred the patient to an endodontist (Certified by the Japan Endodontic Association) for treatment of a root canal infection affecting tooth 27.

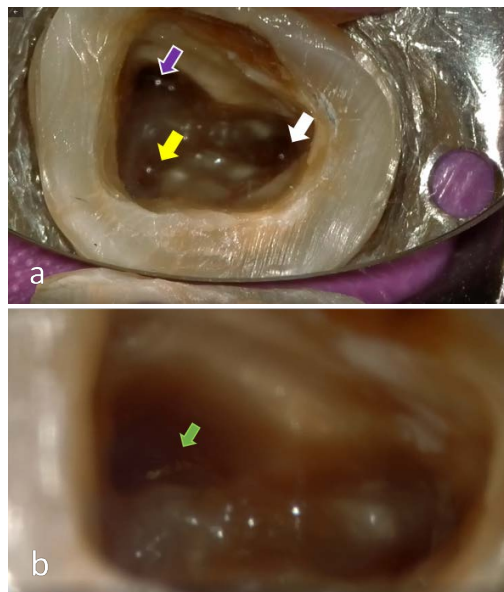
Root canal treatment for tooth 27 started two weeks after the patient's initial visit to our hospital in year X. First, a thorough examination of the root canal was performed using a dental operating microscope. Radiography indicated that the radiopaque findings at the palatal root and around the distal buccal root canal orifice were due to root canal filling material. This filling material and the infected dental substance were removed as much as possible (**Figure 4(a)**). Ceiling of pulp chamber remained in the mesial buccal root canal, and the root canal orifice opening was unclear (blue arrow). The distal buccal root canal (yellow arrow) was left untreated. However, intracanal medicament (red arrow) applied by a previous dentist was observed at the site where the artificial root canal was suspected. Based on these results and CT findings, we identified three root canals for the relevant tooth. On that basis, we initiated conventional root canal treatment (**Figure 4(b)**).

No root fractures were observed. We removed the ceiling of pulp chamber and made all root canals clearly visible (**Figure 5(a)**). We confirmed the presence of an untreated isthmus extending in the palatal direction at the mesial buccal root canal (**Figure 5(b)**).

Since the patient complained of pain during the process of root canal preparation



**Figure 4.** Condition of root canal interior at start of root canal treatment. (a) Blue arrow shows ceiling of pulp chamber. Yellow arrow shows the original distal buccal root canal. (a) Red arrow shows the distal buccal artificial root canal. Yellow arrow shows the original distal buccal root canal.



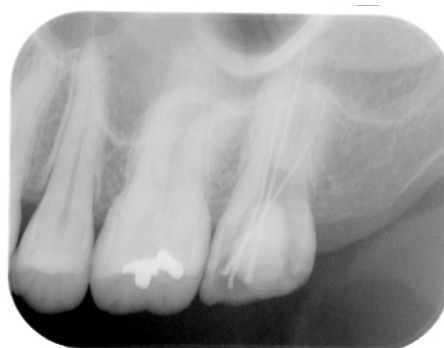**Figure 5.** Root canal clearly showing root canal orifice. (a) Three root canals clearly visible after removal of ceiling of pulp chamber. Purple, Yellow and White arrows show the mesial buccal root canal, distal buccal root canal and palatal root canal, respectively. (b) Green arrow shows an untreated isthmus confirmed within mesial buccal root canal.

at the distal buccal root canal and we observed a vital reaction of the residual pulp, the procedure was undertaken under infiltration anesthesia. **Figure 6** shows an oral radiograph of the state in which a master cone was tentatively placed after expansion of the root canal (**Figure 6**).

Because the surroundings of the apical region were mechanically stimulated, we applied intracanal medication of guaiacol into the root canal, targeting analgesic or anti-inflammatory effects [6]. Since the root canal treatment relieved the patient's toothache, we repeated a tenderness test of the left temporalis. As the results of the test, the patient complained of tenderness and we confirmed, for the first time, the presence of a trigger point (TP) resulting in pain at tooth 27. The root canal treatment was performed using a dental operating microscope, the percussion pain caused by the apical periodontitis and residual pulp, which is odontogenic toothache, disappeared. This permitted the identification of nonodontogenic toothache arising from MPRT, leading to a diagnosis of simultaneous occurrence of odontogenic and nonodontogenic toothache. For this reason, subsequent treatments were performed by an orofacial pain specialist (Certified by the Japanese Society of Orofacial Pain).

Final diagnosis: endodontic disease of tooth 27 and MPRT attributable to left temporalis

Three months after the patient's initial visit in year X, the patient was given a detailed explanation of MPRT and TP [7]. Subsequently, a TPI of 1% mepivacaine hydrochloride was applied at the TP of the left temporalis. Toothache relief was confirmed, and a definitive diagnosis of MPRT attributable to the left temporalis was established. The patient was instructed to perform physical therapeutic care involving self-massage of the temporalis. Since she reported continual dull pain toothache relief immediately after TPI, TPI was continued. Repeated treatment involving three TPIs performed every two weeks all but eliminated the pain from tooth 27. She became aware of sleep bruxism that she had not previously noticed. A fourth TPI was performed to treat the persistent tenderness in the left temporalis. Five months after the patient's initial visit in year X, this resulted in complete resolution of the toothache and the tenderness in the left temporalis. We resumed root canal treatment thereafter, performing a root

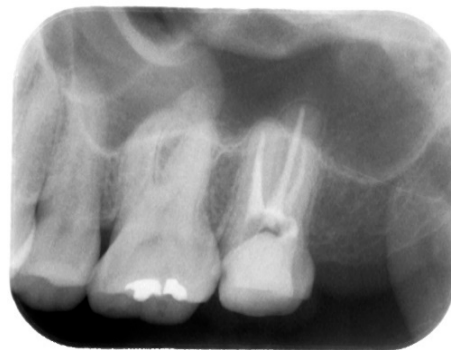

**Figure 6.** Oral radiograph of tentative placement of master cone on tooth 27. Establish three root canals with master cone.

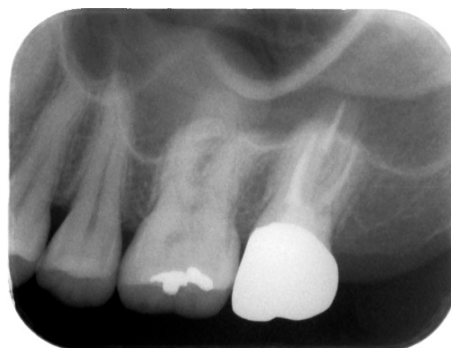canal filling at 10 months (**Figure 7**) and applying a crown prosthesis at 14 months (**Figure 8**) after the patient's initial visit in year X. Following the application of crown prosthesis, no toothache recurred. However, on waking, the patient experienced an aching pain in the bilateral temporalis. She was instructed to perform physical therapeutic care once again. The treatment was completed at this point.

### 3. Discussion

Since the radiography at the patient's initial visit showed no transmission image in the apical region but pointed to a poorly performed root canal filling, we chose an endodontic procedure for tooth 27. The endodontist for this patient considered two possible causes for the toothache. One possible cause for the persistent pain was infected tooth substance within the root canal due to repeated root canal treatment over an extended period of time. The shape of the maxillary molar varies, and women are very likely to experience fusion of tooth canals, particularly with tooth 27 [8]. In this patient, a CT showed three root canals, but when viewed under a dental operating microscope the mesial buccal root canal was found to be compressed, with infected dental substance in the isthmus. The residual infected tooth substance within the root canal may have caused the toothache. Another possible cause was residual pulp in the distal buccal root



**Figure 7.** Oral radiograph of root canal filling on tooth 27. Appropriate root canal filling material was recognized up to the apex.



**Figure 8.** Oral radiograph of application of final prosthesis on tooth 27 at 14 months. Following the application of crown prosthesis, no toothache recurred.

canal. It is clinically recognized that residual pulp tissue after root canal treatment and poor removal of root apical pulp tissue can cause postoperative pain, which can become chronic. Since dental pulp is a visceral tissue, pain arising from the dental pulp is similar to other types of visceral pain for which the actual pain site is difficult to pinpoint [1]. This may explain why our patient complained of pain in the unidentified left maxillary molar site in addition to MPRT. Nevertheless, thanks to diagnosis and treatment by an endodontist using a dental operating microscope enabled us to treat a root canal that was blocked by calcification. And an appropriate root canal treatment was performed without inducing pain secondary to destruction beyond the apical foramen, thereby eliminating the odontogenic toothache.

It is often difficult to distinguish nonodontogenic toothache from general odontogenic toothache [9] [10]. Among patients diagnosed with nonodontogenic toothache, 44% had undergone tooth removal or root canal treatment [4]. For this reason, patients with MPRT should be referred to orofacial pain specialists before the implementation of irreversible treatment [11] [12]. It is difficult both for dentists and for patients complaining of myofascial pain to characterize or identify the site and properties of the pain that may be relevant to myofascial pain. Subjective manifestations by patients with myofascial pain may lead dental physicians to diagnose nonodontogenic disease, mistakenly, as odontogenic disease. We do not know whether the endodontic procedures performed for tooth 27 before the patient's visit to our hospital were performed for odontogenic toothache, or performed irreversibly due to the inability to diagnose MPRT.

TP is not among the terms listed in the Diagnostic Criteria for Temporomandibular Disorders (DC/TMD) or International Classification of Orofacial Pain (ICOP). This may be explained by the paucity of pathophysiological verification of TP in basic research [13]. No studies reported to date offer high quality scientific evidence related to investigations of the efficacy of or scientific rationale for physical therapeutic care for nonodontogenic toothache. However, the American Academy of Orofacial Pain's Guidelines for Assessment, Diagnosis, and Management state that TPI can be diagnostically useful in distinguishing odontogenic from nonodontogenic toothache [14]. TPI is used in the diagnosis and treatment of MPRT, although its mechanisms are not completely understood. Furthermore, toothache is reportedly resolved by TPI [15]. Thus, TPI is recognized to be effective for reducing pain. In fact, TPI is performed in real-world settings to diagnose and treat MPRT. The masseter is predominantly involved in toothache, whether in the maxilla or mandible [3]. Other muscles involved in toothache include the temporalis, internal pterygoid muscle, lateral pterygoid muscle, digastric muscle, sternocleidomastoid muscle, and trapezius muscle [16]. In this particular patient, toothache relief was achieved with TPI of the temporalis.

TP is defined as a hypersensitive spot within a taut band of skeletal muscle that is painful on stimulation and gives rise to referred distant pain. The site at which TP induces referred pain is reportedly reproducible [1]. TP is classified as



active or latent. Latent TP is normally present and does not cause symptoms [15]. However, when myofascial pain becomes chronic, the TP is activated, generating referred pain [17]. To return active TP to a latent state, patients should be instructed to relax the muscles where TP is present. It is also important to provide instructions on physical therapeutic care, such as self-massage. Physical therapeutic care is an effective treatment for MPRT [18] [19]. Our patient was also instructed to maintain the specified physical therapeutic care.

Psychosocial factors are important in treating patients with myofascial pain. Psychosocial stressors contribute to the occurrence of myofascial pain in cases of temporomandibular disorder pain [20]. A tendency toward depression, particularly among women, is reported to contribute significantly to the occurrence of myofascial pain [21]. Therefore, the treatment of myofascial pain should also address psychosocial factors [22]. In our patient, a single diagnosis was considered. After root canal treatment, TP was confirmed, leading to a diagnosis of MPRT. Subsequent interviews for psychosocial items made the patient aware of sleep bruxism. Thus, the first self-care instructions for myofascial pain were delayed until three months after the initial visit. In our patient, since both odontogenic toothache and nonodontogenic toothache were present simultaneously during the initial period, a tenderness test of the left temporalis was unable to always reproduce the pain. However, a second tenderness test following the removal of odontogenic toothache via an endodontic procedure may have reproduced the nonodontogenic toothache. Regarding the multiple causes of pain in this case, it is unclear whether the prolonged symptoms due to apical periodontitis played a role as a psychosocial stress, causing sleep bruxism and resulting in mixed symptoms with MPRT or if the patient had begun experiencing chronic sleep bruxism before then. In any case, both odontogenic and nonodontogenic toothache diagnoses at an early stage appear to be essential in avoiding complex pain exacerbation and transformation to chronic pain.

#### **4. Conclusion**

The implementation of reliable treatment for odontogenic toothache is essential even in cases in which a prolonged disease state makes chronic pain the first diagnosis. Patients with chronic symptoms are often diagnosed as having nonodontogenic toothache, but caution should be exercised when prolonged odontogenic toothache and nonodontogenic toothache occur at the same time, as in this case. And specialized techniques may be required for the treatment of both odontogenic toothache and nonodontogenic toothache. Effective diagnosis of toothache requires comprehensive clinical knowledge as it involves more than simply classifying it as either odontogenic or nonodontogenic.

#### **Consent**

The patient has given her consent for this report to be published and it is in her chart at the Nihon University Hospital at Matsudo.

## Conflicts of Interest

The authors declare no conflicts of interest regarding the publication of this paper.

## References

- [1] Okeson, J. (2014) Bell's Oral and Facial Pain. 7th Edition, Quintessence, Chicago.
- [2] Kalladka, M., Thondebhavi, M., Ananthan, S., Kalladka, G. and Khan, J. (2020) Myofascial Pain with Referral from the Anterior Digastric Muscle Mimicking a Toothache in the Mandibular Anterior Teeth: A Case Report. *Quintessence International*, **51**, 56-62.
- [3] Wright, E.F. (2000) Referred Craniofacial Pain Patterns in Patients with Temporomandibular Disorder. *Journal of the American Dental Association*, **131**, 1307-1315. <https://doi.org/10.14219/jada.archive.2000.0384>
- [4] Linn, J., Trantor, I., Teo, N., Thanigaivel, R. and Goss, A.N. (2007) The Differential Diagnosis of Toothache from Other Orofacial Pains in Clinical Practice. *Australian Dental Journal*, **52**, 100-104. <https://doi.org/10.1111/j.1834-7819.2007.tb00518.x>
- [5] Sanner, F. (2010) Acute Right-Sided Facial Pain: A Case Report. *International Endodontic Journal*, **43**, 154-162. <https://doi.org/10.1111/j.1365-2591.2009.01654.x>
- [6] Murakami, Y., Hirata, A., Ito, S., Shoji, M., Tanaka, S., *et al.* (2007) Re-evaluation of Cyclooxygenase-2-Inhibiting Activity of Vanillin and Guaiacol in Macrophages Stimulated with Lipopolysaccharide. *Anticancer Research*, **27**, 801-807.
- [7] Farella, M., Michelotti, A., Gargano, A., Cimino, R. and Ramaglia, L. (2002) Myofascial Pain Syndrome Misdiagnosed as Odontogenic Pain: A Case Report. *Cranio*, **20**, 307-311. <https://doi.org/10.1080/08869634.2002.11746224>
- [8] Nakazawa, H., Baba, T. and Tsujimoto, Y. (2016) Analysis Fused of Root and Root Canal Morphology of Maxillary First and Second Molars Using Multi-Detector CT in a Japanese Population. *The International Journal of Microdentistry*, **7**, 36-48.
- [9] Kleier, D.J. (1985) Referred Pain from A Myofascial Trigger Point Mimicking Pain of Endodontic Origin. *Journal of Endodontics*, **11**, 408-411. [https://doi.org/10.1016/S0099-2399\(85\)80030-3](https://doi.org/10.1016/S0099-2399(85)80030-3)
- [10] Farella, M., Michelotti, A., Gargano, A., Cimino, R. and Ramaglia, L. (2002) Myofascial Pain Syndrome Misdiagnosed as Odontogenic Pain: A Case Report. *Cranio*, **20**, 307-311. <https://doi.org/10.1080/08869634.2002.11746224>
- [11] Markman, S., Howard, J. and Quek, S. (2008) Atypical Odontalgia—A Form of Neuropathic Pain That Emulates Dental Pain. *Journal of the New Jersey Dental Association*, **79**, 27-31.
- [12] Ram, S., Teruel, A., Kumar, S.K. and Clark, G. (2009) Clinical Characteristics and Diagnosis of Atypical Odontalgia: Implications for Dentists. *Journal of the American Dental Association*, **140**, 223-228. <https://doi.org/10.14219/jada.archive.2009.0136>
- [13] De Laat, A. (2020) Differential Diagnosis of Toothache to Prevent Erroneous and Unnecessary Dental Treatment. *Journal of Oral Rehabilitation*, **47**, 775-781. <https://doi.org/10.1111/joor.12946>
- [14] De Leeuw, R. and Klasser, G.D. (2018) Orofacial Pain: Guidelines for Assessment, Diagnosis, and Management. 6th Edition, Quintessence, Chicago.
- [15] Mascia, P., Brown, B.R. and Friedman, S. (2003) Toothache of Nonodontogenic Origin: A Case Report. *Journal of Endodontics*, **29**, 608-610.

<https://doi.org/10.1097/00004770-200309000-00015>

- [16] Simons, D.G. and Travell, J.G. (1983) Myofascial Pain and Dysfunction: The Trigger Point Manual. 1st Edition, Williams & Wilkins, Baltimore.
- [17] Alonso-Blanco, C., Fernández-de-Las-Peñas, C., de-la-Llave-Rincón, A.I., Zarco-Moreno, P., Galán-Del-Río, F. *et al.* (2012) Characteristics of Referred Muscle Pain to the Head from Active Trigger Points in Women with Myofascial Temporomandibular Pain and Fibromyalgia Syndrome. *The Journal of Headache and Pain*, **13**, 625-637. <https://doi.org/10.1007/s10194-012-0477-y>
- [18] Yatani, H., Komiyama, O., Matsuka, Y., Wajima, K., Muraoka, W., *et al.* (2014) Systematic Review and Recommendations for Nonodontogenic Toothache. *Journal of Oral Rehabilitation*, **41**, 843-852. <https://doi.org/10.1111/joor.12208>
- [19] Money, S. (2017) Pathophysiology of Trigger Points in Myofascial Pain Syndrome. *Journal of Pain & Palliative Care Pharmacotherapy*, **31**, 158-159. <https://doi.org/10.1080/15360288.2017.1298688>
- [20] Cairns, B.E. (2010) Pathophysiology of TMD Pain—Basic Mechanisms and Their Implications for Pharmacotherapy. *Journal of Oral Rehabilitation*, **37**, 391-410. <https://doi.org/10.1111/j.1365-2842.2010.02074.x>
- [21] Giannakopoulos, N.N., Keller, L., Rammelsberg, P., Kronmüller, K.T. and Schmitter, M. (2010) Anxiety and Depression in Patients with Chronic Temporomandibular Pain and in Controls. *Journal of Dentistry*, **38**, 369-376. <https://doi.org/10.1016/j.jdent.2010.01.003>
- [22] Dıraçoğlu, D., Yıldırım, N.K., Saral, İ., Özkan, M., Karan, A., *et al.* (2016) Temporomandibular Dysfunction and Risk Factors for Anxiety and Depression. *Journal of Back and Musculoskeletal Rehabilitation*, **29**, 487-491. <https://doi.org/10.3233/BMR-150644>