

Epidemic to Different Strains of SERRATIA: Experience of Neonatal Intensive Care Unit: About 30 Cases

Fatima-Ezzahra Tahiri^{1,2*}, Abdessamad Lalaoui^{1,2}, Hasna Rafi^{1,2}, Fatiha Bennaoui^{1,2},
Nadia El Idrissi Slitine^{1,2}, Nabila Soraa³, Fadl Marabih Rabou Maoulainine^{1,2}

¹Neonatal Intensive Care Unit, CHU Mohammed VI, Marrakech, Morocco

²Health, Childhood and Development Faculty of Medicine Research Team, Cadi Ayyad University, Marrakech, Morocco

³Microbiology Department, CHU Mohammed VI, Marrakech, Morocco

Email: *fatimaezzahratahiri29@gmail.com

How to cite this paper: Tahiri, F.-E., Lalaoui, A., Rafi, H., Bennaoui, F., Slitine, N.E.I., Soraa, N. and Maoulainine, F.M.R. (2023) Epidemic to Different Strains of SERRATIA: Experience of Neonatal Intensive Care Unit: About 30 Cases. *Open Journal of Pediatrics*, 13, 253-261.

<https://doi.org/10.4236/ojped.2023.132031>

Received: February 8, 2023

Accepted: March 20, 2023

Published: March 23, 2023

Copyright © 2023 by author(s) and Scientific Research Publishing Inc.

This work is licensed under the Creative Commons Attribution International License (CC BY 4.0).

<http://creativecommons.org/licenses/by/4.0/>



Open Access

Abstract

Serratia is an opportunistic pathogenic bacterium of the Enterobacteriaceae family, occasionally responsible for epidemics of nosocomial infections in critical departments; in particular in neonatal intensive care units Enterobacteriaceae form a large family of Gram-negative bacteria, which cause diseases of highly variable severity, due to distinct pathogenic mechanisms. This family is heterogeneous as it consists of about 30 genera of bacteria and more than 100 species. However, all these germs have in common their preferential location in the digestive system, some being part of the normal flora although they are also present in the environment. Several metabolic processes characterize this bacterial family. These include the ability to reduce nitrate to nitrite (for energy generation), ferment glucose, lack cytochrome oxidase, be aerobic or anaerobic, motile or immobile, ... Enterobacteriaceae constitute more than 80% of the germs isolated in the laboratory: *Escherichia*, *Salmonella*, *Shigella*, *Klebsiella*, *Enterobacter*, *Serratia*, *Proteus*, *Morganella* and *Yersinia* are the rods most often found. Regarding nosocomial infection to Serratia, this bacterium colonizes the respiratory, digestive and urinary systems of patients, mainly responsible for bacteremia, infections of the lower respiratory tract, urinary and skin infections. Through our work, we report the epidemic experienced in the neonatal intensive care unit MOHAMMED VI university hospital, mother-child hospital MARRAKECH MOROCCO for three months from December at February 2023 interesting 30 newborns whose clinical presentation was different, the positive diagnosis was based on blood and geographical samples taken by the bacteriology department to isolate the offending germs, the therapeutic management of our patients consisted essentially of various hygiene measures in association with dual anti-

otic therapy based on meropenem and amikacin. The evolution was marked by the death of 21 patients (70%) and the recovery of 9 patients (30%). The prognosis of infection by *Serratia* remains bleak with high morbidity interest in prevention by respecting the rules of hygiene, which begins with hand disinfection.

Keywords

Epidemic, Neonatal Resuscitation, Nosocomial Infection, *Serratiamarcesens*, *Serratiaureitylica*, *Serratia Nematodiphila*, Antibiotic Resistance

1. Introduction

The *Serratia* species belongs to the Enterobacteriaceae family, commonly found in water, soil, animals, insects, plants.

Although *Serratia* displays relatively low virulence, it causes nosocomial infections and outbreaks in severely immunocompromised or critically ill patients, especially in settings such as intensive care units, especially neonatal units. This microorganism gives rise to a wide range of clinical manifestations in neonates: from asymptomatic colonization to keratitis, conjunctivitis, urinary tract infections, pneumonia, surgical wound infections, sepsis, bloodstream infection and meningitis. The most common site of infection is the bloodstream, followed by the respiratory tract and the gastrointestinal tract. *Serratia* strains implicated in epidemic events have often proven to be multi-resistant.

Indeed, this species displays an intrinsic resistance to several classes of antibiotics. Often, the precise source of infection cannot be identified. However, the contaminated hands of healthcare professionals are considered a major vehicle for its transmission. In neonatal intensive care units, colonized or infected neonates are the main potential source of *Serratia*, particularly in the respiratory tract, but also in the gastrointestinal tract. Early identification of colonized or infected patients and prompt implementation of infection control measures, particularly rigorous hand hygiene and contact precautions, are essential to curb the spread of infection.

2. Objective

Report our experience during the epidemic in *Serratia* and its different strains occurring between December and February 2023 involving 30 newborns hospitalized in the neonatal intensive care unit CHU MOHAMMED VI MARRAKECH MOROCCO.

Data collection was carried out using an exploitation sheet containing the various information necessary to establish this work.

3. Interest

Detect the various exposing risk factors to nosocomial infection by *Serratia*, the

clinical and paraclinical evolution as well as the therapeutic management of our patients according to their reasons for hospitalization and the means of prevention proposed through our experience.

4. Results

Our epidemic involved thirty newborns; the average age was 4.3 days with extremes ranging from 1 day to 21 days; the average gestational age in our series was 34 weeks of amenorrhea and 2 days.

The male sex predominated with a percentage of 60% or 18 newborns (Figure 1).

Pregnancy was followed in 66% of our patients, *i.e.* 20 of the newborns.

Delivery was medicalized vaginally in 23 of our patients (76%), tohome in a single patient, by caesarean section in 6 of our patients (30%) whose indications were as follows: two for maternal rescue following a severe pre-eclampsia, two for chorioamnionitis, one for bicatricial uterus and one for macrosomia in gestational diabetes.

The average birth weight was 2300 g with extremes ranging between 970 g and 4800 g.

The infectious anamnesis in the mothers of our patients was positive in 73% (22 cases) (Figure 2).

In our series, the reasons for hospitalization in order of frequency were as follows: respiratory distress due to prematurity in twenty-two patients, postnatal respiratory distress in three patients, neonatal jaundice in two patients, positive infection test in two patients and severe sepsis in a patient (Table 1).

In our series, 33% or 10 of our newborns had an umbilical catheter whose culture was positive in two patients, *onetoserratiaureitylica*, and the other to *serratiamarcescens*, the culture was sterile in the eight other patients.

The average time between hospitalization in our intensive care unit and the appearance of the nosocomial infection was 3.8 days with extremes ranging from 1 day to 10 days.

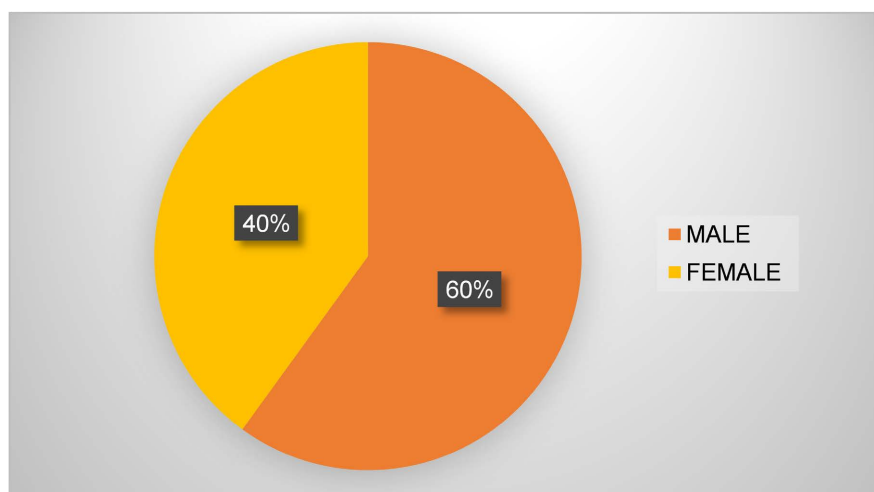


Figure 1. Gender distribution.

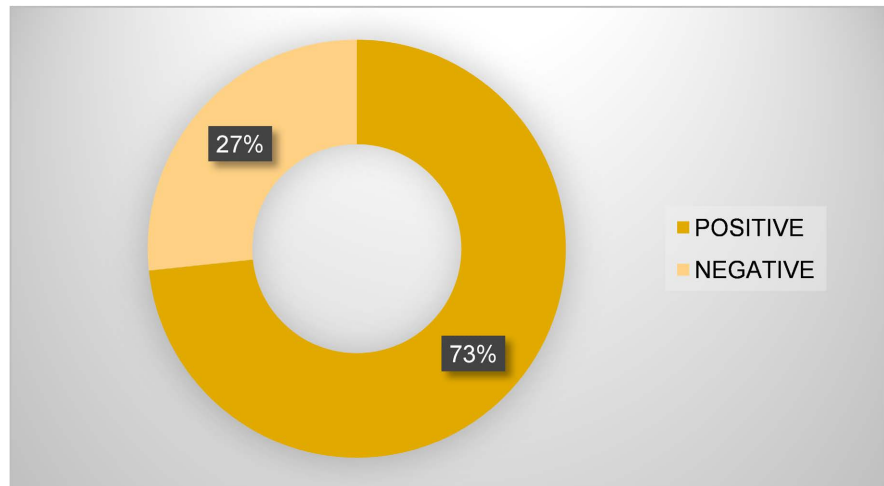


Figure 2. Infectious history in mothers.

Table 1. Reason for hospitalization of newborns.

Reason for hospitalization	Number of Cases
Prematurity and distress	22 cases
Postnatal respiratory distress	3 cases
Neonatal jaundice	2 cases
Positive infection test	2 cases
Sepsis	1 case

Blood culture carried out according to rigorous asepsis standards was positive in all our patients, 70% had a single germ, 30% had the association of two germs according to the figure below (**Figure 3**).

In our study, antibiotic susceptibility was determined by the agar medium diffusion method for each strain included ticarcillin, piperacillin, ampicillin, ticarcillin, piperacillin-tazobactam, amoxicillin-clavulanic acid, cefalotin, cefoxitin, cefotaxime, ceftazidime, cefixime, imipenem, ertapenem, meropenem, ciprofloxacin, tobramycin, gentamycin, amikacin, colistin, cefepime, tegecycline, ceftriaxone, levofloxacin, trimethoprim-sulfamethoxazole and ofloxacin confirming multi-resistance to all the antibiotics tested in 10 patients infected nine with *serratia marcescens* and one with *serratianematodiphila*, and intermediate sensitivity to imipenem, and meropenem in the remaining twenty patients.

The infectious assessment was disturbed in all our patients with a predominance of hematological abnormalities such as leukopenia in 70% of cases, hyperleukocytosis in 30% of cases, deep thrombocytopenia in 80% of cases, a manifest elevation of C-reactive protein in all our patients varying between 100 to 250 mg/l.

Lumbar puncture was performed in 8 of our patients, confirming meningitis to *serratiamarcescens* in three newborns, the rest of our patients had deep thrombocytopenia against indicating the realization of the lumbar puncture.

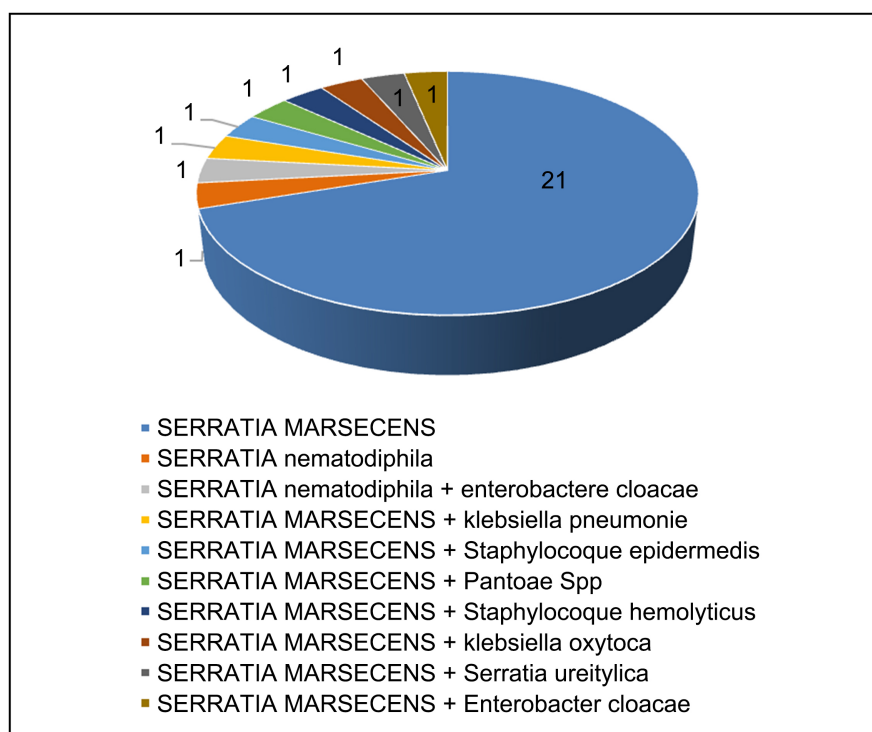


Figure 3. Germs isolated in our patients.

On the respiratory level, thirteen patients were under continuous positive Airways pressure CPAP (43%), ten patients were intubated (33%), three patients were on O₂ glasses (10%) and four patients were on spontaneous ventilation.

The treatment was based on bi-antibiotic therapy made of meropenem and amikacin with favorable outcome in 9 patients, the average duration of antibiotic therapy was 10 to 14 days for meropenem.

The average hospitalization time of our patients was 12 days, with extremes ranging from 10 days to 60 days.

The evolution was marked by the death of 21 patients (70%) and the recovery of 9 patients (30%).

Apart from medical treatment, managing the spread of our epidemic required training by the infectious disease control committee of the entire medical and paramedical team on the importance of hand hygiene. geographical isolation of infected patients, technical isolation of the equipment used, distribution of nursing staff to the different patients according to the isolated germ, total disinfection of the neonatal intensive care unit, local sampling of equipment, stopping of the hospitalization and all educational activities of the service in order to minimize contact with infected patients and the care of uninfected patients in the day hospital of our service.

5. Discussion

Nosocomial infections in neonatal intensive care units are a public health problem because of their serious consequences: high morbidity and mortality and the

significant cost they generate [1].

Species of the genus *Serratia* are facultative anaerobic, chemoorganotrophic bacteria with low nutritional requirements that belong to the family Enterobacteriaceae are Gram-negative rods that measure 0.9 - 2 µm in length and 0.5 - 0.8 µm of diameter.

They possess a peritrichous flagellum that allows them to swim and move in a propeller-like bundle (with differentiation) and they are ubiquitous in soil, water, and on plant surfaces [2] [3].

Its transmission is by direct contact with the mucous membrane, by the soiled hand, medical devices, intravenous fluids, solutions and liquids for humidifying contaminated respirators [4] [5] [6], but there is no transmission directly from person to person.

Serratia has been shown to be a currently recognized pathogen of nosocomial infection in neonates, especially in epidemic form [7], which has also been reported in our experience.

We reported 30 cases of nosocomial infection with different strains of *Serratia* during the three months of December, January and February 2023.

In comparison with a study published in 2010 by Gulcin Bayramoglu *et al.*, including 9 cases, in the neonatal intensive care unit over a period of 36 days [7].

The sources of contamination reported in the literature by *Serratia* were the following: catheters, heparin solution, dialysis machine, propofol, liquid soap [8] [9] [10] and of course manual transmission due to lack of hygiene in the hospitals.

According to Al Jarousha and his colleagues, the risk factors for nosocomial *Serratia* infection are statistically significant: birth weight less than 1500 g, gestational age less than 37 weeks and mechanical ventilation [9].

Other risk factors common to all nosocomial infections are long hospital stays, the prescription of antibiotics and the use of invasive methods: umbilical catheter, intubation, bladder catheterization and parenteral nutrition [6].

In our series, we had 80% premature and 76% under ventilatory support, the average weight was 2300 g, ten newborns had an umbilical catheter.

Serratia and its different strains may be responsible for sepsis, pneumonia, conjunctivitis, urinary tract infections and even gastroenteritis in newborns.

In a study by Morillo *et al.*, the clinical manifestations observed in ascending order were pneumonia, conjunctivitis, sepsis and urinary tract infection [11] whereas in our series sepsis followed by respiratory infection were the main events.

Neurological complications have recently been reported to be more frequent with *Serratia marcescens*, namely, meningitis, brain abscess, and empyema, for this it is recommended to systematically perform brain imaging and more particularly transfontanelar ultrasound, even in the absence of neurological signs [2].

In our series, we diagnosed three cases of multi-resistance *serratiamarcescens*

meningitis, trans-fontanellar ultrasound showing an aspect of ventriculitis with tetraventricular hydrocephalus.

Regarding the resistance of *Serratia* to antibiotics, high resistance to cephalosporins is often reported, which can reach 100% [5] [12]. In our study, the rate of resistance to cephalosporin matches that of the literature. Ten strains were resistant to imipenem and ciprofloxacin, which is inconsistent with the results reported by Al Jarousha, who reported susceptibility of 90% to imipenem and 76% to ciprofloxacin [7]. With regard to colistin, all isolated strains were resistant and corresponded to the results of Buffet-Battalion *et al.* [3] and those of Adjid *et al.* [12].

There are two types of resistance: natural and acquired.

Natural resistance is a known phenomenon, constant and transmissible to offspring. *S. marcescens* presents a natural or intrinsic resistance to several antibiotics, in this case, the resistance to a given antibiotic concerns all strains of this species.

Like all enterobacteriaceae, *Serratiamarcescens* is naturally resistant to penicillin G, macrolides, clindamycin and glycopeptides.

It is also resistant to polymyxins, aminopenicillins and first and second generation cephalosporins by production of an inducible chromosomal cephalosporin.

Serratia marcescens shows significant multiresistance to antibiotics worldwide, namely β -lactams, aminoglycosides and quinolones. It is well established that strains of *Serratia marcescens* can rapidly develop resistance to multiple β -lactams.

S. marcescens has also shown acquired resistance to aminoglycosides and quinolones mainly through the production of enzymes.

β -lactams are generally used to treat severe infections in combination with other families of antibiotics [3] [6] [8] [13]-[18].

Recently, an increase in the frequency of resistance of Enterobacteriaceae including *Serratia marcescens* to aminoglycosides by the production of antibiotic modifying enzymes by adenylation, phosphorylation or acetylation, has been described worldwide [19] [20] [21] [22].

In addition to *Serratia's* resistance to antibiotics, its severity is evident in light of the high reported mortality rates, which range from 14.3% to 62.5% of cases [4] [6] [7] [12] [13], but in our study, we have a higher rate which was 70% given the high number of infected patients in comparison with the different series in the literature.

To deal with these epidemics, a number of measures have been recommended, mainly the education of medical and paramedical personnel on the importance of hand hygiene, the use of double protection by gloves, technical isolation and geographic location of infected patients and disinfection of any surfaces or equipment likely to be contaminated [7].

In our study, we applied the international standards of prevention against

nosocomial infection, each newborn was isolated in a box with hand washing before and after each gesture of care, this individualization makes it easy to observe the measures, hygiene and septic isolation, strengthening hand hygiene with the use of hydroalcoholic solutions, compliance with asepsis rules during invasive care and raising parents' awareness of hand hygiene.

6. Conclusions

Nosocomial infections caused by the different strains of *Serratia* have not only led to increased mortality, morbidity, and cost of treatment, but also continue to endanger the vital prognosis of newborns.

The lack of hand hygiene and asepsis are the probable causes of cross-contamination with *Serratia* producing extended-spectrum beta-lactamase (ESBL). The strengthening of hygiene rules will prevent or control this type of epidemic.

Conflicts of Interest

The authors declare no conflicts of interest regarding the publication of this paper.

References

- [1] Chemsî, M., Zerouali, K., Chahid, I., *et al.* (2013) Incidence of Nosocomial Infections Abderrahim Harouchi, CHU Ibn Rochd, Casablanca, Morocco. *Journal of Pediatrics and Childcare*, **26**, 11-18. <https://doi.org/10.1016/j.jpp.2012.11.001>
- [2] Adjidé, C.C., Li-Thiao-Te, V., Biendo, M., Weibel, B., Laurans, G. and Krim, G. (2004) Étude cas-témoins d'une épidémie à *Serratia marcescens* dans un service de réanimation pédiatrique. *Pathologie Biologie*, **52**, 423-424. <https://doi.org/10.1016/j.patbio.2004.07.019>
- [3] Arslan, U., Erayman, I., Kirdar, S., *et al.* (2010) *Serratia marcescens* Sepsis Outbreak in a Neonatal Intensive Care Unit. *Pediatrics International*, **52**, 208-212. <https://doi.org/10.1111/j.1442-200X.2009.02934.x>
- [4] Bayramoglu, G., Buru, K., Dinc, U., Mutlu, M., Yilmaz, G. and Aslan, Y. (2011) Investigation of an Outbreak of *Serratia marcescens* in a Neonatal Intensive Care Unit. *Journal of Microbiology, Immunology and Infection*, **44**, 111-115. <https://doi.org/10.1016/j.jmii.2010.02.002>
- [5] Morillo, A., González, V., Aguayo, J., *et al.* (2016) A Six-Month *Serratia marcescens* Outbreak in a Neonatal Intensive Care Unit. *Enfermedades Infecciosas y Microbiología Clínica*, **34**, 645-651. <https://doi.org/10.1016/j.eimc.2016.01.006>
- [6] Doaa, M. and Omnia, S. (2014) Bacterial Nosocomial Infections in Neonatal Intensive Care Unit, Zagazig University Hospital, Egypt. *Egyptian Pediatric Association Gazette*, **62**, 72-79. <https://doi.org/10.1016/j.jpp.2012.11.001>
- [7] Jarousha, K.A.M., Qouqa, I.A., Jadba, A.H.N. and Afifi, A.S. (2008) An Outbreak of *Serratia marcescens* Septicaemia in Neonatal Intensive Care Unit in Gaza City, Palestine. *Journal of Hospital Infection*, **70**, 119-126. <https://doi.org/10.1016/j.jhin.2008.06.028>
- [8] van der Vorm, E.R. and Woldring-Zwaan, C. (2002) Source, Carriers, and Management of a *Serratia marcescens* Outbreak on a Pulmonary Unit. *Journal of Hospital Infection*, **52**, 263-267. <https://doi.org/10.1053/jhin.2002.1313>

- [9] Perotti, G., Bernardo, M.E., Spalla, M., Matti, C., Stronati, M. and Pagani, L. (2007) Rapid Control of Two Outbreaks of *Serratia marcescens* in a Northern Italian Neonatal Intensive Care Unit. *Journal of Chemotherapy*, **2**, 56-60. <https://doi.org/10.1080/1120009X.2007.11782448>
- [10] Sartor, C., Jacomo, V., Duvivier, C., Tissot-Dupont, H., Sambuc, R. and Drancourt, M. (2000) Nosocomial *Serratia marcescens* Infections Associated with Extrinsic Contamination of a Liquid Nonmedical Soap. *Infection Control and Hospital Epidemiology*, **21**, 196-199. <https://doi.org/10.1086/501743>
- [11] Madide, A. and Smith, J. (2016) Intracranial Complications of *Serratia marcescens* Infection in Neonates. *South African Medical Journal*, **106**, 342-344. <https://doi.org/10.7196/SAMJ.2016.v106i4.10206>
- [12] Buffet-Bataillon, S., Rabier, V., Bétrémieux, P., et al. (2009) Outbreak of *Serratia marcescens* in a Neonatal Intensive Care Unit: Contaminated Unmedicated Liquid Soap and Risk Factors. *Journal of Hospital Infection*, **72**, 17-22. <https://doi.org/10.1016/j.jhin.2009.01.010>
- [13] Sambuc, R. and Drancourt, M. (2000) Nosocomial *Serratia marcescens* Infections Associated with Extrinsic Contamination of a Liquid Nonmedical Soap. *Infection Control and Hospital Epidemiology*, **21**, 196-199. <https://doi.org/10.1086/501743>
- [14] van der Sar-van der Brugge, S., Arend, S.M., Bernerds, A.T., Berbee, G.A.M., Westendorp, R.G.J., Feuth, J.D.M., et al. (1999) Risk Factors for Acquisition of *Serratia marcescens* in a Surgical Intensive Care Unit. *Journal of Hospital Infection*, **41**, 291-299. <https://doi.org/10.1053/jhin.1998.0498>
- [15] Smith, J.P., Brookfield, D.S.K., Shaw, D.A. and Gray, J. (1984) An Outbreak of *Serratia marcescens* Infection in a Neonatal Unit. *The Lancet*, **323**, 151-153. [https://doi.org/10.1016/S0140-6736\(84\)90074-6](https://doi.org/10.1016/S0140-6736(84)90074-6)
- [16] Shields, J.A., Shields, C.L., Eagle, R.C. and Moster, M. (2000) Localized Infection by *Serratia marcescens* Simulating a Conjunctival Neoplasm. *American Journal of Ophthalmology*, **129**, 247-248. [https://doi.org/10.1016/S0002-9394\(99\)00422-5](https://doi.org/10.1016/S0002-9394(99)00422-5)
- [17] Henry, B., Plante-Jenkins, C. and Ostrowska, K. (2001) An Outbreak of *Serratia marcescens* with Anesthetic Agent Propofol. *American Journal of Infection Control*, **29**, 312-315. <https://doi.org/10.1067/mic.2001.117043>
- [18] Jones, B.L., Gorman, L.J., Simpson, J., Curran, E.T., McNamee, S., Lucas, C., et al. (2000) An Outbreak of *Serratia Marcescens* in Two Neonatal Intensive-Care Unit. *Journal of Hospital Infection*, **46**, 314-319. <https://doi.org/10.1053/jhin.2000.0837>
- [19] Giri, A.V., Anandkumar, N., Muthukumar, G. and Pennathur, G. (2004) A Novel Medium for the Enhanced Cell Growth and Production of Prodigiosin from *Serratia Marcescens* Isolated from Soil. *BMC Microbiology*, **4**, Article No. 11. <https://doi.org/10.1186/1471-2180-4-11>
- [20] Aronson, L.C. and Alderman, S.I. (1943) The Occurrence and Bacteriological Characteristics of *S. Marcescens* from a Case of Meningitis. *Journal of Bacteriology*, **46**, 261-267. <https://doi.org/10.1128/jb.46.3.261-267.1943>
- [21] Cristina, M.L., Sartini, M. and Spagnolo, A.M. (2019) *Serratia Marcescens* Infections in Neonatal Intensive Care Units (NICUs). *International Journal of Environmental Research and Public Health*, **16**, Article 610. <https://doi.org/10.3390/ijerph16040610>
- [22] Montagnani, C., Cocchi, P., Lega, L., Campana, S., Biermann, K.P., Braggion, C., et al. (2015) *Serratia marcescens* Outbreak in a Neonatal Intensive Care Unit: Crucial Role of Implementing Hand Hygiene among External Consultants. *BMC Infectious Diseases*, **15**, Article No. 11. <https://doi.org/10.1186/s12879-014-0734-6>