

Type VI Aplasia Cutis Congenita: About a Case Report at University Teaching Hospital of Bouaké

Yao Kouassi Christian*, Yeboua Yao Kossonou Roland, Yenan John Patrick, Akanji Iburaima Alamun, Adou Leioh Romeo, Sahi Gnantin Josette Landryse, Amani Ehi Alexise Eleonore, Avi-Siallou Christelle Honorine, Aka-Tanoh Koko Aude Hélène, Asse Kouadio Vincent

Department of Pediatrics, University Teaching Hospital of Bouaké, Bouaké, Côte d'Ivoire

Email: *yaokc777@gmail.com, rolandyeboua13@gmail.com, johnyenan@yahoo.fr, iburaima@yahoo.com, leioh91@gmail.com, firstsahi@yahoo.com, amanialexise91@gmail.com, avischristelle611@gmail.com, audeka@gmail.com, assevinc2014@gmail.com

How to cite this paper: Christian, Y.K., Roland, Y.Y.K., Patrick, Y.J., Alamun, A.I., Romeo, A.L., Landryse, S.G.J., Eleonore, A.E.A., Honorine, A.-S.C., Hélène, A.-T.K.A. and Vincent, A.K. (2023) Type VI Aplasia Cutis Congenita: About a Case Report at University Teaching Hospital of Bouaké. *Open Journal of Pediatrics*, 13, 146-152.

<https://doi.org/10.4236/ojped.2023.131018>

Received: November 18, 2022

Accepted: January 26, 2023

Published: January 29, 2023

Copyright © 2023 by author(s) and Scientific Research Publishing Inc.

This work is licensed under the Creative Commons Attribution International License (CC BY 4.0).

<http://creativecommons.org/licenses/by/4.0/>



Open Access

Abstract

Introduction: Aplasia cutis congenita is a rare congenital dermatosis of which type VI represents the Bart's syndrome. The aim of this case is to describe the epidemiological, clinical, therapeutic and prognostic characteristics of this condition in a country with limited resources, for the improvement of prognosis and professional practice. **Observation:** This is a eutrophic newborn, born at term by vaginal delivery, who presented at birth with a unilateral absence of skin on the anteromedial aspect of the right leg starting from the knee and extending to the medial aspect of the right foot, with a dystrophy of the nail of the right big toe without any other visible physical malformation. The evolution was marked at D3 of life by the appearance of bullae on the right hand and elbow as well as on the posterior aspect of the neck, making epidermolysis bullosa suspect. The mother was 38 years old, 8th gesture, 7th pare with history of consanguinity and collodion baby. The association of a localized congenital absence of skin on the lower limbs, epidermolysis bullosa and a nail anomaly led to the diagnosis of congenital cutaneous aplasia of type VI of Frieden's classification or Bart's syndrome. The evolution was satisfactory on the 7th day of life with the beginning of scarring. The management was medical. The outcome was unfavorable with the appearance of sepsis and hemorrhage leading to death. **Conclusion:** Although rare, the clinical diagnosis of Bart's syndrome is simple. However, the management is complex and the prognosis is reserved. To improve this prognosis, the treatment must guarantee excellent control of the infectious and hemorrhagic risks, an adhesion and good therapeutic compliance by the parents and a ri-

gorous monitoring.

Keywords

Aplasia Cutis Congenita, Bart's Syndrome, Newborn, Prognosis, Côte d'Ivoire

1. Introduction

Bart's syndrome is a very rare congenital dermatosis. It belongs to the group of Aplasia cutis congenita (ACC) of which nine clinico-genetic types have been described [1] [2]. It combines congenital skin aplasia, lesions of the lower limbs and epidermolysis bullosa [1]. The clinical diagnosis of Bart's syndrome is usually easy, characterized by well-delimited, translucent, ulcerated membranes through which the underlying structures are visualized [3]. Despite the simplicity of the diagnosis, its prognosis remains guarded [4]. Management is medical and/or surgical depending on the extent and depth of the lesions [5]. The majority of cases in the literature are reported on white skin [6]. We describe a case of Bart's syndrome or ACC type VI on black skin, its management in our context of a country with limited resources and its evolution for the improvement of the prognosis and professional practice.

2. Observation

C.G., 38 years old, was admitted to the delivery room for pelvic pain with uterine contractions in a full-term pregnancy. The pregnancy history revealed a regularly monitored pregnancy, with six prenatal visits, a complete prenatal check-up with no abnormalities, and correct anti-anemia, anti-tetanus and anti-malaria prophylaxis. There was no pathology during the pregnancy, no notion of radiant imaging, and no use of fetotoxic drugs. Both parents were cousins, apparently healthy with no abnormalities of the skin, dander or mucous membranes. The mother was 8th gestational, 7th pare, with a history of a premature newborn who died as a result of generalized dermatologic lesions reminiscent of a collodion baby. The obstetrical examination showed regular and painful uterine contractions, a uterine height of 32 cm, a shortened cervix, open to two fingers with a bulging water sac. The evolution was marked three hours later by a vaginal delivery of a full-term male newborn, weighing 2900 grams, with an Apgar score of 7 at the 1st minute and 9 at the 5th minute, height at 52 centimeters, head circumference at 33 centimeters and absence of skin substances on the right lower limb. The essential care of the newborn was performed in the delivery room and then he was transferred to the neonatology unit. On physical examination, the newborn was neurologically, cardiac, and respiratory stable, with a unilateral absence of skin on the anteromedial aspect of the right leg extending from the knee to the medial aspect of the right foot. This lesion was well limited, covered by a very thin translucent red membrane, exposing easily visualized muscle and

vascular structures (**Figure 1**).

There was a dystrophy of the right big toe nail, the rest of the skin was normal and the scalp was macroscopically healthy. No visible malformation was noted. In view of these signs, the management consisted of placing the baby in an incubator, providing sufficient hydroelectrolytes and energy, ceftriaxone and gentamycin-based biobiotic therapy to prevent superinfection, and twice-daily local care with greasy tulle. Additional examinations were then prescribed. Blood count and C-reactive protein were normal. Transfontanelar, cardiac and abdominal ultrasounds were normal. After 3 days, the newborn presented with bullae on the right hand and elbow and on the posterior aspect of the neck, raising suspicion of epidermolysis bullosa (**Figure 2**). Skin biopsy and histopathological examination of the bullae were not performed because of the insufficient technical picture. The combination of congenital absence of skin on the lower limbs, epidermolysis bullosa and nail abnormality led to the diagnosis of Frieden's type VI ACC, also known as Bart's syndrome. The newborn was discharged on the 7th day of hospitalization with a satisfactory clinical condition. The mother was given detailed instructions on handling the baby and continuing local wound care with a topical antibacterial cream (2% fusidic acid cream) applied twice daily

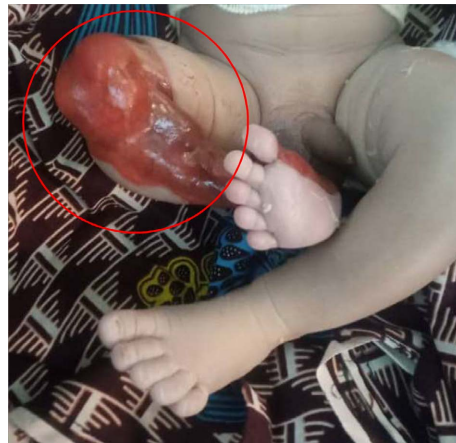

Figure 1. Aplasia cutis congenita of the left lower limb.

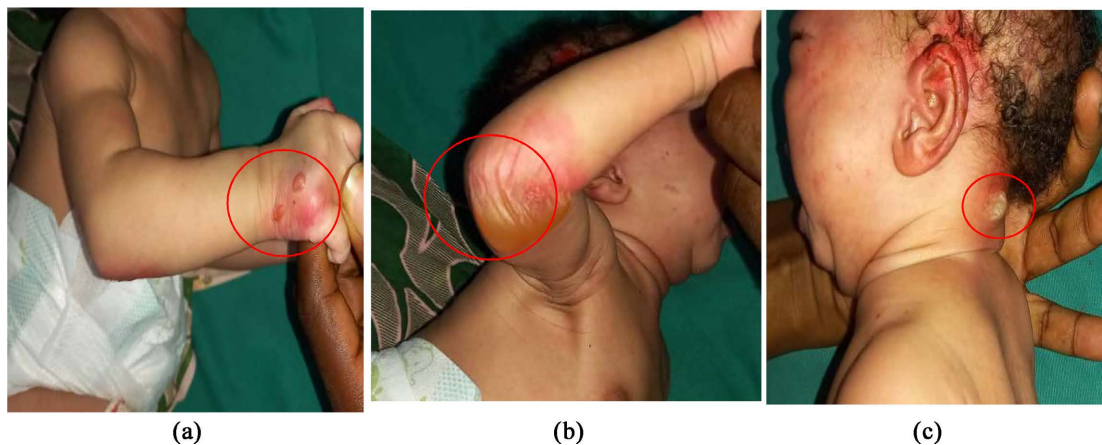


Figure 2. Bullous lesions on the back of the right hand (a), the right elbow (b) and the back of the neck (c).

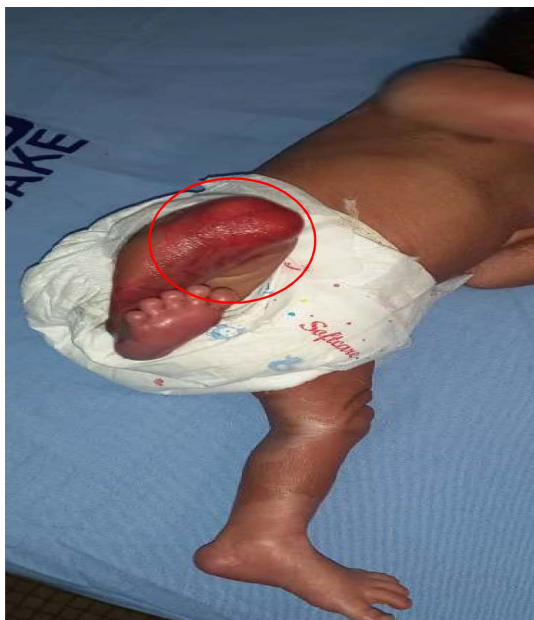

Figure 3. Lesions in the process of healing.

and a non-adhesive dressing. Also, the neonate was seen in dermatology and pediatrics consultation once a week. At the first visit at 14 days of age, the lesion was healing, the bullae had disappeared (**Figure 3**) and the newborn had no signs of vital distress. At 19 days of life, the neonate was admitted to the pediatric emergency department for poor general impression. The general examination revealed a febrile newborn (temperature 39°C), frank mucocutaneous pallor, tachycardia, hypoxemic tachypnea (SpO₂ at 78% room air). On neurological examination, the anterior fontanel was normotensive, hypotonia was noted with abolition of archaic reflexes. The dressing covering the wound was blood-stained and fetid. The rest of the examination was normal. Management consisted of oxygen therapy by mask, vascular filling with saline. A blood sample was taken for biological assessment (CBC, blood group-Rhesus, thickened drop-blood smear, blood culture, CRP, cytobacteriological and chemical examination of the CSF), and then a biantibiotherapy (cefotaxime + gentamycin) was administered. The wound was cleaned and disinfected with a chlorine-based antiseptic preparation (Dakin Cooper®). The outcome of this neonate was fatal 35 minutes after admission.

3. Discussion

Bart's syndrome or ACC type VI is an extremely rare congenital skin disease first described in 1966 [7]. CCA is a rare congenital dermatosis characterized by a localized or extensive skin defect acquired in utero. There are nine types whose pathophysiological mechanisms are not yet clearly elucidated and vary according to the type [2]. These etiologies, according to the hypotheses, could be genetic, vascular, infectious, teratogenic, as well as the amniotic bridges syndrome and the papyrate fetus syndrome [6]. In the present case, we found a notion of con-

sanguinity in the 2nd degree and a history of a premature baby in the siblings who presented skin anomalies similar to congenital ichthyosis. These pre-existing factors could contribute to the occurrence of neonatal malformation [8]. The search for a genetic work-up would have revealed a genetic mutation in the BMS 1 and DLL 4 genes reported in the literature [1]. In our context, these examinations could not be performed due to the lack of technical facilities. Thus, we based our diagnosis on clinical arguments, even if in certain situations a skin biopsy may be necessary to establish a differential diagnosis with other causes of epidermolysis bullosa [1]. Clinically, the skin lesions in Bart's syndrome present as bilateral reddish ulcerated lesions with clear borders extending most often to the medial and posterior aspect of the feet up to the shins [9]. This description of this pathology was found in our context. It is imperative to look for other congenital anomalies associated with the diagnosis of Bart's syndrome in the digestive tract (pyloric atresia), urinary tract (ureteral stenosis, renal anomalies) and facial tract (hypoplasia of the ear, flattening of the nose, hypertelorism) [10]. However, in the case we report, clinical examination and imaging did not reveal any malformation. The management of Bart's syndrome is medical and/or surgical depending on the extent of the skin lesions. In case of focal lesions, it usually involves medical treatment of the wounds with removal of blister fluid with a sterile needle, cleaning with saline and application of a skin antiseptic (silver sulfadiazine cream, bacitracin ointment) to the lesions [11] [12] [13]. For the control of possible infections, antibiotic therapy is most often instituted, sometimes the use of hydro debridement and mechanical debridement is necessary to prevent infection and help the wound to contract [11] [12]. For the maintenance of moist wounds, their protection against trauma and the reduction of contact dermatitis, a dressing with Vaseline gauze seems to be very effective [11] [12]. When the lesions are very extensive and deep, the management of patients may require surgical treatment such as skin grafting or local flaps [11] [14]. In this clinical case, the neonate received medical and conservative treatment consisting of antibiotic therapy and twice-daily local care with fatty tulle. Ambulatory management consisted of twice-daily application of fusidic acid cream to the wounds and weekly non-adhesive dressings. After this treatment, the evolution was marked by the beginning of healing on the 14th day of life. The prognosis of Bart's syndrome is guarded and depends on several factors, most often interrelated. These are clinical factors (severity and extension of the ACC, subtype of epidermolysis bullosa, associated anomalies) and therapeutic factors (compliance with treatment) [15]. Thus, the evolution can be favorable or enameled with hemorrhagic, infectious, metabolic (hypoglycemia) and nutritional complications that can jeopardize the vital prognosis of the newborn. In this case, the complications were hemorrhage and sepsis, which led to the patient's death.

4. Conclusion

The clinical diagnosis of Bart's syndrome or type VI ACC is simple. However, in

our context of a country with limited resources, it poses a problem of management and surveillance. This management must be rigorous with the control of the infectious and hemorrhagic risk. To do so, it requires parental adherence to the treatment, excellent therapeutic compliance and rigorous monitoring.

Ethical Consideration

The patient's father has given his consent for the writing and publication of the study.

Author's Contribution

All authors have participated, read and approved the final version of the manuscript.

Conflicts of Interest

The authors declare no conflicts of interest regarding the publication of this paper.

References

- [1] Alfayez, Y., Alsharif, S. and Santli, A. (2017) A Case of Aplasia Cutis Congenita Type VI: Bart Syndrome. *Case Reports in Dermatology*, **9**, 112-118. <https://doi.org/10.1159/000478889>
- [2] Frieden, I.J. (1986) Aplasia Cutis Congenita: A Clinical Review and Proposal for Classification. *Journal of the American Academy of Dermatology*, **14**, 646-660. [https://doi.org/10.1016/S0190-9622\(86\)70082-0](https://doi.org/10.1016/S0190-9622(86)70082-0)
- [3] Rogvi, R., Sommerlund, M. and Vestergaard, E.T. (2014) Aplasia Cutis Congenita Is a Rare and Possibly Overlooked Congenital Anomaly. *Ugeskrift for Laeger*, **176**, V05140276.
- [4] Taïb, A. and Boralevi, F. (2004) Dermatoses néonatales in dermatologie et infections sexuellement transmissibles. *Edit Masson Paris*, **4**, 899-907.
- [5] Garcia-Romero, M.T., Narvóez-Rosales, V. and Hojyo-Tomoka, M.T. (2011) Bullous Aplasia Cutis Congenita: Case Report and Review of the Literature. *Indian Journal of Dermatology*, **56**, 337-338. <https://doi.org/10.4103/0019-5154.82503>
- [6] Ahogo, K.C., Kouassi, K.A., Cissé, L., Kaloga, M., Gbéry, I.P., Kourouma, H.S., Kouassi, Y.I. and Allou, A.S. (2017) Aplasia Cutis Congenita and Congenital Epidermolysis Bullosa (Bart Syndrome): An Unusual Association on Black Skin. *Revue Internationale des Sciences Médicales*, **1**, 78-80.
- [7] Bart, B.J., Gorlin, R.J., Anderson, V.E. and Lynch, F.W. (1966) Congenital Localized Absence of Skin and Associated Abnormalities Resembling Epidermolysis Bullosa. A New Syndrome. *Archives of Dermatology*, **93**, 296-304. <https://doi.org/10.1001/archderm.1966.01600210032005>
- [8] Mashuda, F., Zuechner, A., Chalya, P.L., Kidenya, B.R. and Manyama, M. (2014) Pattern and Factors Associated with Congenital Anomalies among Young Infants Admitted at Bugando Medical Centre, Mwanza, Tanzania. *BMC Research Notes*, **7**, Article No. 195. <https://doi.org/10.1186/1756-0500-7-195>
- [9] Rajpal, A., Mishra, R., Hajirnis, K., Shah, M. and Nagpur, N. (2008) Bart's Syndrome. *Indian Journal of Dermatology*, **53**, 88-90.

- <https://doi.org/10.4103/0019-5154.41655>
- [10] Casanova, J.M., Martí, R.M., Baradad, M., Egido, R. and Mascaró, J.M. (2006) Bart Syndrome Associated to Lethal Junctional Epidermolysis Bullosa (Herlitz Form) (In Spanish). *Actas Dermo-Sifiliográficas*, **97**, 658-661.
[https://doi.org/10.1016/S0001-7310\(06\)73489-5](https://doi.org/10.1016/S0001-7310(06)73489-5)
- [11] Browning, J.C. (2013) Aplasia Cutis Congenita: Approach to Evaluation and Management. *Dermatologic Therapy*, **26**, 439-444.
<https://doi.org/10.1111/dth.12106>
- [12] Salavastru, C.M., Sprecher, E., Panduru, M., *et al.* (2013) Recommended Strategies for Epidermolysis Bullosa Management in Romania. *Maedica (Buchar)*, **8**, 200-205.
- [13] Elluru, R.G., Contreras, J.M. and Albert, D.M. (2013) Management of Manifestations of Epidermolysis Bullosa. *Current Opinion in Otolaryngology & Head and Neck Surgery*, **21**, 588-593.
<https://doi.org/10.1097/MOO.0000000000000004>
- [14] Abulezz, T.A. and Shalkamy, M.A. (2009) Aplasia Cutis Congenita: Two Cases of Non-Scalp Lesions. *Indian Journal of Plastic Surgery*, **42**, 261-264.
<https://doi.org/10.1055/s-0039-1699359>
- [15] Kulalı, F., Bas, A.Y., Kale, Y., Celik, I.H., Demirel, N. and Apaydın, S. (2015) Type VI Aplasia Cutis Congenita: Bart's Syndrome. *Case Reports in Dermatological Medicine*, **2015**, Article ID: 549825. <https://doi.org/10.1155/2015/549825>