

Heart Failure in Children in a Context of Sars-Cov 2 Infection: About Two Cases at the University Hospital Center of Libreville, Gabon

Ayo Bivigou Elsa^{1,2*}, Mpori Jamila³, Mba Aki Tatiana⁴,
Ondo Mba Léo⁵, Békalé Joachim⁵, Kouna Philomene²

¹Cardiology Department, University Hospital of Libreville, Libreville, Gabon

²Department of Internal Medicine and Medical Specialties, Medical School, University of Health Sciences, Libreville, Gabon

³Cardiology Unit, Jeanne Ebori Mother and Child Foundation University Hospital Center, Libreville, Gabon

⁴Department of Ophthalmology, University Hospital of Owendo, Libreville, Gabon

⁵Intensive Care Unit, Jeanne Ebori Mother and Child Foundation University Hospital Center, Libreville, Gabon

Email: *bivayo@yahoo.fr

How to cite this paper: Elsa, A.B., Jamila, M., Tatiana, M.A., Léo, O.M., Joachim, B. and Philomene, K. (2022) Heart Failure in Children in a Context of Sars-Cov 2 Infection: About Two Cases at the University Hospital Center of Libreville, Gabon. *Open Journal of Pediatrics*, 12, 274-282.

<https://doi.org/10.4236/ojped.2022.121030>

Received: February 8, 2022

Accepted: March 28, 2022

Published: March 31, 2022

Copyright © 2022 by author(s) and Scientific Research Publishing Inc.

This work is licensed under the Creative Commons Attribution International License (CC BY 4.0).

<http://creativecommons.org/licenses/by/4.0/>



Open Access

Abstract

This study reports two observations of heart failure diagnosed in the context of SARS-CoV 2 infection in children at the University Hospital Center of Libreville, Gabon. Long considered exempted from serious forms of Covid-19 infection, the fatal evolution of one of the two cases proves that there is an interest for a more rigorous approach in their management in a pandemic context. The multisystem inflammatory syndrome associated with this virus in children can be responsible for cardiac manifestations that can be life-threatening. Early diagnosis and treatment are necessary to reduce mortality. However, this approach is made difficult in our regions by the limited biomedical equipment and the absence of essential therapies as noted in these two observations.

Keywords

Heart Failure, Children, Sars-Cov 2 Infection

1. Introduction

Since the first case declared in Gabon on March 12, 2020, infection with SARS-Cov-2 constitutes, with regard to the rest of the world, a major public health challenge [1] [2] [3]. After the respiratory distress widely reported at the start of the pandemic, numerous extrapulmonary manifestations, including cardiovascular manifestations, have been described [2] [3]. The latter initially concerned

elderly patients, with high cardiovascular risk and/or presenting co-morbidities [4]. An exaggerated autoimmune response characterized by a cytokine storm and thrombotic phenomena was the mechanism incriminated in these particular forms [4]. Subsequently, numerous publications have reported cardiovascular manifestations, in particular myocarditis, which can occur in children during Covid-19 [5] [6] [7] [8] [9]. These are related to a multisystem inflammatory syndrome associated with infection (MIS-C) and can be life-threatening [6] [7] [8] [9]. Multi organ involvement, mucocutaneous involvement, cardiovascular symptoms and gastrointestinal symptoms were the main features with fever [7]. However, the diagnosis of these serious forms of SARS-CoV-2 infection remains complex. In Gabon, according to data from the World Health Organization, 47,506 have been confirmed as of February 2022 with 303 (0.64%) deaths [10]. No data have been published on heart damage, especially in children, during Covid-19. This work reports two observations of heart failure occurring in children.

2. Patient 1

This was a 10-year-old patient, whose only history is obesity defined by a Z-score greater than 3 standard deviations according to the criteria of the International Obesity Task Force (IOTF), admitted on October 13, 2021 in intensive care at the Jeanne Ebori Mother and Child Foundation University Hospital Center in Libreville in an array of cardiogenic shock. The anamnesis reported a fatty febrile cough associated with vomiting evolving for five days. The clinical examination found a picture of global heart failure (HF) with New York Heart Association (NYHA) stage IV dyspnea and systolic blood pressure of 70 mmHg. Fine crackles were noted at two-thirds of the lung bases. The pulsed oxygen saturation (SpO₂) was 92% in ambient air and the temperature at 39.0. The biological assessment reported hyperleukocytosis at 31,000/mm³ with neutrophil predominance (84%), a slight lymphopenia at 4290/mm³, thrombocytopenia at 94,000/mm³, C-reactive protein at 52 mg/dl and pro-calcitonin at 16.9 ng/ml. There was also impaired renal function (creatinine clearance at 39 ml/min), hepatic cytolysis (SGOT 12,441 IU/l, SGPT 601 UI/l) and prothrombin time (PT) at 17%. The electrocardiogram (ECG) showed sinus tachycardia (heart rate 130/min) associated with anteroseptal ST segment elevation (**Figure 1**). Echocardiography-Doppler objectified a dilated cardiomyopathy with an end-diastolic diameter of the left ventricle (LV) measured at 64 mm (Normal for the size 38 - 48 mm) in long axis parasternal section, global hypokinesia and a left ventricular ejection fraction (LVEF) measured at 23% in Simpson (four cavities). The right cavities were of normal size, without pulmonary hypertension and the systolic excursion of the plane of the tricuspid annulus was normal (22 mm). The patient was put on vasopressor amine combined with diuretics and curative anticoagulation with enoxaparin. In this infectious context in a child, the diagnosis of acute myocarditis had been evoked. Antibiotic therapy with cefixime at a dose of 8 mg/kg/d had been associated in the hypothesis of an associated bronchopul-

monary superinfection. In the context of the SARSCoV-2 pandemic, two nasopharyngeal PCR (Polymerase Chain Reaction) tests were performed and were negative. The evolution was favorable after five days with improvement of the hemodynamic state and reduction of the congestive signs allowing the weaning of the vasopressor amines and the transfer in cardiology to the University Hospital Center of Libreville (CHUL). NTproBNP and troponin levels, obtained late 10 days from the onset of symptoms, were 390 pg/ml (N < 157 pg/ml) and 6.3 pg/ml (N < 5 pg/ml), respectively. The D-dimers were at 2232 ng/ml. The follow-up ECG showed normalization of the ST segment (Figure 2). Echocardiography performed seven days after hospitalization showed persistence of left ventricular dilation and severe alteration of LVEF with appearance of a left intraventricular mural thrombus located at the apex (Figure 3), this despite anticoagulation at a curative dose. The search for an associated underlying thrombotic pathology had motivated the performance of a thoracic computed tomography (CT) which revealed bilateral and diffuse ground glass overdensity pulmonary lesions associated with nodular hyperdensities under the lateral and basal pleural evoking a Sarscov-2 viral pneumonitis evaluated at 25% lung parenchyma involvement. The patient was discharged after 15 days under diuretic treatment (furosemide and antialdosterone), inhibitor of the angiotensin, digoxin 0.25mg 1/2 tab/day and anticoagulation with acenocoumarol. The patient

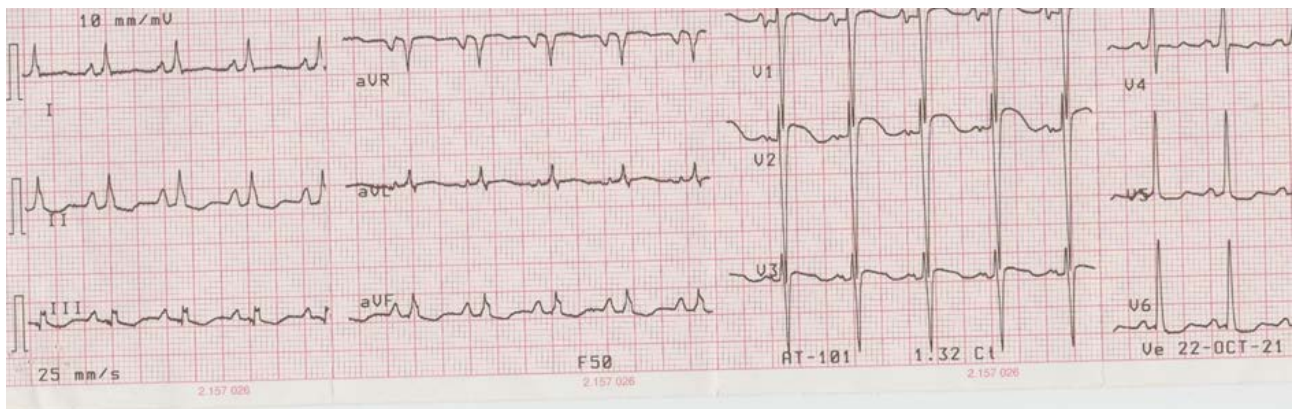


Figure 1. Antero-septal ST segment elevation in a 10-year-old female patient with heart failure.

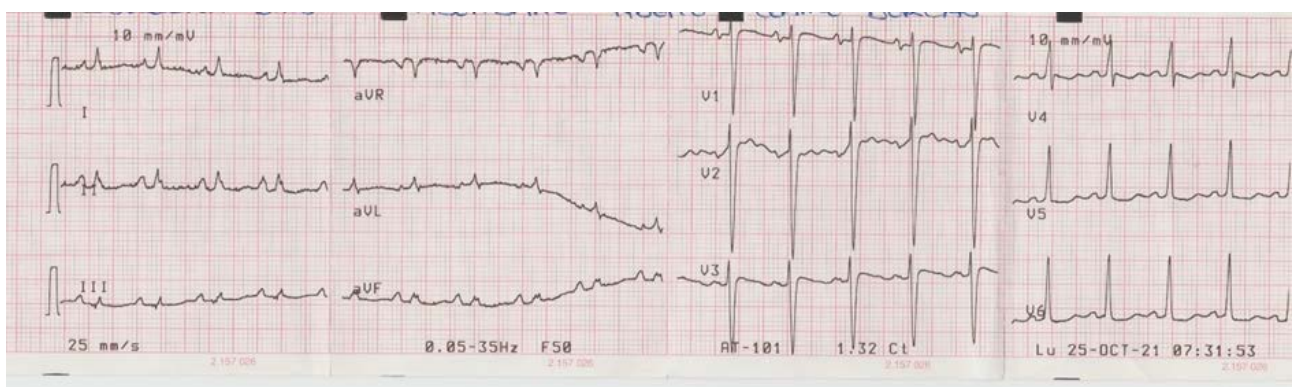


Figure 2. Normalization of the ST segment in the antero-septal in a 10-year-old patient with heart failure.

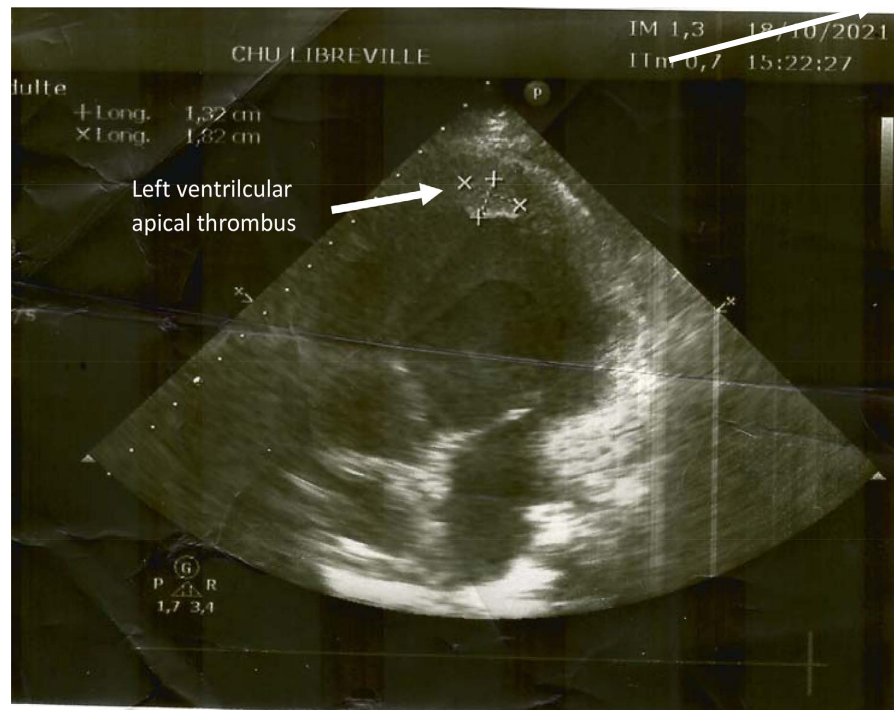


Figure 3. Left intraventricular thrombus complicating SARS CoV 2 myocarditis in a 10-year-old patient, Trans-thoracic echocardiography, apical view 4 chambers (Photo library, cardiology department-CHUL).

died 15 days later in a context of sudden death, probably due to rhythm disorder.

3. Patient 2

It was a 16-year-old patient, with no particular history, admitted in a private health facility in Libreville on October 12, 2021 for an influenza-like illness withodynophagia, a fever of 40° and significant asthenia which had been evolving for 10 days. The interrogation reported diffuse abdominal pain without transit disorders and a skin rash that lasted 72 hours and regressed spontaneously before hospitalization. Clinical examination revealed submaxillary lymphadenopathy and tonsillitis. A diagnosis of bacterial angina was concluded and treatment with ceftriaxone at a dose of 100 mg/kg was initiated. Faced with the persistence of fever after 6 days of hospitalization, the onset of rapidly progressive dyspnea and OMI, the patient was referred to the CHUL cardiology ward. The examination revealed a syndrome of global heart failure with NYHA stage IV dyspnea. SpO2 was 96% on room air. There was also bilateral conjunctivitis. The electrocardiogram showed a sinus rhythm with an HR of 90/minute and a right bundle branch block (**Figure 4**). Doppler echocardiography performed on admission showed a slightly dilated LV (55 mm) associated with septoapical and anterior hypokinesia and an estimated LVEF of 25% - 30% in Simpson four chambers. The mitral profile was restrictive. The RV was of normal size and function. The diagnosis of myocarditis evolving in a viral context had been concluded given the extra-cardiac manifestations and the patient's age. Biologically, there was a

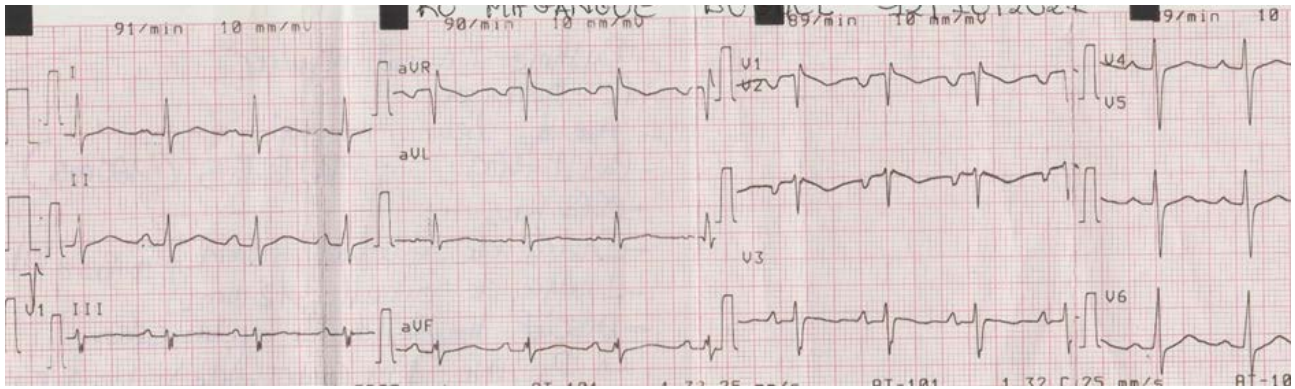


Figure 4. Right bundle branch block in a 16-year-old patient with heart failure in the context of SARS CoV 2 infection.

significant inflammatory syndrome with thrombocytosis at 843,000 platelets per mm^3 , an ESR at 40 mm in the first hour, a CRP at 56 mg/dl and D-dimers at 1956 ng/ml. The NT-proBNP level was 491 pg/ml ($N < 157$ pg/ml) and the troponinemia was 15.6 pg/ml ($N < 5$ pg/ml). Hyperleukocytosis at 22,060/ mm^3 with neutrophil predominance (87%), lymphopenia at 1764/ mm^3 and hepatic cytolysis (SGOT 232 IU/l, SGPT 118 IU/l) were also noted. The TP was 68%. HIV, hepatitis A, B and C serologies were negative. Antistreptolysin O antibodies were negative, as was typhoid serology. The nasopharyngeal PCR to SARS-CoV 2 carried out 17 days from the onset of symptoms was negative. Thoraco-abdomino-pelvic CT showed homogeneous hepatomegaly (hepatic arrow at 161 mm) with no deep suppuration in the abdomen or infectious focus in the lungs. A Covid-19 serology had been carried out with demonstration of a high level of Ig M antibodies (13.5) indicating a recent infection. The diagnosis of SARS-CoV 2 myocarditis was suggested. The evolution under classic treatment of HF associated with a double antibiotic therapy with cefixime for 10 days and azithromycin for 5 days as recommended in the National Guidelines was favorable with regression of congestive signs, normalization of the biological assessment in particular of troponin, regression conductive disorder on the ECG (**Figure 5**) and improvement in LVEF (50%) after 10 days of treatment (**Figure 6**) [11]. Septal hypokinesia persists at 3 months follow-up with an asymptomatic patient on an ACE inhibitor.

4. Discussion

These two clinical cases are the first cases of HF described in children in the context of recent SARS-CoV 2 infection in Libreville and gave forth to the following comments:

In industrialized countries, endomyocardial biopsy and cardiac magnetic resonance imaging (MRI) can be used to diagnose myocarditis [12]. In the absence of these key examinations at the CHUL and in many other SSA countries, the use of the diagnostic criteria of the European Society of Cardiology (ESC) is very important [12]. Myocarditis is clinically suspected in the presence of at least one suggestive clinical presentation and at least one diagnostic criterion, and the

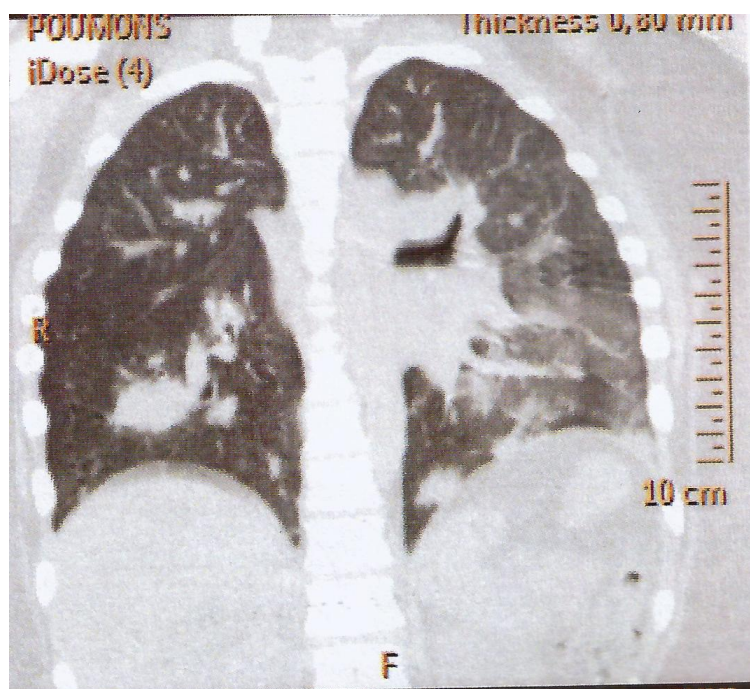


Figure 5. Chest computed tomography lesions suggestive of SARS-CoV 2 infection in a 10-year-old patient (Photo library, cardiology department-CHUL).

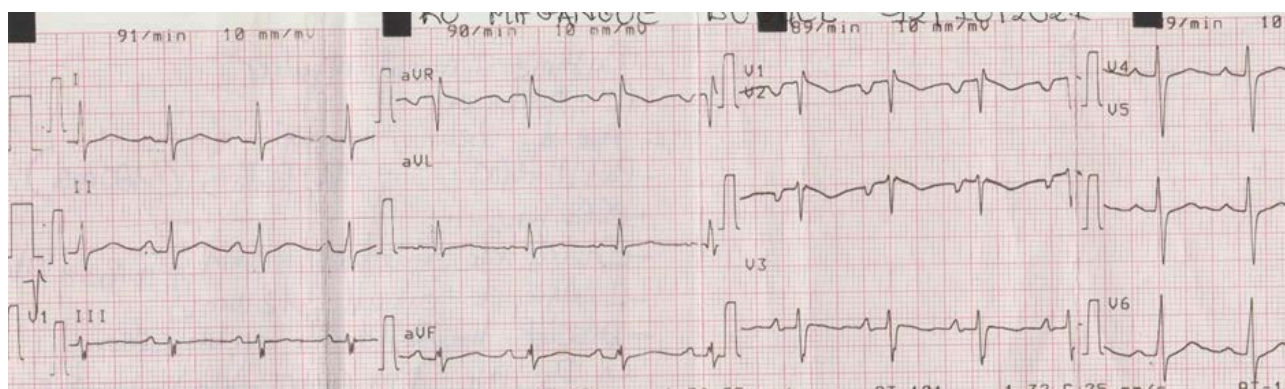


Figure 6. Regression of the conductive disorder in this same patient.

suspicion is all the stronger the more criteria are present. Our two patients had a clinical aspect implying myocarditis (cardiogenic shock in patient 1 and acute heart failure in patient 2) and three diagnostic criteria (ST elevation in patient 1, right bundle branch block in patient 2, elevation of troponinemia and echocardiographic abnormalities in both). The hypothesis of a pre-existing decompensated dilated cardiomyopathy in the case of a Covid-19 had not however been excluded in spite the importance of cavitory dilation.

If the formal diagnosis of the viral etiology of myocarditis is based on histological evidence associated with a positive PCR, it can be suspected in the event of a recent history of viral infection in subjects under 35 years of age and in the no cardiovascular risk factor as noted in our two patients [11]. The SARS-CoV 2 etiology was retained in both cases despite a negative PCR. Indeed, although it is

the reference diagnostic test for Covid-19, it is frequently negative as reported in 54% of cases in a meta-analysis of 12,057 patients suspected of SARS CoV 2 infection [13]. Low positive PCR rates are also reported by Jain *et al.* and Dhanalakshmi *et al.* with respectively 39.1% and 15% in case series of SARS CoV-2 myocarditis in children [6] [7]. In this context, repeat testing and the use of other infection diagnostic techniques are recommended [14]. Repeating the tests is difficult to apply at the CHUL and in other SSA countries such as Benin and justifies the performance of a single PCR in our two patients [13] [15]. With a chest CT sensitivity of 91.6% demonstrated by Bôger *et al.*, the typical lesions objectified in patient 1 allowed us to retain the diagnosis of Covid-19 [14]. In patient 2, chest CT was normal. Indeed, myocardial damage can occur during Covid-19 in the absence of lung damage as reported in a patient by Cuomo *et al.* [16]. The serological test was used to confirm the diagnosis in patient 2 because of its demonstrated specificity of 91.6% [14]. Also, high levels of Ig M and Ig G are frequently reported in other studies on SARS CoV 2 myocarditis in children [7].

In adults, myocarditis during Covid-19 is classically associated with severe forms with severe pulmonary involvement and in patients admitted to an ICU [4]. In children, it is secondary to the multisystem inflammatory syndrome associated with Covid-19 (MIS-C). According to the WHO, this syndrome occurring in children and adolescents aged 0 to 19 years is characterized by the presence of persistent fever (≥ 3 days) associated with at least two signs of cutaneous-mucous, cardiovascular, coagulopathy, digestive disorders in a significant inflammatory context (raised CRP and procalcitonin) without any other obvious bacterial cause and in the presence of elements revealing Covid-19 (PCR, antigenic test or positive serology) or probable contact with affected patients [17]. The fever was raised in our two patients. Patient 1 presented 4 signs including significant coagulation disorders with a PT of 17% and very high D-dimers. This prothrombogenic context could have participated in the formation of the left intraventricular thrombus objectified in this young patient. Patient 2 had 6 signs including gastrointestinal disorders and mucocutaneous lesions. The latter are reported in respectively 52% and 45% of children with MIS-C in a cohort of 58 adolescents in the United States [9]. The presence of pharyngitis associated with submaxillary lymphadenopathy may have misled the initial diagnosis. Lymphadenopathy is described in 16% to 31.5% of MIS-C cases and up to 62.5% of cases in patients with a negative RT-PCR [7] [9]. Similarly, the elevation of procalcitonin reported in patient 1 and the hyperleukocytosis noted in the two patients could erroneously point to a bacterial origin. Elevated procalcitonin is reported in 35% - 92% of MIS-C cases [18]. However, its dosage is not available at the CHUL. The absence of blood culture is the main limitation to exclude with certainty the bacterial origin in these two children. MIS-C being unknown by the practitioners who treated these two patients explains the non-use of corticosteroids.

5. Conclusion

These two clinical cases of heart failure occurring in the context of SARS-CoV2 infection in children demonstrate the diagnostic difficulties of myocarditis in our regions in the absence of cardiac MRI. The fatal evolution of one of the two cases testifies to the sometimes pejorative prognosis of Covid-19 in the latter. MIS-C, a new entity described since the beginning of this pandemic and at the origin of this myocarditis, deserves to be known to pediatricians and cardiologists. The importance of suspecting it in febrile adolescents during this pandemic must be emphasized. In the absence of intravenous immunoglobulins in Gabon, the administration of corticosteroids could improve the prognosis.

Ethical Considerations

The parents of the two children completed and signed a consent form for publication.

Conflicts of Interest

The authors declare no conflicts of interest regarding the publication of this paper.

References

- [1] <https://covid19.who.int/region/afro/country/ga>
- [2] Mbow, M., Lell, B., Jochems, S.P., Cisse, B., Mboup, S., Dewals, B.G., Jaye, A., Dieye, A. and Yazdanbakhsh, M. (2020) COVID-19 in Africa: Dampening the Storm? *Science*, **369**, 624-626. <https://doi.org/10.1126/science.abd3902>
- [3] Salzberger, B., Buder, F., Lampl, B., Ehrenstein, B., Hitzenbichler, F., Holzmann, T., Schmidt, B. and Hanses, F. (2021) Epidemiology of SARS-CoV-2. *Infection*, **49**, 233-239. <https://doi.org/10.1007/s15010-020-01531-3>
- [4] He, X.W., Lai, J.S., Cheng, J., Wang, M.W., Liu, Y.J., Xiao, Z.C., Xu, C., Li, S.S. and Zeng, H.S. (2020) Impact of Complicated Myocardial Injury on the Clinical Outcome of Severe or Critically Ill COVID-19 Patients. *Chinese Journal of Cardiology*, **48**, 456-460.
- [5] Pousa, P.A., Mendonça, T.S.C., Oliveira, E.A. and Simões-E-Silva, A.C. (2021) Extrapulmonary Manifestations of COVID-19 in Children: A Comprehensive Review and Pathophysiological Considerations. *The Journal of Pediatrics*, **97**, 116-139. <https://doi.org/10.1016/j.jpeds.2020.08.007>
- [6] Jain, S., Sen, S., Lakshmivenkateshiah, S., Bobhate, P., Venkatesh, S., Udani, S., Shobhavat, L. andankar, P., Karande, T. and Kulkarni, S. (2020) Multisystem Inflammatory Syndrome in Children with COVID-19 in Mumbai, India. *Indian Pediatrics*, **57**, 1015-1019. <https://doi.org/10.1007/s13312-020-2026-0>
- [7] Dhanalakshmi, K., Venkataraman, A., Balasubramanian, S., Madhusudan, M., Amperayani, S., Putlibai, S., Sadasivam, K., Ramachandran, B. and Ramanan, A.V. (2020) Epidemiological and Clinical Profile of Pediatric Inflammatory Multisystem Syndrome—Temporally Associated with SARS-CoV-2 (PIMS-TS) in Indian Children. *Indian Pediatrics*, **57**, 1010-1014. <https://doi.org/10.1007/s13312-020-2025-1>
- [8] Bhat, C.S., Gupta, L., Balasubramanian, S., Singh, S. and Ramanan, A.V. (2020) Hy-

- perinflammatory Syndrome in Children Associated with COVID-19: Need for Awareness. *Indian Pediatrics*, **57**, 929-935. <https://doi.org/10.1007/s13312-020-1997-1>
- [9] Whittaker, E., Bamford, A., Kenny, J., Kaforou, M., Jones, C.E., Shah, P., Ramnarayan, P., Fraisse, A., Miller, O., Davies, P., Kucera, F., Brierley, J., McDougall, M., Carter, M., Tremoulet, A., Shimizu, C., Herberg, J., Burns, J.C., Lyall, H., Levin, M., PIMS-TS Study Group and EUCLIDS and PERFORM Consortia (2020) Clinical Characteristics of 58 Children with a Pediatric Inflammatory Multisystem Syndrome Temporally Associated with SARS-CoV-2. *JAMA*, **324**, 259-269. <https://doi.org/10.1001/jama.2020.10369>
- [10] World Health Organization (2022). <https://covid19.who.int/region/afro/country/ga>
- [11] National Guidelines for the Medical Management of Coronavirus Disease 2019 (Covid-19), Covid-19 Scientific Committee, April 2020.
- [12] Caforio, A.L., Pankuweit, S., Arbustini, E., Basso, C., Gimeno-Blanes, J., Felix, S.B., Fu, M., Heliö, T., Heymans, S., Jahns, R., Klingel, K., Linhart, A., Maisch, B., McKenna, W., Mogensen, J., Pinto, Y.M., Ristic, A., Schultheiss, H.P., Seegewiss, H., Tavazzi, L., Thiene, G., Yilmaz, A., Charron, P., Elliott, P.M. and European Society of Cardiology Working Group on Myocardial and Pericardial Diseases (2013) Current State of Knowledge on Aetiology, Diagnosis, Management, and Therapy of Myocarditis: A Position Statement of the European Society of Cardiology Working Group on Myocardial and Pericardial Diseases. *European Heart Journal*, **34**, 2636-2648. <https://doi.org/10.1093/eurheartj/ehz210>
- [13] Arevalo-Rodriguez, I., Buitrago-Garcia, D., Simancas-Racines, D., Zambrano-Achig, P., Del Campo, R., Ciapponi, A., Sued, O., Martinez-García, L., Rutjes, A.W., Low, N., Bossuyt, P.M., Perez-Molina, J.A. and Zamora, J. (2020) False-Negative Results of Initial RT-PCR Assays for COVID-19: A Systematic Review. *PLoS ONE*, **15**, e0242958. <https://doi.org/10.1371/journal.pone.0242958>
- [14] Böger, B., Fachi, M.M., Vilhena, R.O., Cobre, A.F., Tonin, F.S. and Pontarolo, R. (2021) Systematic Review with Meta-Analysis of the Accuracy of Diagnostic Tests for COVID-19. *American Journal of Infection Control*, **49**, 21-29. <https://doi.org/10.1016/j.ajic.2020.07.011>
- [15] Murielle, H., Philippe, A., Arnaud, S., *et al.* (2020) Diagnosis of Acute Myocarditis during Covid-19 in a Country with a Limited Technical Platform: Reflection around a Case. *Journal of the Society of Clinical Biology of Benin*, No. 35, 99-104.
- [16] Cuomo, G., Menozzi, M., Carli, F., Digaetano, M., Raimondi, A., Reggianini, L., Li-gabue, G., Guaraldi, G. and Mussini, C. (2020) Acute Myocarditis as the Main Clinical Manifestation of SARS-CoV2 Infection. *Infectious Disease Reports*, **12**, 8609. <https://doi.org/10.4081/idr.2020.8609>
- [17] World Health Organization (2020) Multisystem Inflammatory Syndrome in Children and Adolescents with COVID 19 Scientific Brief. <https://www.who.int/publicationsdetail/multisystem-inflammatory-syndrome-in-children-and-adolescents-with-covid-19>
- [18] Kohn-Loncarica, G., Fustiñana, A., Díaz-Rubio, F., Jaramillo-Bustamante, J.C., González-Dambrasuskas, S., Vásquez-Hoyos, P., Fernández-Sarmiento, J., González, G., Mansur, A., Ponce, J. and Jabornisky, R. (2020) Recommendations for the Initial Management of Multisystem Inflammatory Syndrome Temporally Related to COVID-19 in Children and Adolescents. *Archivos Argentinos de Pediatría*, **118**, e514-e526. <https://doi.org/10.5546/aap.2020.eng.e514>