

# A Rare Cause of Leukocoria in Children: Persistent Hyperplastic Primary Vitreous

Prudence Ada Assoumou<sup>1\*</sup>, Davy Alex Mouinga Abayi<sup>2</sup>, Yoan Mboussou<sup>3</sup>,  
Annick Kougou Ntoutoume<sup>4</sup>, Helene Nyinko Aboughe<sup>4</sup>, Olive Matsanga<sup>4</sup>,  
Tatiana Harly Mba Aki<sup>4</sup>, Emmanuel Mve Mengome<sup>2</sup>

<sup>1</sup>Owendo University Hospital Center, Department of Surgery at the Faculty of Medicine of the University of Health Sciences, Libreville, Gabon

<sup>2</sup>Omar Bongo Ondimba Military Instructions Hospital, Department of Surgery at the Faculty of Medicine of the University of Health Sciences, Libreville, Gabon

<sup>3</sup>Médivision Clinic, Libreville, Gabon

<sup>4</sup>Jeanne Ebori Foundation Mother and Child University Hospital Center, Department of Surgery at the Faculty of Medicine of the University of Health Sciences, Libreville, Gabon

Email: \*prudence\_apa@yahoo.fr

**How to cite this paper:** Assoumou, P.A., Mouinga Abayi, D.A., Mboussou, Y., Kougou Ntoutoume, A., Nyinko Aboughe, H., Matsanga, O., Mba Aki, T.H. and Mve Mengome, E. (2024) A Rare Cause of Leukocoria in Children: Persistent Hyperplastic Primary Vitreous. *Open Journal of Ophthalmology*, 14, 63-68.

<https://doi.org/10.4236/ojoph.2024.141006>

**Received:** August 17, 2023

**Accepted:** February 24, 2024

**Published:** February 27, 2024

Copyright © 2024 by author(s) and Scientific Research Publishing Inc.

This work is licensed under the Creative Commons Attribution International License (CC BY 4.0).

<http://creativecommons.org/licenses/by/4.0/>



Open Access

## Abstract

**Introduction:** Leukocoria, a whitish pupillary reflection, is a common warning sign of various pediatric ocular pathologies, including Persistent hyperplastic primary vitreous (PHVP). This case report describes the observation of a 3-year-old child with melanoderma, presenting with a white spot in the left eye since birth. **Observation:** Uncorrected distance visual acuity was 2/10 in the right eye and hand movements were perceived at 2 meters in the left eye. Examination of the anterior segment in the left eye revealed leukocoria and microphthalmia. The fundus examination was normal in the right eye but revealed a white mass extending from the center of the optic disc towards the temporal region in the left eye. Ocular imaging, including ocular ultrasound and optical coherence tomography, confirmed the diagnosis of PHVP, illustrated by a residual white mass at the center of the optic disc in the left eye. **Conclusion:** PHVP should be considered in the presence of leukocoria in a child, with urgent exclusion of retinoblastoma. This observation underscores the importance of early diagnosis for appropriate management.

## Keywords

PHVP, Leukocoria, Amblyopia, Ocular Imaging, Childhood

## 1. Introduction

Leukocoria, characterized by a whitish pupillary reflection, holds crucial signi-

ificance as a major indicator of various severe pediatric ocular conditions, including PHVP [1]. While prior studies have emphasized the crucial role of leukocoria as an early sign of PHVP [2] [3] [4] [5], gaps persist in understanding the underlying mechanisms of this condition and optimizing resulting management strategies. In this context, this clinical case aims to make a significant contribution to the literature by exploring the clinical features of leukocoria, emphasizing its intrinsic connection to PHVP, and examining best management practices based on tangible outcomes. A comprehensive understanding of these aspects could pave the way for advances in early diagnosis and more effective management of PHVP, providing positive prospects for the long-term ocular health of affected children. Before delving into clinical details, it is essential to highlight that this report fully adheres to ethical principles. Formal consent has been obtained from the patient's family, and all identifiable information has been meticulously anonymized to preserve confidentiality. In the course of this work, we present the case of a 3-year-old melanodermic child who sought medical attention for a white spot in the left eye present since birth.

## 2. Observation

This concerns the case of a 3-year-old melanodermic girl, born full-term and seemingly healthy. The consultation was prompted by the presence of a white spot in the left eye, noticeable since birth. The initial examination revealed predominant leukocoria in the left eye, while visual acuity was 2/10 in the right eye and hand movements were perceived at 2 meters in the left eye. Normal anterior segment examination on the right highlighted leukocoria (Figure 1) and microphthalmia in the left eye. Intraocular pressure was normal in both eyes. Fundus examination (Volk) was normal in the right eye (Figure 2) but revealed a white mass extending from the center of the optic disc towards the temporal region in the left eye (Figure 3). Ocular ultrasound confirmed the presence of vitreous as a white mass and microphthalmia, with an axial length of approximately 21.7 mm (Figure 4). Faced with diagnostic uncertainties, color Doppler ultrasound (Figure 5) confirmed the diagnosis of PHVP by showing vascular flow around the retro-ocular mass. Magnetic Resonance Imaging (MRI) reinforced the diagnosis of posterior PHVP, revealing a hyperintense signal in the posterior segment in T1 and T2, related to fibrovascular residue and subretinal fluid (Figure 6). The clinical course of this case was marked by the development


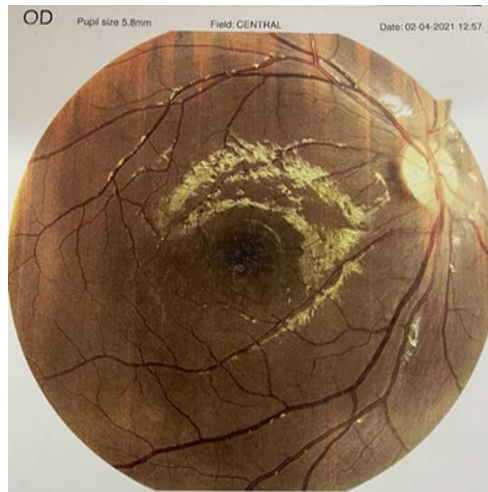
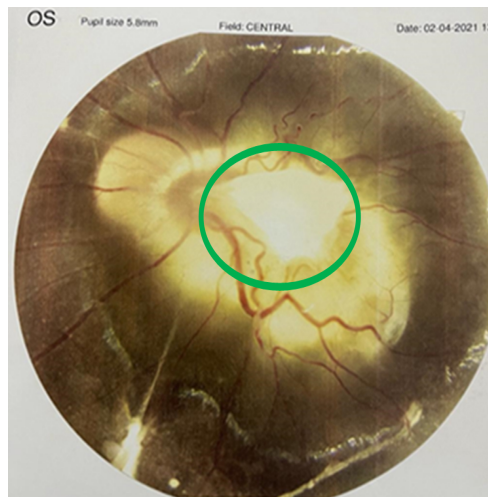


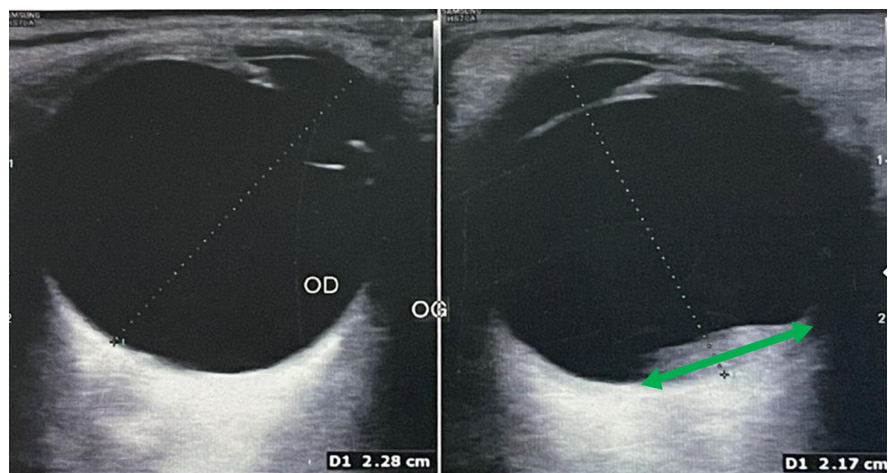
Figure 1. Leukocoria in the left eye.



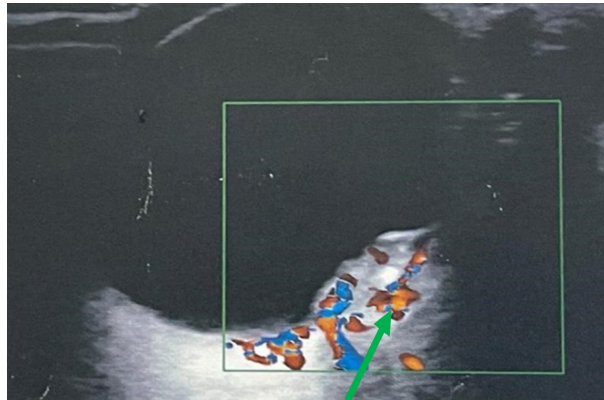
**Figure 2.** Normal right fundus.



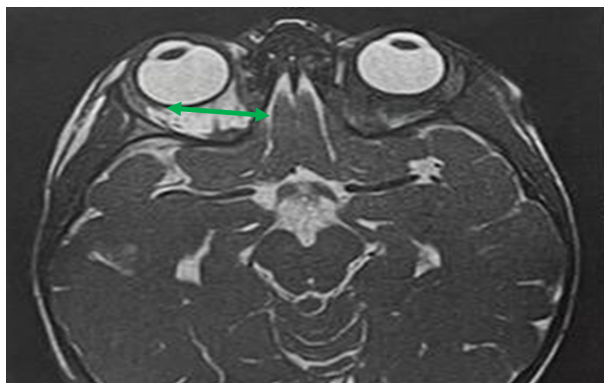
**Figure 3.** Residual embryonic vitreous in the optic disc of the left eye.



**Figure 4.** B-mode ocular ultrasound of the left eye shows vitreous as a mass and microphthalmia (AL = 21.7 mm).



**Figure 5.** Color Doppler ultrasound of the left eye shows vascular flow around the retro-ocular mass.



**Figure 6.** MRI of the left eye reveals a hyperintense signal in the posterior segment on T1 and T2.

of profound amblyopia in the left eye, without anatomical complications. Management involved prescribing full optical correction after cycloplegic refraction and functional rehabilitation with an orthoptist to address amblyopia, without surgical indication. Despite the poor prognosis for the left eye, hope persists for the right eye. This observation underscores the complexity of managing PHVP, emphasizing the need for a multidisciplinary approach to optimize functional outcomes in these young patients.

### 3. Comments

The early detection of PHVP is of crucial importance, requiring a congenital diagnosis shortly after birth, even within the first few days of life. This urgent approach aims to rule out retinoblastoma, a formidable pediatric cancer, thus ensuring a better quality of life for the child. However, PHVP often presents in seemingly healthy children without associated anomalies, complicating the diagnostic process [5]. The initial complexity of diagnosing PHVP underscores the need for a comprehensive diagnostic approach.

The combined use of ultrasound, color Doppler ultrasound, and MRI has been essential in confirming the nature of the retro-ocular mass, highlighting the

diversity of tools required in these complex situations. Nevertheless, it should be noted that these examinations face challenges when performed in children due to their young age, small eye size, and potential for cooperation refusal.

According to the literature, PHVP manifests through various clinical expressions, notably distributed into anterior (25%), posterior (12%), and mixed (70%) forms [6]. However, the diagnostic challenge of PHVP is particularly evident in its anterior form, where the predominance of leukocoria can mislead, pointing towards congenital ocular pathologies such as retinoblastoma, congenital cataract, congenital glaucoma, retinopathy of prematurity, and Coats' disease [5]. The diverse clinical manifestations, ranging from leukocoria to microphthalmia and the retro-ocular mass, underscore the variability in PHVP presentations. This diversity emphasizes the crucial importance of a thorough clinical evaluation to fully grasp the extent of the condition and guide management.

The decision to favor a conservative approach, excluding surgical intervention, confirmed by prescribing full optical correction and functional rehabilitation with an orthoptist, highlights the importance of personalized management. This approach aims to mitigate functional consequences while limiting the risks associated with more invasive procedures.

The evolution of this condition sparks debates. Some authors inevitably predict severe complications such as glaucoma, vitreous hemorrhages, retinal detachment, and inflammations, while others believe it may not progress [7] [8]. However, the potential risk of profound amblyopia in the left eye without anatomical complications underscores concerns related to the inherent challenges of PHVP, highlighting the importance of early intervention to mitigate long-term visual complications.

The prognosis of this malformation is generally bleak, influenced by various factors such as the age at diagnosis, the degree of visual axis involvement, diagnostic delay, initial lesion extent, and clinical form. The disparity in prognosis between the left and right eyes highlights the variability in outcomes in PHVP. This finding underscores the importance of ongoing evaluation to adjust management based on the condition's evolution while maintaining hope for positive visual prospects for the right eye.

The treatment of PHVP aims to mitigate induced amblyopia. Exclusively medical management involved full optical correction accompanied by functional rehabilitation under the supervision of an orthoptist. The simultaneous involvement of an ophthalmologist and an orthoptist, coupled with the use of different diagnostic modalities, highlights the essential need for a multidisciplinary approach. This collaboration ensures comprehensive and patient-specific care, emphasizing the crucial importance of the medical team in managing complex cases such as this one.

#### **4. Conclusion**

This clinical case underscores the complexity of PHVP, requiring a personalized



and multidisciplinary approach. Collaboration among various eye health specialists is essential for comprehensive care, aiming to optimize functional outcomes. By exploring such cases, we aim to enhance care and advance in the management of this rare pathology.

### Conflicts of Interest

The authors declare no conflicts of interest regarding the publication of this paper.

### References

- [1] Reese, A.B. and Payne, F. (1945) Persistence and Hyperplasia of the Primary Vitreous: Tunica Vasculosa Lentis or Retrolental Fibroplasia. *Transactions of the American Ophthalmological Society*, **43**, 163-192.
- [2] Roussat, B., Barbat, V., Cantaloube, C., Baz, P., Iba-Zizen, M.T. and Hamard, H. (1998) Syndrome de persistance et d'hyperplasie du vitré primaire. Aspects cliniques et thérapeutiques. *Journal Français d'Ophtalmologie*, **21**, 501-507.
- [3] Alexandrakis, G., Scott, I.U., Flynn Jr., H.W. Murray, T.G. and Feuer, W.J. (2000) Visual Acuity Outcomes with and without Surgery in Patients with Persistent Fetal Vaculature. *Ophthalmology*, **107**, 1068-1072. [https://doi.org/10.1016/S0161-6420\(00\)00100-7](https://doi.org/10.1016/S0161-6420(00)00100-7)
- [4] Roche, O., Keita Sylla, F., Beby, F., Orssaud, C. and Dufier, J.L. (2007) Persistance et hyperplasie du vitré primitif. *Journal Français d'Ophtalmologie*, **30**, 647-657. [https://doi.org/10.1016/S0181-5512\(07\)89674-4](https://doi.org/10.1016/S0181-5512(07)89674-4)
- [5] Ahmiti, I., Ahbeddou, S., El Khaoua, M., Tzili, N., Alami, F., Bencherifa, F. and Berraho, A. (2013) Persistance et hyperplasie du vitré primitif. *Maroc Médical*, **35**, 252-261.
- [6] Silbert, M. and Gurwood, A.S. (2000) Persistent Hyperplastic Primary Vitreous: Clinical Review. *Clinical Eye and Clinical Care*, **12**, 131-137. [https://doi.org/10.1016/S0953-4431\(00\)00054-0](https://doi.org/10.1016/S0953-4431(00)00054-0)
- [7] Haddad, R., Font, R.L. and Reeser, F. (1978) Persistent Hyperplastic Primary Vitreous. A Clinicopathologic Study of 62 Cases and Review of the Literature. *Survey of Ophthalmology*, **23**, 123-124. [https://doi.org/10.1016/0039-6257\(78\)90091-7](https://doi.org/10.1016/0039-6257(78)90091-7)
- [8] Cantaloube, A. (1989) Persistance et hyperplasie du vitré primitif. Difficultés diagnostiques et thérapeutiques, Thèse Médecine Paris.