

# Rhegmatogenous Retinal Detachment in One-Eyed Patients: Therapeutic and Prognostic Challenges

El Hadji Malick Sy\*, Aïssatou Aw, Aly Mbara Ka, Jean Pierre Diagne, Hawo Madina Diallo, Audrey Samra, Soda Mbaye, Papa Amadou Ndiaye

Ophthalmology Department of Abass NDAO Hospital, Cheikh Anta Diop University, Dakar, Senegal

Email: \*elhadjimalicksyonly@gmail.com, aichatou18@gmail.com, kaam75@hotmail.com, sebanemack@yahoo.fr, evadiallo2001@yahoo.fr, audrey.samra@gmail.com, soresm93@gmail.com, pagets001@gmail.com

**How to cite this paper:** Sy, E.H.M., Aw, A., Ka, A.M., Diagne, J.P., Diallo, H.M., Samra, A., Mbaye, S. and Ndiaye, P.A. (2023) Rhegmatogenous Retinal Detachment in One-Eyed Patients: Therapeutic and Prognostic Challenges. *Open Journal of Ophthalmology*, 13, 64-72.  
<https://doi.org/10.4236/ojoph.2023.131007>

**Received:** November 30, 2022

**Accepted:** February 7, 2023

**Published:** February 10, 2023

Copyright © 2023 by author(s) and Scientific Research Publishing Inc. This work is licensed under the Creative Commons Attribution International License (CC BY 4.0).

<http://creativecommons.org/licenses/by/4.0/>



Open Access

## Abstract

**Background:** Retinal detachment is a major ophthalmologic emergency. The rhegmatogenous form is the most common and its management is exclusively surgical as soon as possible. This urgency becomes major and absolute when it occurs in a particular monocular vision. **Purpose:** To analyze the clinical forms of rhegmatogenous retinal detachment (RRD), the results and the complications of their management in monophthalmic patients. **Methodology:** This was a retrospective and analytical study from June 2007 to December 2019. We included all patients who received a consultation for rhegmatogenous retinal detachment. All patients were seen by at least two posterior segment specialists and all were operated on by the same surgeon. **Results:** 57 files (57 eyes) were collected with an average age of 44.71 years and a sex ratio of 7.14. The average consultation time is 40.80 days. Patients complained of decreased visual acuity in 96.49% of cases. We had myopia in 49.12% of cases and 91.23% of patients were phakic. Retinal holes were found in 31.58% of our patients and giant tears in 17.54%. The mean retinal detachment extension was 2.52 quadrants and the macula was raised in 32 cases. The average time taken to take charge was 10 days. Detachment surgery was performed in 42 patients with 100% anatomical recovery. **Conclusion:** Retinal detachment in one-eyed patient is a major ophthalmic emergency. Its management must not suffer from any delay. Post-operative outcomes are relatively similar between the internal and external pathways. In one-eyed patient, silicone can be left alone in the absence of complications.

## Keywords

Rhegmatogenous Retinal Detachment, One-Eyed Patient, Intraocular Surgery,

## 1. Introduction

Rhegmatogenous retinal detachment (RRD) is a surgical emergency especially if the macular region is not affected by lifting. This is the most common form of RD [1]. Its occurrence in the one-eyed patients increases the urgency and poses a problem of functional prognosis due to apprehension of the occurrence of blindness.

The incidence of retinal detachment (RD) is estimated to be 1/10,000 per year in France and is one of the main causes of secondary blindness according to the WHO [1].

RRD diagnosis is relatively easy, but the real challenge is its management. This is an area of ophthalmic surgery that has increased significantly in recent years. To the rare and urgent adjectives, we would add that this is a subject that is very little documented in our countries. These various reasons motivated us to share our Senegalese experience on the issue.

However, the incidence of RRD in one-eyed patients is not well documented.

In this work, we analyze the clinical forms of RRD, the results and the complications of their management.

## 2. Method

This is a retrospective and analytical study from January 2007 to December 2019, conducted in our Ophthalmology department at the Abass Ndao Hospital in Dakar, which is a reference centre for retinal diseases.

We included all patients who presented with rhegmatogenous retinal detachment in a single eye during the study period. Excluded were patients without rhegmatogenous retinal detachment or non-transparent ocular medium. In our work, we have studied age, sex, causes of monocular vision, refraction, consultation time, visual acuity, dehiscence, macula and lens condition, vitreoretinal proliferation, surgical time, type of surgery, anatomical and functional recovery for each surgical approach as well as post-operative complications.

The history of all patients was accurately reported as was the cause of the loss of function of the contralateral eye.

All patients were examined by at least two differentiated posterior practitioners, who compared and validated their results.

The topography of the retinal detachment and the objectified dehiscence were recorded on an Amsler diagram.

All patients were operated on by the same surgeon by intraocular technique with more silicone oil (vitrectomy) or externally (episcleral indentation).

The surgical technique was chosen after studies of various parameters such as the type of detachment, the topography of the dehiscences, the presence of a

proliferative vitreoretinopathy (PVR) and the existence of previous surgery.

Post-operative monitoring assessed anatomical recovery, functional recovery, and whether or not there were complications. This data was collected on a form for each patient and the analysis was performed using SPSS and Excel.

### 3. Results

We collected 57 records of RRD in one-eyed patients (57 eyes) with a hospital frequency relative to the total number of RRDs received during the same study period of 18.56%.

The average age was 44.71 years with extremes between 10 and 85 years with a double peak between 40 - 50 years (21.05%) and 60 - 70 years (26.31%) (Figure 1).

The sex ratio was 7.14.

Functional loss of the contralateral eye was secondary to RD in 36.84% and trauma to the eyeball in 31.58% (Figure 2).

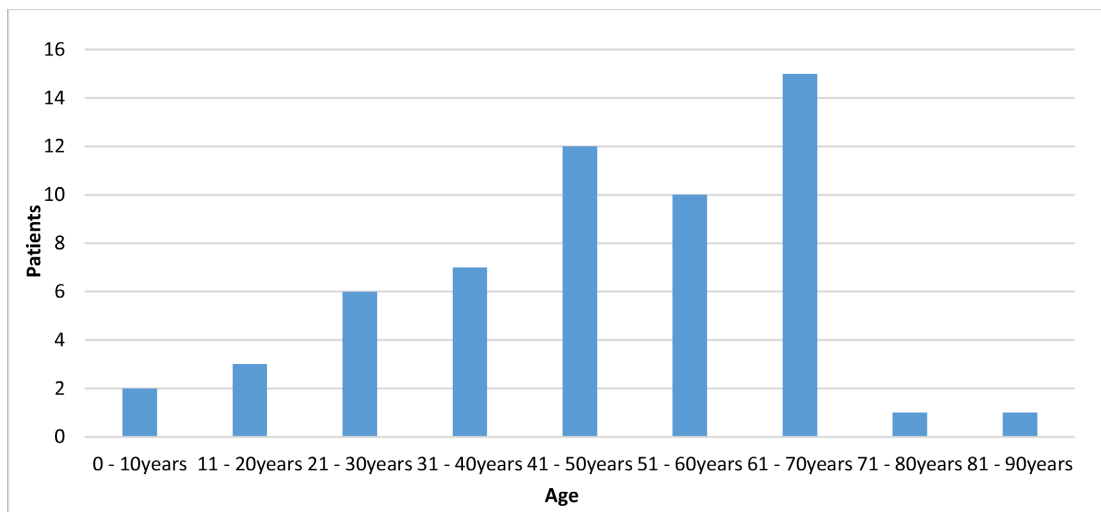


Figure 1. Distribution of patients by age.

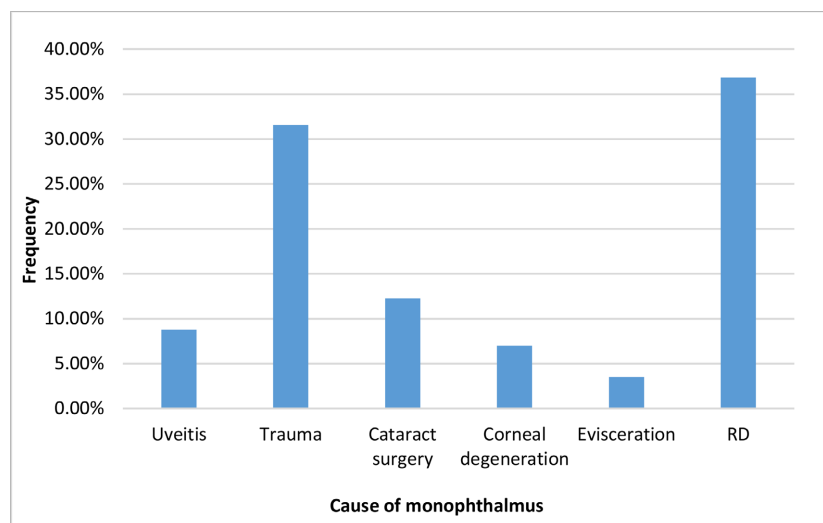


Figure 2. Distribution of patients according to cause of monocular vision.

We found 49.12% myopic patients and 26.31% hyperopia (Figure 3).

Patients were phakic in 91.23% of cases and pseudophakic in 7.02%.

The average consultation time was 40.80 days with extremes ranging from 1 day to 4 years. The consultation was done within the first fifteen days following the symptoms in 57.89% of cases.

The reasons for consultation were a decrease in visual acuity, isolated in 96.49% or associated with myodeopsis (45.45%), scotoma (25.45%) or phosphenes (18.18%). Preoperative visual acuity was less than 1/10<sup>th</sup> in 87.72% of our patients.

Objectified retinal dehiscences were retinal holes in 31.58% of our patients, single tears in 21.05% of cases, giant tears in 17.54% of patients and mixed dehiscences in 17.54% of cases. Horseshoe tears accounted for 12.28% respectively (Figure 4).

The average RD extension was estimated at 2.52 quadrants in our series.

Detachment was associated with macular lift (macula OFF) in 54.39% and a stage A PVR was found in 50.88% of our patients. Stage B and C PVRs accounted for 40.35% and 8.77% respectively.

The average turnaround time was 10 days with extremes of 1 to 30 days.

Surgery was performed in 42 patients (73.68%) with an externally in 25 patients (59.52%) and internally in 17 patients (40.47%).

Anatomical recovery was obtained in all patients who were operated on or

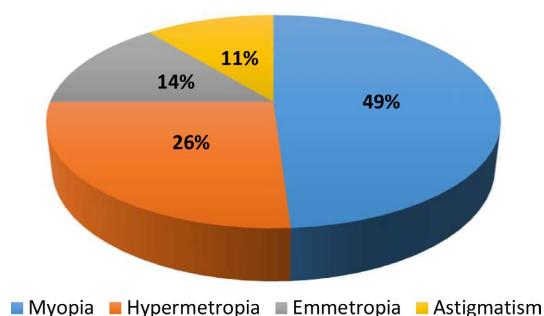


Figure 3. Distribution of patients according to refraction.

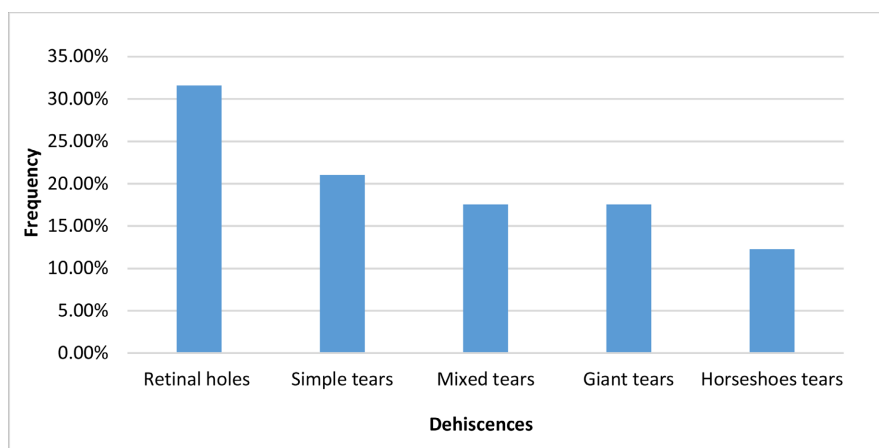


Figure 4. Distribution of dehiscences according to their type.

100% of the cases, but a surgical recovery (in one patient who was operated on internally and two operated on externally) was required, or 7.14%.

In this surgical series, we noted functional recovery in 27 patients (64.29%) of which 10 internally and 17 externally. Visual acuity was stable in 5 patients (11.9%) and decreased in 10 patients (20.81%).

In patients operated on regular monitoring had made it possible to highlight post-operative complications. For example, in patients who were operated internally, we found cataract (75%), silicone emulsification (4.76%) and passage of PFCL to macular (2.38%) (**Figure 5**) and external superinfection of the explant (2.38%). Ocular hypertonia was also observed in 4.76% of cases.

#### 4. Discussion

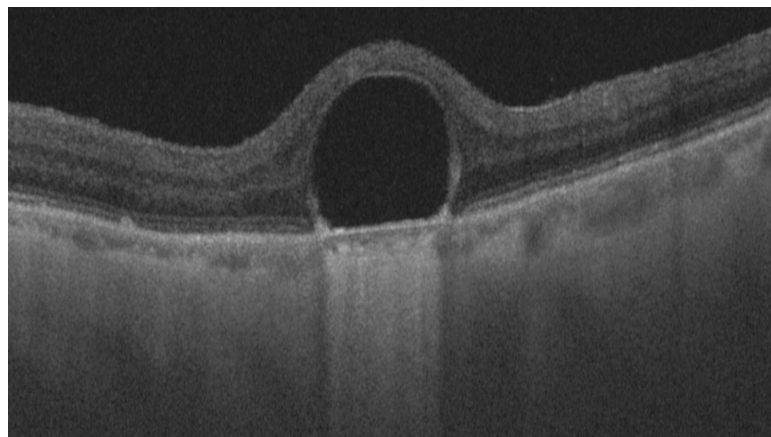
Retinal detachment is very rare before the age of 20 [2].

The age of occurrence varies gradually over time and follows a double bump profile. There is a spike in frequency between 20 and 30 years and then between 50 and 70 years [2].

This frequency of RRD in older subjects is linked to the aging process of the glass itself (synesis, rheological, biochemical and structural changes, enlargement of its base) [1].

The male predominance (87.72%) in our study is reported by STANGOS [3]; however, no scientific explanation was given.

In our study, half of our patients were myopic (49.12%). This frequency of myopia encountered is also described in the literature [1]. Myopia is a recognized risk factor in the occurrence of RRD. Indeed, 55% of these non-traumatic RRDs are due to the greater frequency of lesions of the retinal periphery that it causes [1]. The identified retinal dehiscence was dominated by holes (31.58%) as in the MATRI [4] and MATHIS [5] studies. According to NDIAYE [6], myopia is the major predisposing factor for the occurrence of RRD because it creates rhegmatogenous lesions on the retinal periphery. In total, the involvement of



**Figure 5.** OCT image of one of our patients presenting with a postoperative submacular PFCL bubble (rounded appearance of the bubble creating an acute angle with the layer of the retinal pigment epithelium).

myopia in RRD was also highlighted in our series and was the most common risk factor behind monocular vision.

In retinal detachment, decreased visual acuity is the main reason for consultation. Thus, depending on its severity, a variable consultation time can be noted [7].

In our series, the consultation time was 15 days for more than half of our patients; which was long compared to Finn's results [7]. This may be due to the small number of posterior segment specialists in our regions.

After surgery, the RD will evaluate the anatomical recovery but also functional. Various factors are associated with functional recovery however macular involvement, PVR and RD extension are the most described in the literature [1] [2]. Indeed, there is a strong correlation between the height of preoperative macular lifting and the degree of post-operative functional recovery [1]. This macular uplift also plays an important role in the management time. In our series, the macula was OFF in 54.38% of cases and the average time taken was 10 days. ROSS [8] in his study concluded that less than 30 days of macular lifting was associated with better postoperative visual acuity. On the contrary, old studies estimated that functional recovery after surgery was compromised beyond 7 days of macular lifting [9] [10]. This correct management time compared to recent studies is long in a one-eyed patient subject. In addition to impacting anatomical and functional recovery, this delay in surgery also promotes the occurrence and evolution of PVRs which is a factor of very poor prognosis especially those of stage C [11].

In 17 patients with intraocular surgery (23 Gauge) and 25 patients with external surgery, we had a final retinal reapplication rate of 88% and 100% respectively. The line gain was 1.77 lines for patients with vitrectomy surgery and 2.70 lines for externally operated patients for the same control time. Functional recovery was achieved in 61.90% of cases (26 patients) for both types of surgery while the final anatomical recovery was 100%. There would be no significant differences between the internal and external channels. Thus, the surgical prognosis will essentially depend on factors other than the surgical route chosen for the treatment of RRD [12]. The surgical success of RDD is based on effective treatment of retinal dehiscence, relief of vitreoretinal traction, and early treatment of dehiscence [1] [13]. Thus, the surgery will be done according to the most appropriate technique and according to the indications specific to each technique to ensure a simple but effective management of the RD: minimal treatment.

Given our study population (one-eyed patients), the silicone oil internal tamponation was chosen during intraocular surgery of our patients. This silicone option is consistent with most of the literature [1] [13].

The choice of silicone can also be justified on the one hand by the transparency properties of the latter compared to the gas allowing an early post-operative autonomy. On the other hand, silicone is more suitable for post-operative laser treatment.

With the advancements granted (23 G - 25 G - 27 G - Endolaser etc.), ab-interno surgery has taken precedence over the external route. However, the episcleral pathway is also effective for the treatment of RRD if the right indications are asked. It also allows a minimalist treatment with fewer complications [13].

In our series, we performed external surgery with proportions comparable in terms of anatomical and functional recovery to that of the intraocular pathway. This is consistent with the majority of large-scale comparison studies [14] [15] [16] [17] on surgical treatment of RDs (Table 1).

In our series, we made the option of silicone to remain in the absence of complications. According to Chauvaud [13], the authors agree that silicone must be removed at the end of the second month from an internal tamponation. After 2 months of buffering, complications are exposed mainly due to silicone emulsification in the anterior chamber (AC) [13].

In addition, it was shown that the final result was not modified by an extension of the buffer time when the retina is flat and the recurrence time of the PVRs exceeded, corresponding to the first 2 months [13]. This silicone ablation, although usually systematic, has a number of exceptions. The special cases of this silicone ablation are the RD of the strong myopic by dehiscence at the posterior pole compared to chorioretin atrophy and monocular vision. The silicone can be left at home in the one-eyed patient if the eye does not have a permanently fixed retinal situation and for whom it is believed that withdrawal would cause a recurrence of RD. However, leaving the silicone permanently in place does not exclude the occurrence of long-term complications [13]. In our series the silicone removal was performed in three patients however a few days after withdrawal, a recurrence of the RD motivated a surgical resumption. Thus, according to our experience and in agreement with the various authors the withdrawal of

**Table 1.** Anatomical and functional results of several series comparing at the base the different therapeutic techniques.

Studies	Indentation	Vitrectomy	Anatomical and/or functional recovery
Oshima <i>et al.</i> 2000 [14]	55 cases	47 cases	91% Indentation 91% Vitrectomy
Roider <i>et al.</i> 2001 [15]	60 cases	10 cases	98% Indentation 93% Vitrectomy
Brazitikos <i>et al.</i> 2005 [16]	75 cases	75 cases	83% Indentation 94% Vitrectomy
Cheng <i>et al.</i> 2006 [17]	92 cases	19 cases	85% Indentation 95% Vitrectomy
Our study	25 cases	17 cases	100% Vitrectomie (AR) 88% Indentation (AR) 52.94% Vitrectomie (FR) 68% Indentation (FR)

silicone in the one-eyed patients is only considered in case of complications with fall in visual acuity [13] [18].

However, our study has some limitations, namely the delay in consultation that can impact functional outcomes despite adequate and timely treatment. This could be explained on the one hand by the absence of retinal specialists in our regions, and on the other by the ignorance of this disease by the population. But also at the epidemiological level, a multicenter study would be more representative and would allow to determine the real incidence of RRD in one-eyed patients in our country. And finally, although the condition of the lens played an important role in the choice of surgical technique in our work, its impact on functional recovery could not be determined.

## 5. Conclusion

Monocular rhegmatogenous retinal detachment is increasingly common in our regions. Its diagnostic and therapeutic management must not suffer from any delay, because the risk of permanent blindness is not negligible. When the correct indications for RRD surgery are given, the post-operative results (anatomical and functional) have no significant difference between the internal and external routes. In one-eyed patients, silicone can be left standing in the absence of major complications. Examination of the adelphe eye and prophylactic treatment of lesions in myopic-monocular vision should be systematic in order to avoid the occurrence of a RDD that may engage the visual prognosis.

## Deceleration

The authors state that they have no connection with this article.

## Conflicts of Interest

The authors declare no conflicts of interest regarding the publication of this paper.

## References

- [1] Caputo, G., Metge Galatoire, F., Arndt, C. and Contrat, J. (2011) Retinal Detachments: 2011 Report French Society of Ophthalmology. Elsevier, Berlin, 545.
- [2] Girard, P. and Tandouni, R. (2006) "Idiopathic" Retinal Detachment. Clinical Semiology and Treatment. *Encycl. Méd. Chir. Ophthalmology*, 21-245.
- [3] Stangos, A.N., Petropoulos, I.K., Brozou, C.G., *et al.* (2004) Pars-Plana Vitrectomy Alone vs Vitrectomy with Scleral Buckling for Primary Rhegmatogenous Pseudophakic Retinal Detachment. *American Journal of Ophthalmology*, **138**, 952-958. <https://doi.org/10.1016/j.ajo.2004.06.086>
- [4] El Matri, L., Mghaieth, F., Chaker, N., *et al.* (2004) Simultaneous Bilateral Rhegmatogenous Retinal Detachments: About 7 Observations. *Journal Français d'Ophthalmologie*, **27**, 15-18. [https://doi.org/10.1016/S0181-5512\(04\)96086-X](https://doi.org/10.1016/S0181-5512(04)96086-X)
- [5] Mahtis, A., Pagot-Mathis, V., Dumas, S. and Roque, I. (2000) Retinal Complications of Cataract Surgery. *Journal Français d'Ophthalmologie*, **23**, 88-95.



- [6] Ndiaye, P.A., Koffane, R.J., Wade, A., *et al.* (2001) Frequency of Rhegmatogenous Lesions in Melanodermal Myopes. *Journal Français d'Ophtalmologie*, **24**, 927-929.
- [7] Finn, A.P., Elliott, D., Kim, L.A., *et al.* (2016) Characteristics and Outcomes of Simultaneous Bilateral Rhegmatogenous Retinal Detachments. *Ophthalmic Surgery, Lasers and Imaging Retina*, **47**, 840-845. <https://doi.org/10.3928/23258160-20160901-07>
- [8] Ross, W.H. and Kozy, D.W. (1998) Visual Recovery in Macular-Off Rhegmatogenous Retinal Detachments. *Ophthalmology*, **105**, 2149-2153. [https://doi.org/10.1016/S0161-6420\(98\)91142-3](https://doi.org/10.1016/S0161-6420(98)91142-3)
- [9] Burton, T.C. (1982) Recovery of Visual Acuity after Retinal Detachment Involving the Macula. *Transactions of the American Ophthalmological Society*, **80**, 475-497.
- [10] Gundry, M.F. and Davies, E.W.G. (1974) Recovery of Visual Acuity after Retinal Detachment Surgery. *American Journal of Ophthalmology*, **77**, 310-314. [https://doi.org/10.1016/0002-9394\(74\)90735-1](https://doi.org/10.1016/0002-9394(74)90735-1)
- [11] Berrod, J.P., Sautiere, B., Rozot, P. and Raspiller, A. (1996) Retinal Detachment after Cataract Surgery. *International Ophthalmology*, **20**, 301-308. <https://doi.org/10.1007/BF00176882>
- [12] Haugstad, A., Moosmayer, S. and Bragadóttir, R. (2017) Primary Rhegmatogenous Retinal Detachment—Surgical Methods and Anatomical Outcome. *Acta Ophthalmologica*, **95**, 247-251. <https://doi.org/10.1111/aos.13295>
- [13] Chauvaud, D. and Azan, F. (2004) Retinal Detachment Surgery. Elsevier, Amsterdam, 110.
- [14] Oshima, Y., Yamanishi, S., Sawa, M., Motokura, M., Harino, S., *et al.* (2000) Two-Year Follow-Up Study Comparing Primary Vitrectomy with Scleral Buckling for Macula-Off Rhegmatogenous Retinal Detachment. *Japanese Journal of Ophthalmology*, **44**, 538-549. [https://doi.org/10.1016/S0021-5155\(00\)00205-7](https://doi.org/10.1016/S0021-5155(00)00205-7)
- [15] Roider, J., Hoerauf, H., Hager, A., Herboth, T. and Laqua, H. (2001) Conventional Ablation Surgery or Primary Vitrectomy in Complicated Retinal Holes. *Ophthalmologie*, **98**, 887-891. <https://doi.org/10.1007/s003470170069>
- [16] Brazitikos, P.D. androudi, S., D'amico, D.J., Papadopoulos, N., Dimitrakos, S.A., *et al.* (2003) Use of Perfluorocarbon Fluid in Primary Vitrectomy Repair of Multiple Break Retinal Detachment. *Retina*, **23**, 615-621. <https://doi.org/10.1097/00006982-200310000-00002>
- [17] Cheng, S.-F., Yang, C.H., Lee, C.H., Yang, C.M., Huang, J.S., *et al.* (2008) Anatomical and Functional Results of Surgery for Primary Rhegmatogenous Retinal Detachment in High Myopes. *Eye*, **22**, 70-76. <https://doi.org/10.1038/sj.eye.6702527>
- [18] Trigui, A., Gharbi, J., Hamdi, S., Mahfoudh, K.H. and Feki, J. (2013) Prolonged Silicone Oil Tamponade: Indications and Tolerance. *Journal Français d'Ophtalmologie*, **36**, 117-123. <https://doi.org/10.1016/j.jfo.2012.06.006>