

# Thiel-Behnke Corneal Dystrophy in a Young Man in Denmark—A Case Report

Sara Bøgelund Rasmussen\*, Anders Peter Søndergaard

Department of Ophthalmology, University Hospital of Southern Denmark, Vejle Hospital, Denmark

Email: \*sabr9@hotmail.com

**How to cite this paper:** Rasmussen, S.B. and Søndergaard, A.P. (2024) Thiel-Behnke Corneal Dystrophy in a Young Man in Denmark—A Case Report. *Open Journal of Ophthalmology*, 14, 208-217.  
<https://doi.org/10.4236/ojoph.2024.143021>

**Received:** June 4, 2024

**Accepted:** July 29, 2024

**Published:** August 1, 2024

Copyright © 2024 by author(s) and Scientific Research Publishing Inc. This work is licensed under the Creative Commons Attribution International License (CC BY 4.0).  
<http://creativecommons.org/licenses/by/4.0/>



Open Access

## Abstract

**Background:** This case report presents a case of bilateral Thiel-Behnke corneal dystrophy in Denmark. Thiel-Behnke is an autosomal dominant inherited epithelial-stromal TGFBI dystrophy causing visual impairment. **Methods and Results:** This case study presents a 24-year-old Lithuanian man, with no previous ocular history, who had experienced slowly progressive visual impairment since his childhood. He was examined at the Department of Ophthalmology at Vejle Hospital and Aarhus University Hospital, where he was diagnosed with bilateral Thiel-Behnke corneal dystrophy. Histology confirmed the diagnosis. A lamellar corneal transplantation was performed in the right eye; however, due to epithelial growth under the corneal graft, it was later decided to redo the operation. Following the operations, the patient experienced a visual improvement in best corrected visual acuity (BCVA) from 0.1 (20/25 Snellen equivalent) to 0.3 (20/40 Snellen equivalent) in his right eye. **Conclusions:** This case of Thiel-Behnke corneal dystrophy is to our knowledge the first reported case in Denmark.

## Keywords

Thiel-Behnke Corneal Dystrophy, Thiel-Behnke, Corneal Dystrophy, Honeycomb Dystrophy, Cornea

## 1. Introduction

A corneal dystrophy is an inherited disorder, where deposition of abnormal material in the cornea disturbs corneal transparency and refraction [1]. The corneal dystrophies are often bilateral, symmetric, slowly progressive, and are not related to environmental or systemic factors, even though there are some exceptions. The International Classification of Corneal Dystrophies (IC3D) have suggested to classify corneal dystrophies in the following classes according to lo-

cation; 1) epithelial and subepithelial dystrophies, 2) epithelial-stromal Transforming Growth Factor Beta Induced (TGFBI) dystrophies, 3) stromal dystrophies, and 4) endothelial dystrophies. Moreover, the IC3D also suggest categorizing the dystrophies based on the underlying genetics using the following categories; 1) Gene and mutation is known, 2) Gene is unknown and chromosomal loci is known, 3) Gene and chromosomal loci is unknown, and 4) Suspected or new corneal dystrophies [2].

Thiel-Behnke corneal dystrophy (TBCD), also called honeycomb corneal dystrophy, is an epithelial-stromal TGFBI dystrophy, genetic category 1 [2]. It is autosomal dominant inherited and located on the genetic loci 5q31 on the TGFBI gene [2]-[6]. The symptoms begin in the early childhood with slowly progressive visual impairment, and in some cases painful corneal erosions. Initially, irregular scattered opacities can be observed, which later develops into symmetrical subepithelial honeycomb-shaped opacities, often in the central part of cornea. These opacities can later grow into the stromal layer and spread to the peripheral parts of cornea [2].

With transmission electron microscopy, curly collagen fibers can be detected. Furthermore, hyperreflective material in Bowman's layer extending into the epithelium in a sawtooth-shaped pattern can be found in an Optical Coherence Tomography (OCT). With these findings, the examiner can differentiate TBCD from Reis-Bücklers Corneal Dystrophy (RBCD), which can be a difficult task, as they present with similar symptoms. Unlike TBCD, RBCD is characterized by irregular diffuse geographic-like corneal opacities, rod-shaped bodies in transmission electron microscopy, and a homogenous layer of hyperreflective deposits often with a serrated anterior border is apparent at the level of the Bowman layer and the anterior stroma in OCT [2] [7] [8].

This case study displays a case of Thiel-Behnke corneal dystrophy diagnosed in a young Lithuanian man living in Denmark.

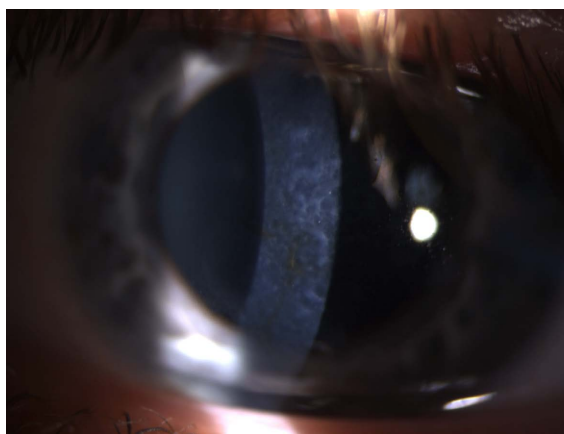
## 2. Case Presentation and Results

A 24-year-old Lithuanian man was referred to the department of Ophthalmology at Vejle Hospital in February 2017. He experienced blurred vision in both eyes. It started in his childhood, but the visual impairment had especially developed over the last ten years. He did not experience pain. The patient had no previous ocular history and had not experienced pain. His mother had had a corneal transplant operation in one eye, because of corneal dystrophy, unknown which type. The mother was living in Lithuania, so it was not possible to examine her or run genetic tests. There was no other family history of corneal dystrophy.

The examination showed a best corrected visual acuity (BCVA) of 0.1/0.2 (20/25 and 20/32 Snellen equivalent), a small exotropia in primary position, centrally located superficial corneal iron deposits, and symmetric corneal subepithelial and stromal reticular opacities in both eyes. The results rose a suspicion

of Thiel-Behnke corneal dystrophy (TBCD), which the department of Ophthalmology at Vejle Hospital is unable to treat. Therefore, the patient was referred to the specialized corneal team at the department of Ophthalmology at Aarhus University Hospital.

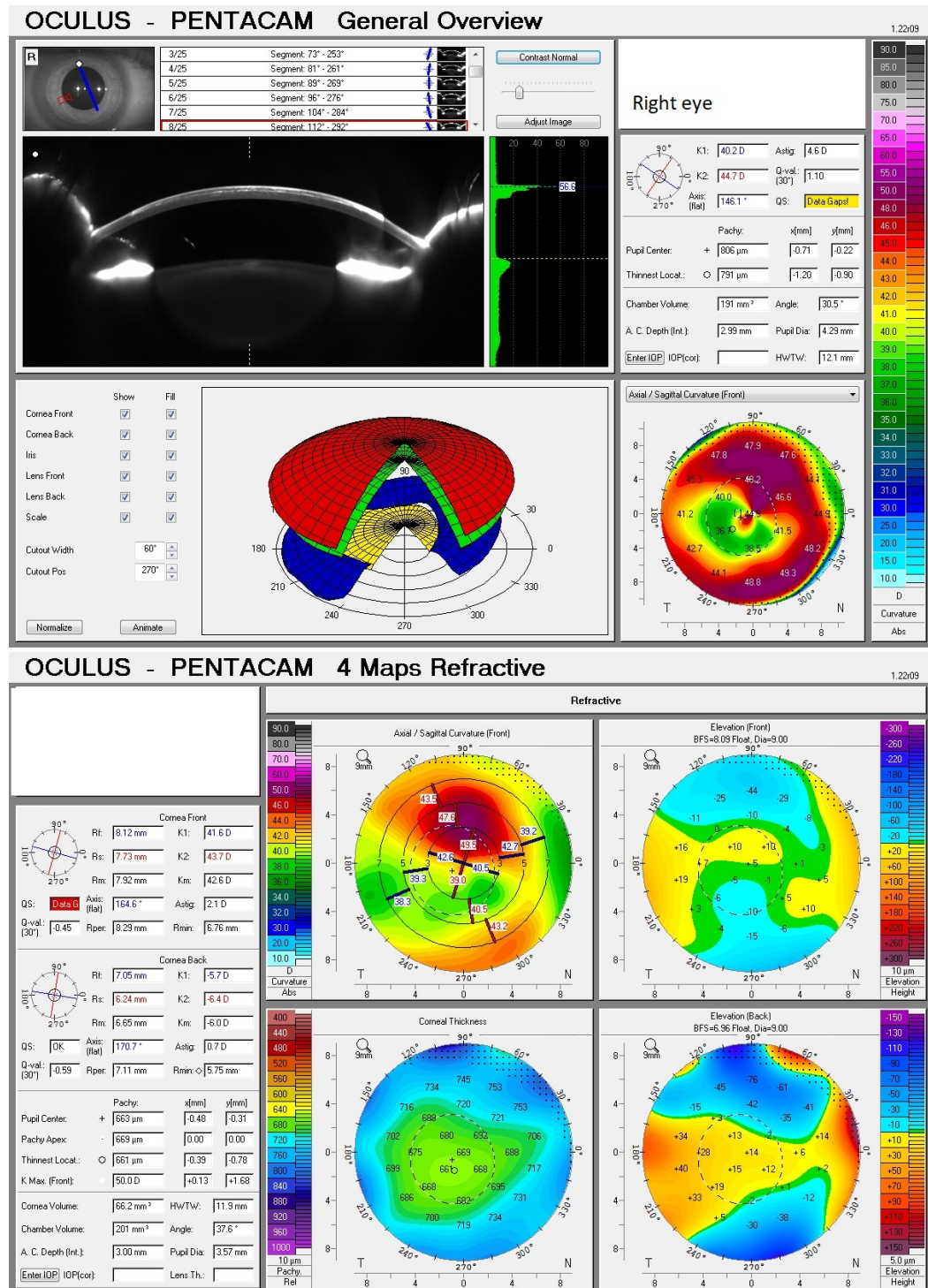
At Aarhus University Hospital, the findings were confirmed (**Figure 1**). An anterior Optical Coherence Tomography (OCT) showed a thickening of the anterior corneal stroma, especially in the right eye. The opacities reached a depth of approximately 217  $\mu\text{m}$  in the right eye and approximately 200  $\mu\text{m}$  in the left eye. Corneal topography (Pentacam, Oculus) (**Figure 2** and **Figure 3**) showed an irregular astigmatism in the right eye (10 - 11 diopters), and a more regular astigmatism in the left eye (4.2 diopters). As described the thickness of the corneal opacities in the right eye were 217  $\mu\text{m}$ , why phototherapeutic keratectomy (PTK) was not considered to be suitable for this patient. It was decided to perform a corneal transplantation (FS-ALK: Femtosecond laser-assisted anterior lamellar keratoplasty) on the right eye in local anesthesia. The surgery was performed October 2017 at Aarhus University Hospital. With Visumax (Zeiss, Germany) an anterior donor lamella, with the size of 7.50 mm in diameter, 0.200 mm thickness and an edge-angle of 70 degrees, was made and used in the surgery. A histologic examination after the surgery confirmed the TBCD diagnosis (**Figure 4** and **Figure 5**). The day after the operation, there was an inferonasal displacement of the graft, why it was repositioned in local anesthesia. Twenty-nine days after the operation, the bandage contact lens was removed. The corneal graft was clear, and a few inferior islands of epithelial cells were seen under the graft. The BCVA was 0.6 in the right eye (20/80 Snellen equivalent). No interventions were performed, and the patient was scheduled for at control 2 month later.



**Figure 1.** Thiel-Behnke corneal dystrophy (TBCD) in the patient's right eye.

Thirty-five days after the surgery, the patient contacted the department of Ophthalmology, because he experienced increased blurred vision in the right eye. It was decided to perform a second FS-ALK in the right eye, because of epithelial growth under the corneal graft. This was performed 41 days after the first surgery. The first corneal graft was removed, the area was cleaned for epithelial

cells, and a new anterior donor lamella with the same size as the previous was placed. The first day after the second surgery, acceptable graft conditions were observed. 22 days after the second surgery, the patient had increased intraocular pressure in the right eye (37 mmHg). It was interpreted as a response to the steroid eye drops treatment, and he was given pressure reducing eye drops.



**Figure 2.** Corneal topography (Pentacam, Oculus) scan of the patient's right eye (May 2017).

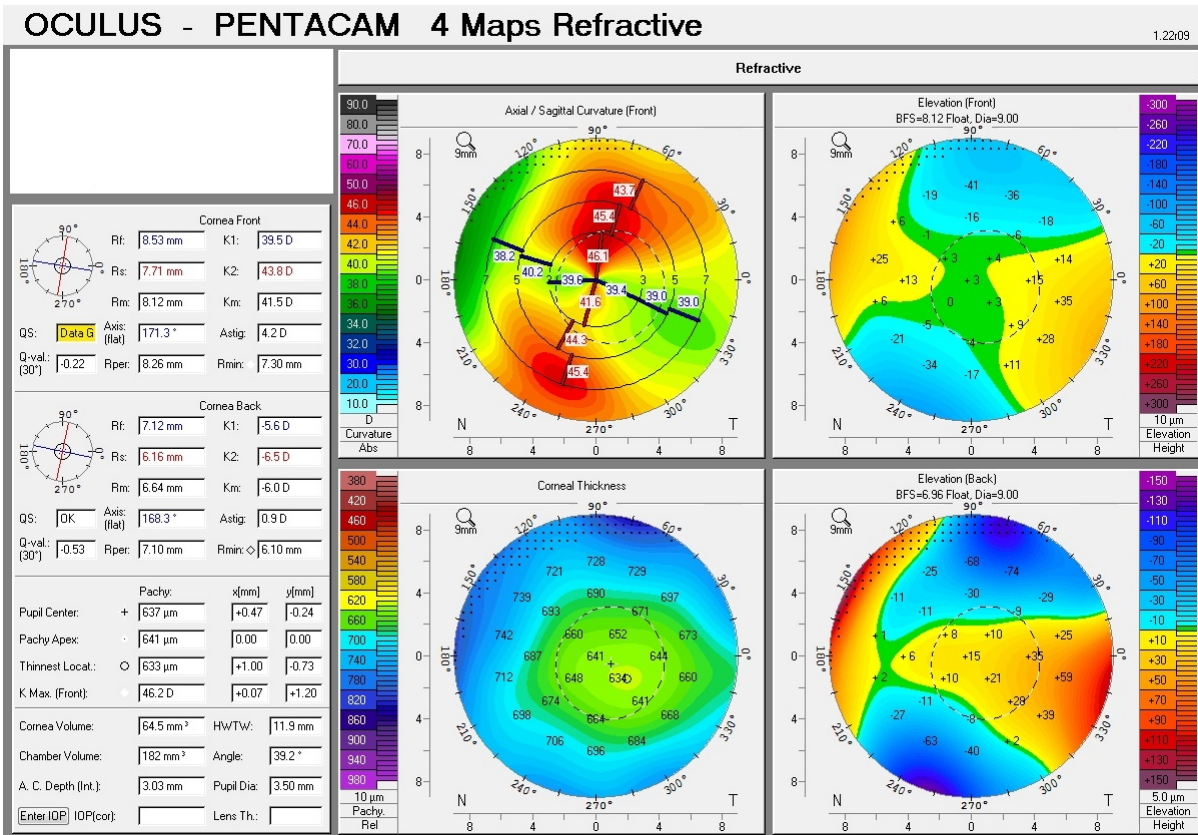
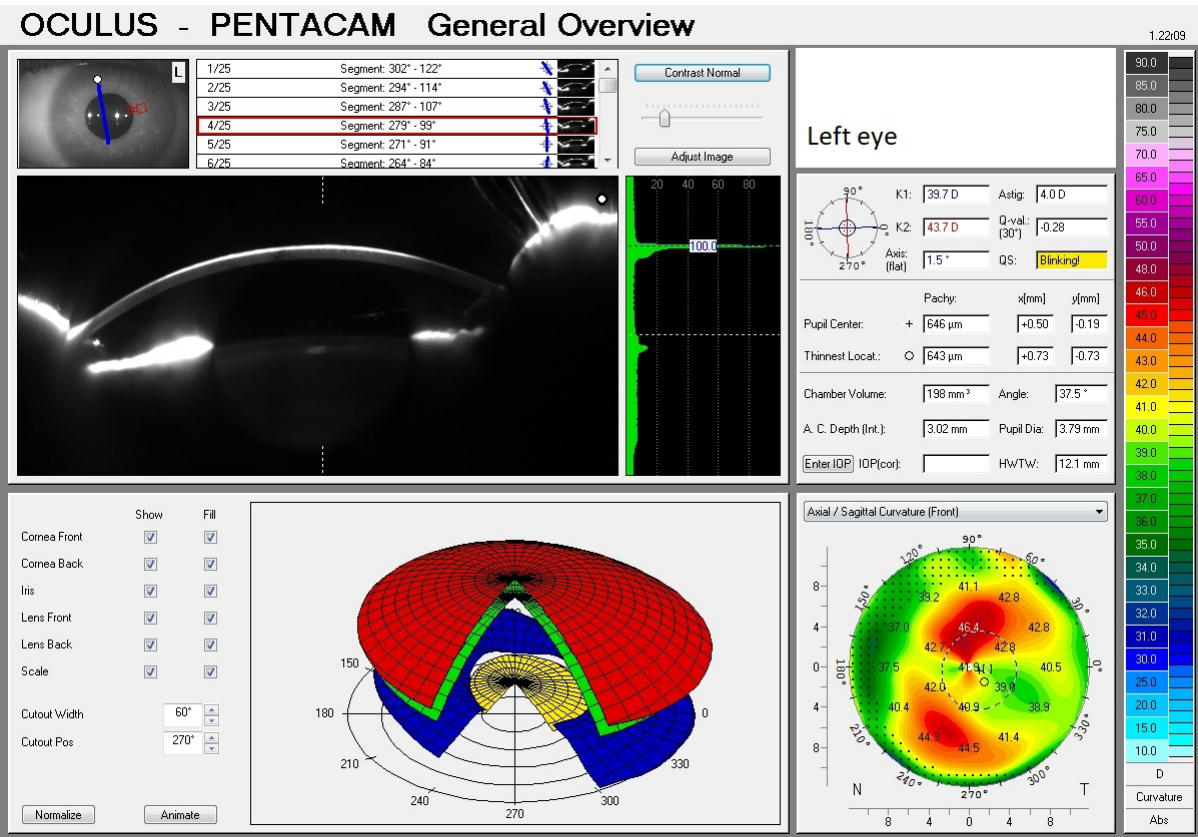
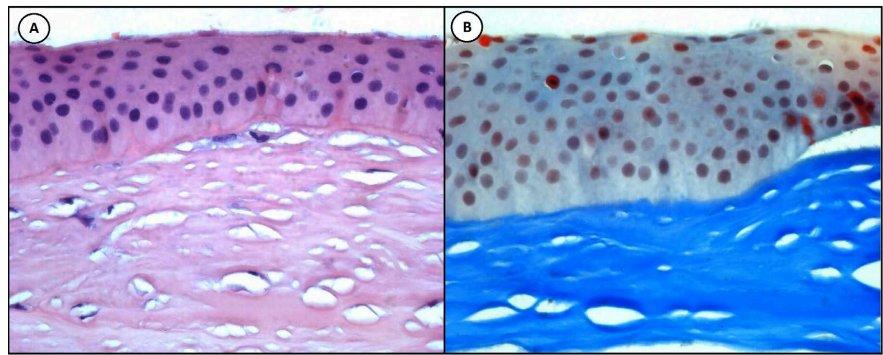
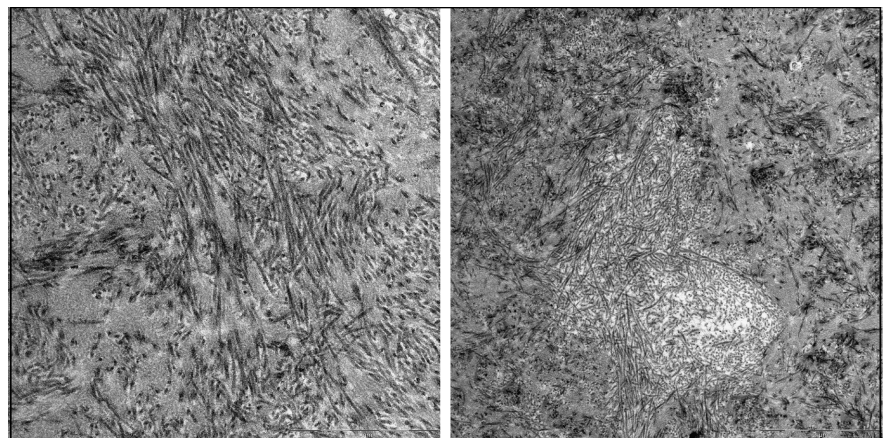


Figure 3. Corneal topography (Pentacam, Oculus) scan of the patient's left eye (May 2017).



**Figure 4.** (A) Histology examination with Bowman's layer extending into the epithelium in a sawtooth-shaped pattern. (B) Histology examination with Alcian Blue Stain.



**Figure 5.** Electron microscopy with curly collagen fibers.

148 days after the first operation, the examination showed a clear corneal graft, no epithelial growth, a discrete irregular corneal surface, and a BCVA of 0.2 in the right eye (20/25 Snellen equivalent).

866 days (approximately 2 years) after the first surgery, the ophthalmologic examination showed a clear corneal graft in the right eye and moderate TBCD in the left eye. The BCVA was 0.3/0.4 (20/40 and 20/50 Snellen equivalent). The examiner did not find any explanations for the vision loss, neither cataract, intraocular pressure changes, macular changes nor retinal changes were found. The patient was content with the results and was not interested in further surgical treatment at that moment. Until now the patient has not returned to the department of Ophthalmology, why there is no further information about the long-term outcomes of the surgery and the progression of the TBCD in the left eye.

### 3. Discussion

This case of TBCD is, to our knowledge, the first reported case in Denmark, which is remarkable, even though the patient is originally from Lithuania. This case is relevant, because it adds to the existing material on the subject and can be helpful in the diagnosis of future cases. Genetic counseling is relevant and valua-

ble for these patients. Therefore, it is very important to include the inheritance aspects in the information given to the patients [9]. The patient in this case report had a mother, who had had a corneal transplant operation, because of corneal dystrophy, unknown which type. No relatives were interested in genetic tests at the time.

Regarding treatment, a stage-related therapeutic approach is recommended. Patients with superficial corneal opacities are initially treated with conservative therapy with gels, ointments, and contact lenses. When the conservative therapy is no longer sufficient, the patients are suitable candidates for PTK. PTK can be repeated in the attempt to postpone corneal transplantation, both lamellar and penetrating keratoplasty [10]. Unfortunately, this was not suitable for the patient in the described case, because of the thickness of the corneal opacities.

A study by Hieda *et al.* found a significant improvement in BCVA after PTK surgery. Gradual recurrence of central superficial opacities was observed in the PTK-treated patients. In one patient significant recurrence compromising the BCVA was observed in one eye after 42 months [11]. Recurrence seems to appear later with TBCD compared to RBCD [10] [11]. PTK induces a risk of irregular corneal surfaces, hyperopic shift, and stromal haze [12]. The use of wave-front-guided photorefractive keratectomy (PRK) is described to reduce the hyperopic shift induced by PTK and might enhance the effect of PTK [13].

In case of deeper stromal affection corneal transplantation, lamellar keratoplasty or penetrating keratoplasty, might be a possible treatment [8]-[10]. Femtosecond laser-assisted anterior lamellar keratoplasty (FS-ALK) was the chosen treatment for the patient in the reported case. It is a relatively new surgical method showing safe and efficient results [14]-[18]. With FS-ALK it is possible to treat a larger corneal area than with PTK, and the literature reports good postoperative results [17].

Penetrating keratoplasty has shown good clinical outcomes, but induces a risk of immunological rejection, graft failure, irregular astigmatism, infection, and other complications. Therefore, it should be avoided in patients, where FS-ALK can be used and postpone the need for further treatment [17].

Even though recurrence is a known risk, TBCD is considered to have a relatively good prognosis compared to other corneal dystrophies. The patients are older at the onset of treatment, and time of recurrence is longer compared to several other corneal dystrophies [19].

Ongoing research is investigation the use of gene therapy and gene manipulations to prevent corneal dystrophies and recurrence [20]. To our knowledge, there is no current literature regarding gene therapy and Thiel Behnke.

## 4. Conclusion

The 24-year-old Lithuanian man was diagnosed with Thiel Behnke corneal dystrophy, confirmed by a histologic examination. He was treated with a corneal transplantation (FS-ALK) on the right eye. Forty-one days after the first surgery

a second FS-ALK was performed on the right eye due to epithelial growth under the corneal graft. Approximately 2 years after the first surgery, the ocular examination showed a vision reduction on the right eye to BCVA 0.3 (20/40 in Snellen equivalent) despite of a clear corneal craft. The patient was content with the result and was not interested in further surgical treatment. This case of TBCD is, to our knowledge, the first reported case in Denmark. The case adds to the existing material on the subject and can be helpful in the diagnosis of future cases.

## Acknowledgements

Not applicable.

## Statement of Ethics

Written informed consent was obtained from the patient for publication of the details of their medical case and any accompanying images. Ethical approval is not required for this study in accordance to local or national guidelines.

## Author Contributions

APS diagnosed the patient in the clinic and took part in the treatment. SBR has collected the presented data from the patient's medical record and written the case report, with support from APS. Both authors read and approved the final manuscript.

## Data Availability Statement

The data presented in this study are available upon request from the corresponding author.

## Funding Sources

This study received no external funding.

## Conflicts of Interest

The authors declare no conflicts of interest.

## References

- [1] Moshirfar, M., Bennett, P. and Ronquillo, Y. (2022) Corneal Dystrophy. StatPearls.
- [2] Weiss, J.S., Rapuano, C.J., Seitz, B., Busin, M., Kivelä, T.T., Bouheraoua, N., *et al.* (2024) IC3D Classification of Corneal Dystrophies—Edition 3. *Cornea*, **43**, 466-527. <https://doi.org/10.1097/ico.0000000000003420>
- [3] Cho, K.J., Mok, J.W., Na, K.S., Rho, C.R., Byun, Y.S., Hwang, H.S., *et al.* (2012) TGFBI Gene Mutations in a Korean Population with Corneal Dystrophy. *Molecular Vision*, **18**, 2012-2021.
- [4] Ridgway, A.E., Akhtar, S., Munier, F.L., Schorderet, D.F., Stewart, H., Perveen, R., *et al.* (2000) Ultrastructural and Molecular Analysis of Bowman's Layer Corneal Dystrophies: An Epithelial Origin? *Investigative Ophthalmology & Visual Science*, **41**,

- 3286-3292.
- [5] Chen, Y.-J., Chen, J.-T., Lu, D.-W. and Tai, M.-C. (2010) *In Vivo* Corneal Confocal Microscopic Findings and Gene Analysis of Three Patients with Thiel-Behnke Corneal Dystrophy. *British Journal of Ophthalmology*, **94**, 262-264. <https://doi.org/10.1136/bjo.2009.165217>
  - [6] Kannabiran, C. and Klintworth, G.K. (2006) TGFBI Gene Mutations in Corneal Dystrophies. *Human Mutation*, **27**, 615-625. <https://doi.org/10.1002/humu.20334>
  - [7] Weidle, E.G. (1999) Honeycomb-Shaped Corneal Dystrophy of Thiel and Behnke. Re-classification and Distinction from Reis-Bücklers' Corneal Dystrophy. *Klin Monbl Augenheilkd*, **214**, 125-135. <https://doi.org/10.1055/s-2008-1034764>
  - [8] Küchle, M., Green, W.R., Völcker, H.E. and Barraquer, J. (1995) Reevaluation of Corneal Dystrophies of Bowman's Layer and the Anterior Stroma (Reis-Bücklers and Thiel-Behnke Types): A Light and Electron Microscopic Study of Eight Corneas and a Review of the Literature. *Cornea*, **14**, 333-354. <https://doi.org/10.1097/00003226-199507000-00001>
  - [9] Klintworth, G.K. (2009) Corneal Dystrophies. *Orphanet Journal of Rare Diseases*, **4**, Article No. 7. <https://doi.org/10.1186/1750-1172-4-7>
  - [10] Seitz, B. and Lisch, W. (2011) Stage-Related Therapy of Corneal Dystrophies. In: Seitz, B. and Lisch, W., Eds., *Corneal Dystrophies*, S. Karger AG, 116-153. <https://doi.org/10.1159/000324081>
  - [11] Hieda, O., Kawasaki, S., Wakimasu, K., Yamasaki, K., Inatomi, T. and Kinoshita, S. (2013) Clinical Outcomes of Phototherapeutic Keratectomy in Eyes with Thiel-Behnke Corneal Dystrophy. *American Journal of Ophthalmology*, **155**, 66-72.E1. <https://doi.org/10.1016/j.ajo.2012.06.022>
  - [12] Fagerholm, P. (2003) Phototherapeutic Keratectomy: 12 Years of Experience. *Acta Ophthalmologica Scandinavica*, **81**, 19-32. <https://doi.org/10.1034/j.1600-0420.2003.00015.x>
  - [13] Hou, Y. and Hsiao, C. (2017) Combination of Phototherapeutic Keratectomy and Wavefront-Guided Photorefractive Keratectomy for the Treatment of Thiel-Behnke Corneal Dystrophy. *Indian Journal of Ophthalmology*, **65**, 318-320. [https://doi.org/10.4103/ijo.ijo\\_683\\_16](https://doi.org/10.4103/ijo.ijo_683_16)
  - [14] Yoo, S.H., Kymionis, G.D., Koreishi, A., Ide, T., Goldman, D., Karp, C.L., *et al.* (2008) Femtosecond Laser-Assisted Sutureless Anterior Lamellar Keratoplasty. *Ophthalmology*, **115**, 1303-1307.E1. <https://doi.org/10.1016/j.ophtha.2007.10.037>
  - [15] Shousha, M.A., Yoo, S.H., Kymionis, G.D., Ide, T., Feuer, W., Karp, C.L., *et al.* (2011) Long-Term Results of Femtosecond Laser-Assisted Sutureless Anterior Lamellar Keratoplasty. *Ophthalmology*, **118**, 315-323. <https://doi.org/10.1016/j.ophtha.2010.06.037>
  - [16] Abusayf, M.M., Tobaigy, M.F., Alfawaz, A. and Alkatan, H.M. (2022) Femtosecond Laser Assisted Superficial Lamellar Keratectomy as a Successful Treatment of Corneal Opacity in a Patient with Thiel Behnke Corneal Dystrophy. *International Journal of Surgery Case Reports*, **95**, Article 107257. <https://doi.org/10.1016/j.ijscr.2022.107257>
  - [17] Steger, B., Romano, V., Biddolph, S., Willoughby, C.E., Batterbury, M. and Kaye, S.B. (2016) Femtosecond Laser-Assisted Lamellar Keratectomy for Corneal Opacities Secondary to Anterior Corneal Dystrophies. *Cornea*, **35**, 6-13. <https://doi.org/10.1097/ico.0000000000000665>
  - [18] Malyugin, B.E., Belodedova, A., Antonova, O., Gelyastanov, A., Tuuminen, R., Levinger, E., *et al.* (2022) Clinical Comparison of Manual and Laser-Cut Corneal Tun-

- nel for Intrastromal Air Injection in Femtosecond Laser-Assisted Deep Anterior Lamellar Keratoplasty (DALK). *Graefe's Archive for Clinical and Experimental Ophthalmology*, **261**, 185-191. <https://doi.org/10.1007/s00417-022-05765-9>
- [19] Ellies, P., Renard, G., Valleix, S., Yves Boelle, P. and Dighiero, P. (2002) Clinical Outcome of Eight Bigh3-Linked Corneal Dystrophies. *Ophthalmology*, **109**, 793-797. [https://doi.org/10.1016/s0161-6420\(01\)01025-9](https://doi.org/10.1016/s0161-6420(01)01025-9)
- [20] Courtney, D.G., Atkinson, S.D., Moore, J.E., Maurizi, E., Serafini, C., Pellegrini, G., *et al.* (2014) Development of Allele-Specific Gene-Silencing siRNAs for TGFBI Arg124Cys in Lattice Corneal Dystrophy Type I. *Investigative Ophthalmology & Visual Science*, **55**, 977-985. <https://doi.org/10.1167/iovs.13-13279>