

Small Cell Neuroendocrine Carcinoma of the Vulva: Case Report and Literature Review

Gabriela Françoes Rostirolla^{1*}, Alessandra Guerra², Maria Carolina Rey Alt³,
Luiza Tesser Dalla Libera³, Maria Eduarda Appel Binda³, Márcia Appel⁴,
Fernando De Marco dos Santos⁵

¹Department of Obstetrics and Gynecology, Caxias do Sul University, Caxias do Sul, Brazil

²Department of Pathology, UNIVATES, Lajeado, Brazil

³Medical Student, Caxias do Sul University, Caxias do Sul, Brazil

⁴Department of Obstetric and Gynecology, Federal University of Rio Grande do Sul, Porto Alegre, Brazil

⁵Department of Oncology Surgeon, Caxias do Sul University, Caxias do Sul, Brazil

Email: *gabirossti@gmail.com, Alessandraguerra@grupodiagnose.com.br

How to cite this paper: Rostirolla, G.F., Guerra, A., Alt, M.C.R., Libera, L.T.D., Binda, M.E.A., Appel, M. and De Marco dos Santos, F. (2024) Small Cell Neuroendocrine Carcinoma of the Vulva: Case Report and Literature Review. *Open Journal of Obstetrics and Gynecology*, 14, 295-300.

<https://doi.org/10.4236/ojog.2024.142027>

Received: January 9, 2024

Accepted: February 26, 2024

Published: February 29, 2024

Copyright © 2024 by author(s) and Scientific Research Publishing Inc.

This work is licensed under the Creative Commons Attribution International License (CC BY 4.0).

<http://creativecommons.org/licenses/by/4.0/>



Open Access

Abstract

Background: Neuroendocrine neoplasms are those that develop from a neuroendocrine cell. They most commonly affect the lungs, gastrointestinal tract, and pancreas, being rare conditions in the female genital tract. When present, these neoplasms often manifest with nonspecific signs and symptoms such as pain, itching, swelling, single-focus lesions, bleeding, and enlargement of inguinal lymph nodes, in addition to the presence of progressively enlarging vulvar nodules. Consequently, the diagnostic investigation involves histopathological examination and confirmation through immunohistochemistry. **Objective:** To present a comprehensive understanding of this rarely studied pathology. The primary objective is to provide valuable insights that could aid in the future development of universally applicable treatment guidelines. **Case Presentation:** A 57-year-old female, with no prior comorbidities, menopause at 36, who presented with a left vulvar nodule accompanied by intense pain and swelling, later diagnosed with small cell neuroendocrine carcinoma in the vulva. **Conclusion:** This case report highlights the importance of enhancing our knowledge regarding small cell neuroendocrine carcinoma in the vulva, given its scarcity in medical literature. The information presented here underscores the need for standardized diagnostic and treatment approaches, paving the way for future consensus on managing this uncommon but challenging neoplasm.

Keywords

Vulvar Neoplasms, Carcinoma, Small Cell, Carcinoma, Neuroendocrine, Genital Neoplasms, Female, Vulvar Diseases

1. Introduction

Neuroendocrine neoplasms develop from a nerve cell with the capacity to produce and release hormones into the bloodstream. Classified by the World Health Organization into well-differentiated neuroendocrine tumors (NET) and poorly differentiated neuroendocrine carcinomas (NEC)—further subdivided into small and large cells [1]—they predominantly affect the lungs, gastrointestinal tract, and pancreas, with rare occurrences in the female genital tract, particularly the vulva.

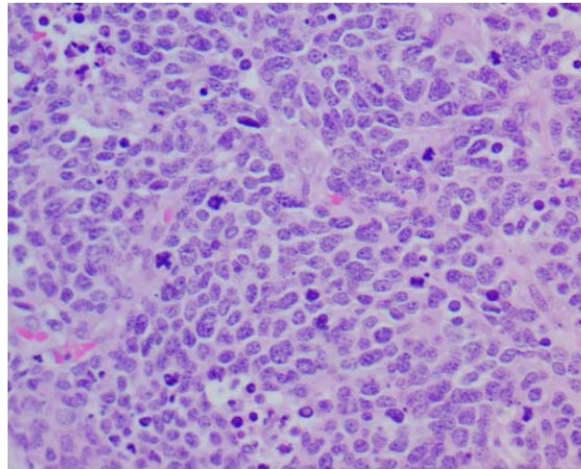
Analysis of past cases provides valuable insights into the diverse demographics impacted by small cell neuroendocrine carcinoma of the vulva. Notably, the global documentation until 2014 only accounted for 14 cases, with the inaugural instance recorded in 1982. This limited dataset depicts a diverse clinical landscape, characterized by variations in lesion sizes, treatment modalities, and outcomes. These cases span different age groups, ranging from a 28-year-old to 79-year-old, with distinct therapeutic approaches such as surgery, radiotherapy, and chemotherapy. Despite this heterogeneity, a common theme emerges in the aggressive nature of the disease, as evidenced by recurrent cases, metastases to various sites, and relatively short survival periods post-recurrence [2]. The varied clinical landscape, coupled with the aggressive nature of the disease underscores the pressing need for continued research.

Diagnosis heavily relies on pathology and immunohistochemistry of the lesions, as the signs and symptoms are very nonspecific. Due to their rarity, there is still insufficient data to establish a universal treatment guideline [3]. This case report aims to provide information about small cell neuroendocrine carcinoma of the vulva, contributing to a better understanding and potentially enabling the creation of tailored treatment strategies to improve patient outcomes in the future [1].

2. Case Report

A 57-year-old female patient, without previous comorbidities, experienced menopause at 36 years old and presented with a left vulvar nodule accompanied by intense pain and swelling. An ultrasound of the left vulva revealed a heterogeneous, oval-shaped, well-defined nodule with anechoic cystic areas in between, approximately 0.7 cm deep from the skin surface and measuring 2.6×1.8 cm. Additionally, a cytopathological examination of the uterine cervix showed no abnormalities, and colposcopy with biopsy revealed chronic endocervicitis.

Given the condition, excision of the lesion was performed, resulting in significant pain relief. The anatomopathological examination identified a malignant neoplasm with marked cellularity, presence of crushing artifacts, and a large number of mitoses (Figure 1). Subsequently, the patient experienced a return of pain but without vaginal bleeding, fever, or weight loss. Immunohistochemistry confirmed the diagnosis of small cell neuroendocrine carcinoma in the vulva. Further staging examinations, including PET scan, pelvic and abdominal MRI,



H&E, 400X, MAT 1

Figure 1. Histopathological diagnosis of high-grade neuroendocrine carcinoma in left hemivulvectomy resection.

and chest CT scan, did not identify metastasis. Subsequently, the patient underwent radical vulvectomy, revealing disease-free margins. Later, the patient received radiotherapy. After 6 months of follow-up, the patient improved well and the disease did not progress.

Free and informed consent was obtained by the patient prior to the case description.

3. Discussion

Neuroendocrine carcinoma comprises a heterogeneous group of neoplasms, representing 2% of gynecological tract cancers. It presents four subtypes: typical and atypical carcinoid tumors, constituting well-differentiated tumors, and large and small cell neuroendocrine carcinomas, constituting poorly differentiated tumors [4] [5]. Thus, neuroendocrine carcinomas represent a variety of neoplasms, both due to different anatomical sites and various histological subtypes. Regarding the vulva, a less common site for gynecological malignancy, neuroendocrine carcinoma can be subdivided into Merkel cells, small, and large cells [6] [7]. Small cell neuroendocrine carcinoma mainly affects the lungs, with a 5% extrapulmonary incidence. Within the reproductive tract, it predominantly affects the uterine cervix, making vulvar involvement even rarer.

Regarding symptoms, it resembles the presentation of any tumor in the gynecological tract. Among reported cases of small cell neuroendocrine vulvar carcinoma, the only common symptom among patients was the presence of a progressively enlarging vulvar nodule, as presented by our patient. Additionally, pain, itching, swelling, unifocal plaques, bleeding, and inguinal lymphadenopathies can be found. Some patients with gynecological neuroendocrine carcinoma present altered cervical cytology, a fact not identified in our patient [2] [8] [9].

Risk factors for vulvar carcinoma are well established, such as cervical or vulvar intraepithelial neoplasia, history of cervical cancer, smoking, lichen sclerosis

in the vulva, immunodeficiency syndrome, and Northern European ancestry [7]. However, despite the first reported case of small cell neuroendocrine vulvar carcinoma dating back to 1981, no definitive risk factors have been identified for this disease [2]. Despite a similar clinical behavior, it is known that gynecological small cell carcinomas present distinct risk factors from each other. For instance, cervical neuroendocrine carcinoma is associated with HPV 18 in more than 90% of cases [4] [10]. Pulmonary small cell carcinoma predominantly linked to active smoking, similar to cervical small cell carcinoma, yet this link isn't established for gynecological small cell carcinoma. Nevertheless, both pulmonary and gynecological small cell carcinomas present similar histopathological characteristics, determining similar therapeutic approaches. Nonetheless, it is unknown whether they share identical genetic alterations, necessitating genomic investigation for better diagnostic elucidation of gynecological small cell carcinoma [10].

The diagnosis of vulvar carcinoma starts with a pelvic physical examination to identify the primary manifestation: nodules. Additionally, colposcopy can be performed to identify non-visualized subclinical lesions. In the presence of significant lesions, a biopsy should be performed for pathological determination. The exact diagnostic investigation follows WHO criteria, involving anatomopathological examination and confirmation via immunohistochemistry [7]. The anatomopathological examination demonstrates undifferentiated tumoral proliferation of small, basophilic oval cells arranged in a sheet, trabecular, nested, or pseudorosette pattern with the presence of numerous 100 to 200 μm neurosecretory granules with perinuclear microfilaments, scant cytoplasm with undefined boundaries, oval and hyperchromatic nuclei, with rare nucleoli. Intense mitotic activity is accompanied by crushing artifacts, nuclear fragmentation, and necrosis, as seen in our patient. The detection of neurosecretory granules is an unequivocal histological indicator for proving neuroendocrine differentiation. However, microscopic examination alone is complex, requiring immunohistochemistry support for confirmation in most cases [7].

Immunohistochemistry shows positivity in the expression of at least one of the neuroendocrine markers: synaptophysin, chromogranin-A, neuron-specific enolase, CD56, CD57, protein gene product 9.5, and vesicle protein. However, chromogranin-A, synaptophysin, and CD56 are most commonly used for neuroendocrine differentiation, especially chromogranin-A, allowing for precise diagnosis [2] [8]. Identifying markers of neuroendocrine histogenesis is essential to exclude important differential diagnoses, such as Merkel cell cancers [8]. Although it is a skin neuroendocrine carcinoma, the CK20 marker is identified in 90% of cases, unlike small cell neuroendocrine carcinomas, where TTF-1 is found in 30% of cases [10]. Additionally, the misdiagnosis of Bartholin gland cyst or abscess can delay recognition of this aggressive malignancy [11].

The small cell neuroendocrine carcinoma has an extremely unfavorable prognosis, irrespective of its location. Regarding the reproductive tract, there are few reports of short-term survival. However, vulvar involvement stands out due to its usual lymphatic and vascular invasion, leading to local-regional recurrences

and early metastases despite treatment. Metastases were primarily identified in inguinal and para-aortic lymph nodes, lungs, brain, and bone marrow. Nevertheless, the prognosis might be associated with the tumor's extent and stage [2] [8]. Concerning staging, thoraco-abdomino-pelvic tomography, cerebral tomography, as well as osteo-medullary biopsy, can be requested [9].

After staging, treatment should be planned in conjunction with the patient due to the lack of consensus regarding appropriate therapy, given the rarity of the presented condition. However, locoregional surgical treatment, either through extensive surgery (the option used in our patient) or excision with healthy margins greater than 5 mm, and adjuvant radiotherapy constitute the therapeutic basis for cases reported in the literature [2]. Pelvic inguinal radiotherapy involves doses of 50 to 60 Gy. Despite this, local treatment in small cell vulvar neuroendocrine carcinoma hasn't proven effective in controlling the disease. Therefore, systemic treatment with chemotherapy has been gaining traction as an attempt to improve patient survival, with preferred regimens being etoposide-cisplatin or doxorubicin-cyclophosphamide-vincristine [2] [8]. Due to the small number of reported cases, inferring the long-term effectiveness of systemic treatment is challenging, requiring increasingly genomic research for the discovery of new markers and molecular aberrations useful in treatment.

4. Conclusion

Small cell neuroendocrine carcinoma of the vulva remains a poorly studied disease, posing a diagnostic challenge for gynecologists and pathologists [3]. Due to the absence of pathognomonic signs and symptoms, the diagnostic course heavily relies on anatomopathological examination, confirmed through immunohistochemistry [6]. The urgent need to develop standardized guidelines and management strategies is hindered by the rarity of cases [3].

Conflicts of Interest

The authors declare no conflicts of interest regarding the publication of this paper.

References

- [1] Rindi, G., Mete, O., Uccella, S. *et al.* (2022) Overview of the 2022 WHO Classification of Neuroendocrine Neoplasms. *Endocrine Pathology*, **33**, 115-154. <https://doi.org/10.1007/s12022-022-09708-2>
- [2] Bouhafa, T., Kanab, R., Bouayed, N. *et al.* (2014) Carcinoma neuroendocrine à petites cellules de la vulve. *Gynécologie Obstétrique & Fertilité*, **42**, 877-879. <https://doi.org/10.1016/j.gyobfe.2014.07.032>
- [3] Yin, Y., Han, L., Ruan, J. and Zheng, A. (2022) Vulvar Neuroendocrine Carcinoma: A Case Report and Literature Review. *Gynecology and Pelvic Medicine*, **5**, 30. <https://doi.org/10.21037/gpm-21-62>
- [4] Chun, Y. (2015) Neuroendocrine Tumors of the Female Reproductive Tract: A Literature Review. *Journal of Pathology and Translational Medicine*, **49**, 450-461.

- <https://doi.org/10.4132/jptm.2015.09.20>
- [5] Gardner, G., Reidy-Lagunes, D. and Gehrig, P. (2011) Neuroendocrine Tumors of the Gynecologic Tract: A Society of Gynecologic Oncology (SGO) Clinical Document. *Gynecologic Oncology*, **122**, 190-198. <https://doi.org/10.1016/j.ygyno.2011.04.011>
- [6] Georgescu, T., Bohiltea, R., Munteanu, O., *et al.* (2021) Emerging Therapeutic Concepts and Latest Diagnostic Advancements Regarding Neuroendocrine Tumors of the Gynecologic Tract. *Medicina (Kaunas)*, **57**, 1338. <https://doi.org/10.3390/medicina57121338>
- [7] UpToDate. (2023) Vulvar Cancer: Epidemiology, Diagnosis, Histopathology, and Treatment. <https://www.uptodate.com/contents/vulvar-cancer-epidemiology-diagnosis-histopathology-and-treatment>
- [8] Correia, A., Branco, E.C., *et al.* (2017) Small Cell Carcinoma of the Vulva: Case Report. *Clinics and Practice*, **7**, Article 918. <https://doi.org/10.4081/cp.2017.918>
- [9] Mharrech, A., Benchakroun, N., Tawfiq, N., *et al.* (2006) Le carcinome à petites cellules de la vulve: À propos d'un cas avec revue de la littérature, *Journal de Gynécologie Obstétrique et Biologie de la Reproduction*, **35**, 834-837. [https://doi.org/10.1016/S0368-2315\(06\)76489-4](https://doi.org/10.1016/S0368-2315(06)76489-4)
- [10] Atienza-Amores, M. and Guerini-Rocco, E. (2014) Small Cell Carcinoma of the Gynecologic Tract: A Multifaceted Spectrum of Lesions. *Gynecologic Oncology*, **134**, 410-418. <https://doi.org/10.1016/j.ygyno.2014.05.017>
- [11] Han, L., Zheng, A. and Chen, Y. (2021) A Rare Case of Primary Small Cell Neuroendocrine Carcinoma of the Bartholin Gland. *International Journal of Gynecology & Obstetrics*, **155**, 539-540. <https://doi.org/10.1002/ijgo.13782>