

# The Use of Autologous Tibia Strut Graft to Enhance Bone Healing of an Infected Long-Bone Nonunion

Reynders-Frederix Peter<sup>1\*</sup>, Schioppa Dragos<sup>1</sup>, Reynders-Frederix Cristina<sup>2</sup>, DeGuio Giulia<sup>1</sup>

<sup>1</sup>Department of Orthopedic Surgery, Brugmann University Hospital, Brussels, Belgium

<sup>2</sup>Department of Revalidation & Physiotherapy, Saint-Pierre University Hospital, Brussels, Belgium

Email: \*reynders52@hotmail.com

**How to cite this paper:** Peter, R.-F., Dragos, S., Cristina, R.-F. and Giulia, D. (2023) The Use of Autologous Tibia Strut Graft to Enhance Bone Healing of an Infected Long-Bone Nonunion. *Open Journal of Orthopedics*, 13, 525-542.

<https://doi.org/10.4236/ojo.2023.1312051>

**Received:** November 24, 2023

**Accepted:** December 26, 2023

**Published:** December 29, 2023

Copyright © 2023 by author(s) and Scientific Research Publishing Inc.

This work is licensed under the Creative Commons Attribution International License (CC BY 4.0).

<http://creativecommons.org/licenses/by/4.0/>



Open Access

## Abstract

We treated five patients with an infected non-union of the femur and tibia with autologous tibia strut grafts. All patients had bone defects ranging from three to nine centimeters. Three patients suffered for more than seven years from chronic osteitis. Our objective was to describe this grafting technique and its results. We focussed on healing time, postoperative complications and functional recovery. We retrospectively studied five patients with an infected non-union of the lower limb who had undergone previous surgeries to overcome the bone healing problem. In this group of patients, we had four femur non-union and one tibia non-union. All of them had a previous infection episode, in which medical and surgical therapy was needed. Of the participants, three were men, and two were females with a mean age of 43.3 years (28 - 55).

## Keywords

Pseudarthrosis, Bone Infection, Bone Grafting

## 1. Introduction

The treatment of an infected lower limb non-union remains a complex therapeutic problem. Several techniques have been developed over time to address it.

All these techniques have their positives and negatives. Good results were obtained when using the following: structural allografts [1] [2], Masquelet's technique [3], Ilizarov distraction osteogenesis and compression [4] [5] [6] [7], free vascularised fibula graft [8], changing the biomechanics of the fracture site [9] [10] [11] [12] and recombinant BMP 2 and 7 [13].

These patients often have multiple orthopaedic ailments, such as deep bone

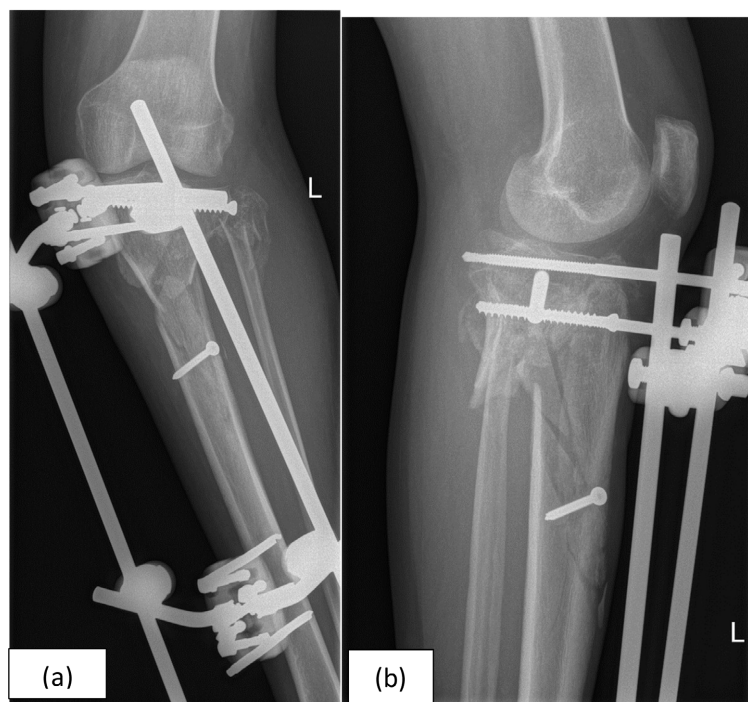
infections, bone defects and extensive scarring with reduced local bone vascularisation, regardless of whether these ailments are combined with systemic influences that negatively affect the healing process. The influence of diabetes, tobacco abuse, corticoid use, social deprivation and social isolation negatively affects bone healing [14].

## 2. Procuring the Cortical Graft

After preparing the receptor side, the autologous cortical tibial graft is taken from the anterior medial surface of the contralateral healthy tibia. The size of the defect determines the length of bone required; however, at least 6 cm of proximal and 5 cm of distal tibia should be left behind at the donor site. The graft is outlined, and drill holes with a 3.2 mm drill are made. The holes are joined together by using an oscillating saw. Cooling of the saw blade with physiologic serum is done to avoid unnecessary heat necrosis of the bone. With the chisel, the graft, with as much bone marrow as possible, is carefully lifted out of the donor bed and immediately implanted in the receptor bed. The donor site tibial bone defect is filled with a cortical tibia allograft. In two cases a press fit between the graft and the donor site was obtained. In these cases, no screws were used.

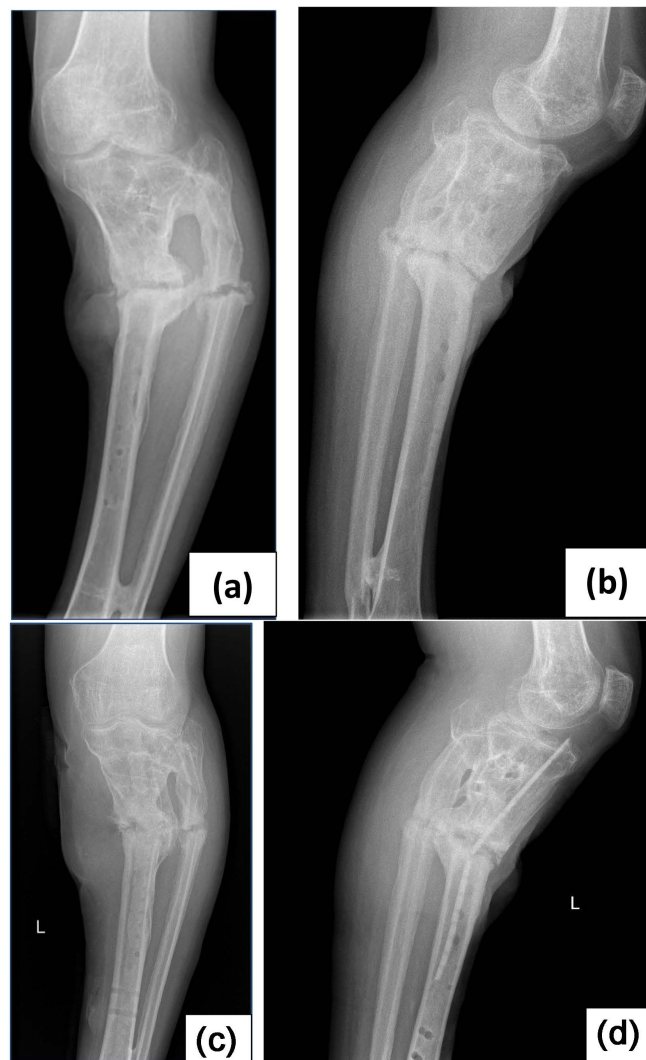
### 2.1. Case 1

A 52-year-old man was assaulted and sustained a displaced open proximal tibia fracture. His condition was treated by antibiotics, debridement and bone fixation with an external fixator (**Figure 1(a)** & **Figure 1(b)**). An infected malunion in



**Figure 1.** Case no. 1. Initial radiographs after trauma with suboptimal placement of an external fixation and percutaneous placed screws.

valgus occurred. The deep bone infection with *Staphylococcus aureus* and fistula formation was treated intermittently with oral antibiotics for three months; ciprofloxacin 500 mg twice a day together with 160 mg trimethoprim/800mg sulfamethoxazol/once a day. After a minor trauma, a new fracture occurred seven years after the initial incident (**Figure 2(a)** & **Figure 2(b)**). Spontaneous healing in a plaster cast was not possible because of the renewed deep bone infection with fistula formation and soiling of the plaster cast. Masquelet's technique was used to heal the infected non-union, no bone healing could be obtained. The infected nonunion was accepted by the patient and treated with oral antibiotic administration; ciprofloxacin 500 mg twice a day together with 160 mg trimethoprim/800mg sulfamethoxazol/once a day. Eventually, with long-lasting antibiotic therapy, the deep bone infection came under control, as there were no external infection signs. Because of the increasing varus of the tibia nonunion,



**Figure 2.** ((a), (b)) Case no. 1. Radiographs eleven years after the initial fracture. Mobile pseudarthrosis with varus deformity. ((c), (d)) Case no. 1. Radiographs two years after the removal of the external fixator. On profile, the broken endosteal located graft is clearly visible.

another attempt was made to achieve bone healing, this time with a biological nail (autologous strut graft) (**Figure 2(c)** & **Figure 2(d)**). The external tissue scarring was so extensive that a classical surgical approach to the fracture site proved impossible.

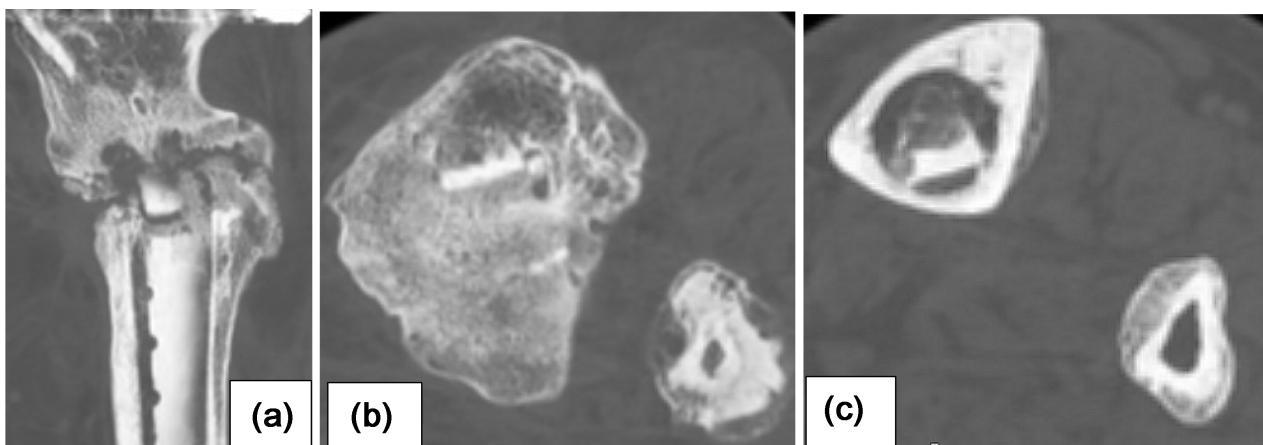
#### Surgical Technique:

First, a fibula osteotomy was performed to obtain a better alignment of the lower leg. Then, an autologous cortical tibia graft, taken from the other tibia, was inserted intramedullary via a suprapatellar approach (**Figure 3(a)** & **Figure 3(b)**). By this method, a one inch transverse incision is made 4 cm proximal from the patella. The quadriceps aponeurosis is split and with a long curved scissor the soft spot of the proximal tibia (area intercondylaris) is located. With a pointed hand riemer of 6 mm width, the cortical bone is perforated and the autologous tibia strut graft is carefully hamered in the intramedullary canal. Because of pliability of the tibia graft the Herzog curve of the proximal tibia is easily passed.

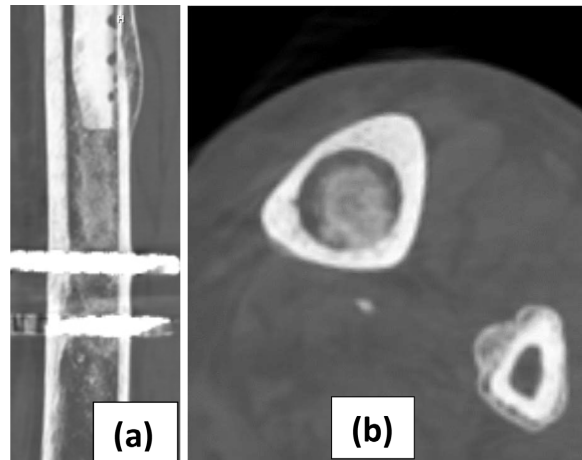
The tibia was then stabilised with an external fixator. Patient was not compliant and started immediate full weight bearing. One week after surgery, the cortical bone graft broke at the level of Herzog's angle. After one year, there was sufficient endosteal bone formation around the intramedullary graft, and the fixator external could be taken off (**Figures 3(a)-(c)** and **Figure 4(a)** & **Figure 4(b)** and **Figure 5(a)** & **Figure 5(b)**). The patient is now walking with a cane for equilibrium reasons. Knee bending is 115° for an extension lag of 5°.

## 2.2. Case 2

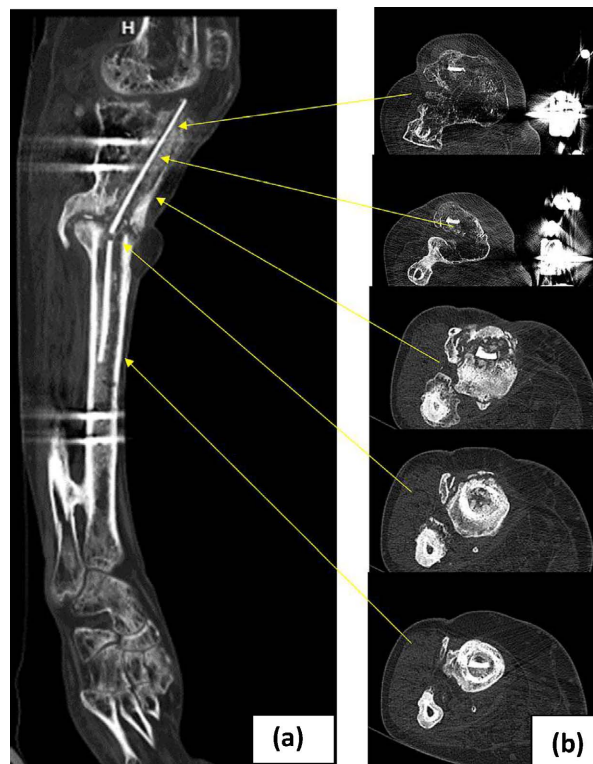
A 55-year-old man, who smokes heavily, received a total knee prosthesis for severe gonarthrosis (**Figure 6**). Unfortunately, a deep infection occurred. The patient was given antibiotics as the only treatment because he refused further surgery. He sought surgical advice five years after the initial placement of the knee prosthesis. A bone scan with marked white blood cells showed profound osteomyelitis of the distal femur and proximal tibia. A cemented spacer was



**Figure 3.** (a)-(c) Case no. 1. CT images showing the endosteal bone formation around the broken cortical graft.



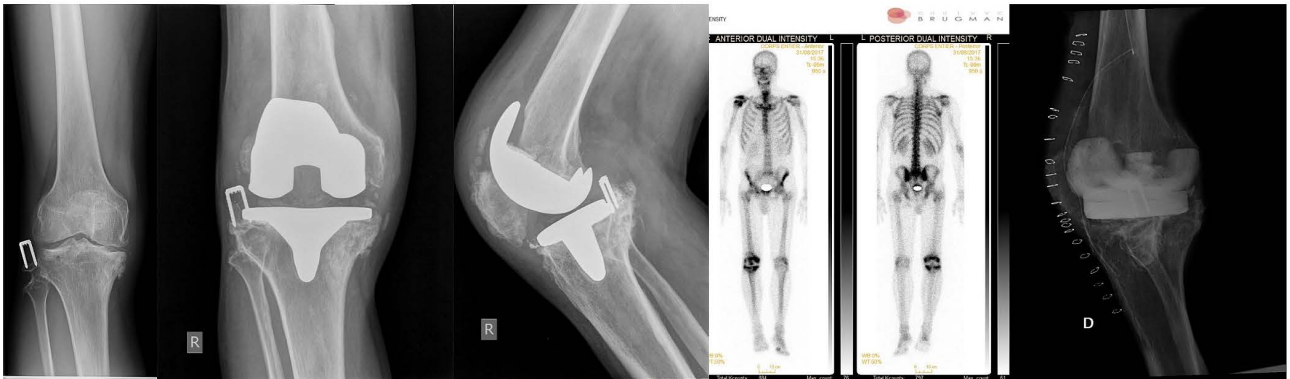**Figure 4.** Case no. 1. CT images picturing the extensive endosteal bone formation underneath the autologous cortical graft.



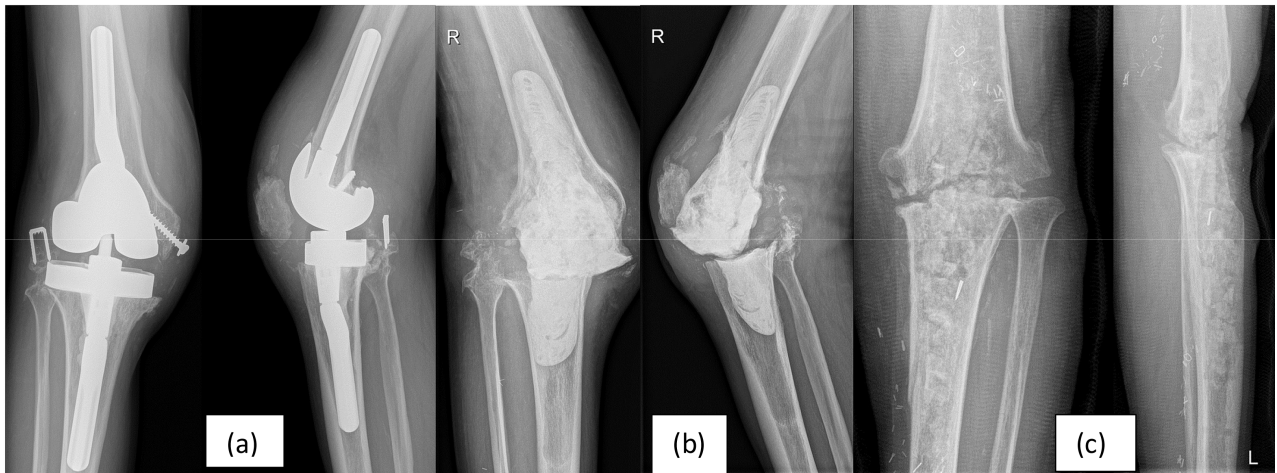
**Figure 5.** Case no. 1. CT scan overview of the autologous strut graft and the endosteal ingrowth at different levels.

used and then changed after three months by a hinged knee prosthesis (**Figures 7(a)-(c)**). Within a year, the deep infection reoccurred, necessitating the removal of the knee prosthesis. An attempt to perform an arthrodesis of his knee with a bridging external fixator failed (**Figure 7(c)**). After one year with an external fixator, the bone union did not occur, and a cortical autologous strut graft was placed anteriorly, spanning the arthrodesis site. The graft was fixed with two 4.5 mm cortical screws, one above and one below the arthrodesis site.

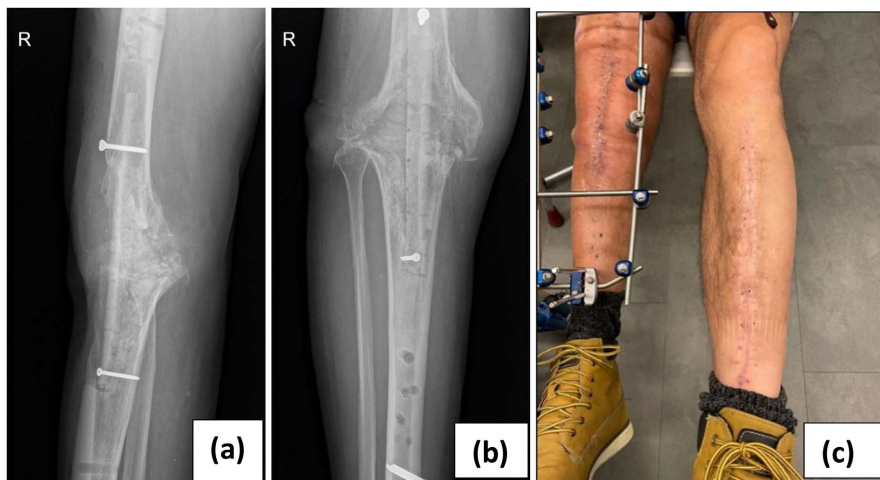
A new spanning external fixator was placed to secure the knee arthrodesis (**Figures 8(a)-(c)**).



**Figure 6.** Case no. 2. Radiographs and white blood cell bone scan of an infected prosthesis and spacer (PMMA) placement.



**Figure 7.** Case no. 2. Radiographs after the revision of the knee prosthesis **Figure 2(a)**, removal because of deep infection and placement of a PMMA spacer **Figure 2(b)** and one year after external fixation.



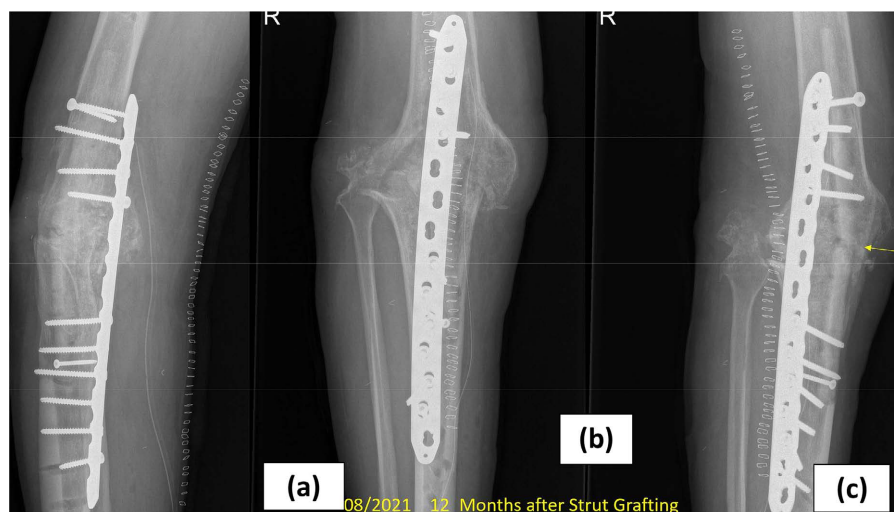**Figure 8.** ((a), (b)) Case no. 2. Radiographs showing the anterior placed grafted spanning the non-union side and fixed with two 4.5 mm cortical screws and spanning external fixator; (c) Case no. 2. Clinical views of both lower legs with the surgical scar on the left tibia for the graft procurement.

Three months after the last surgery, the patient fell on the street, breaking his strut graft with a skin laceration in front of his knee. The skin abrasion became infected. Antibiotics were given, and the anteriorly located wound was debrided. After six weeks, the wound became clean, and a posteriorly placed large fragment femoral plate was placed covering the former knee joint (**Figures 9(a)-(c)**). This patient had poorly vascularised, scarred-down and immobile tissue in the front of his knee. No attempt was made to remove the anteriorly located broken cortical strut graft. At the same time, a cortical strip of bone from the posterior side of the proximal tibia was taken and shifted proximally to bridge the fracture site. Removal of dead bone tissue was done with the same procedure. After the last surgery, the anteriorly located infected wound healed. The anteriorly (broken) and posteriorly cortical bone grafts were integrated after one year. Full weight-bearing activities were possible at that time.

Two years later, the posteriorly located femur plate broke (**Figure 10(a)**). The broken implant was replaced by two cannulated crossing screws of 7.3 mm screws to secure the former knee joint together with a solid femur allograft which spans the non-union side. This graft was secured to the femur with six 4.5 mm cortical screws: three screws above and three screws below the non-union site (**Figure 10(b)**). It took another two years post-surgery to see the bony union and peripheral integration of the allograft. Four years after the allograft strut graft placement, the patient is pain free at his knee and walks with one cane. He developed a severe bilateral omarthrosis of both shoulders because of the long standing use of his elbow crutches.

### 2.3. Case 3

A 28-year-old female was involved in a car crash. An isolated closed femur fracture was diagnosed and treated with open femoral nailing and cerclage wiring. One year later, there was a painful mobile pseudarthrosis with a leg shortening



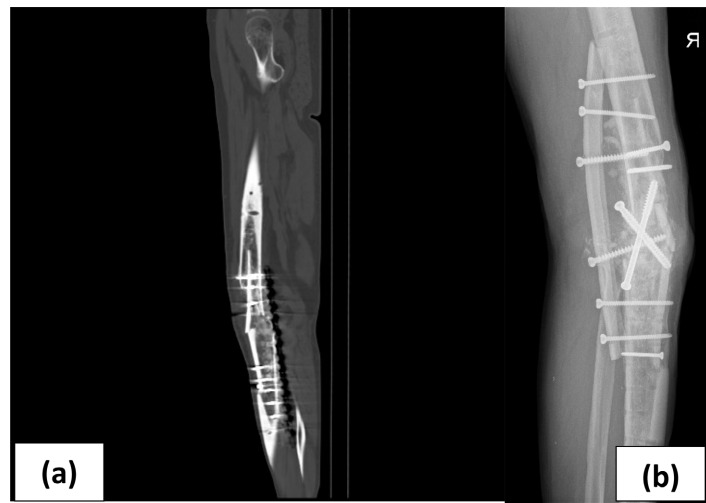**Figure 9.** Case no. 2. Radiographs of the posterior located femur plate and broken, anteriorly placed cortical tibial graft.

of three centimetres on the same site (**Figure 11(a)** & **Figure 11(b)**).

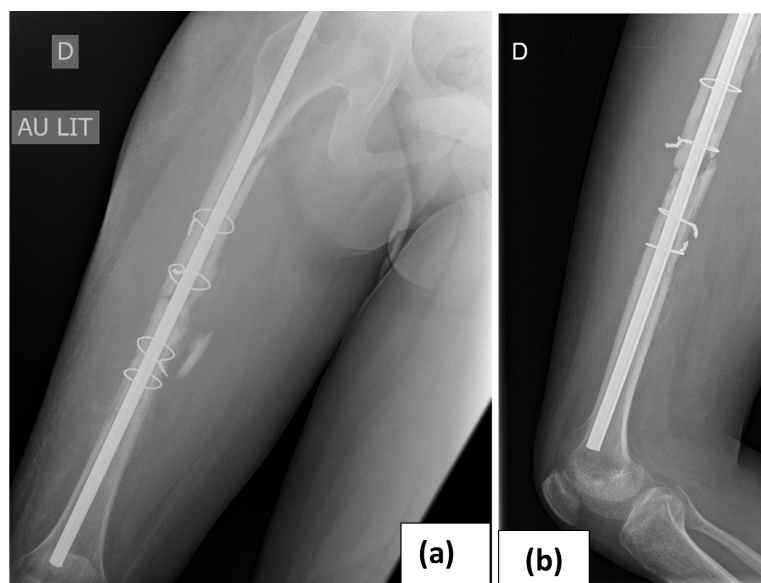
She did not experience any infection after her initial treatment. The clover leaf nail was replaced by a locking femoral nail. At the same time, an allograft was placed at the lateral side of the femur, bridging the non-union fracture side (**Figure 12**).

Unfortunately, the deep tissue samples came back positive for *Enterobacter cloacae*, *Streptococcus oralis* and *Escherichia coli*. All the implants and allograft were removed, and her leg was put in a spanning external fixator, spanning her hip as well as her knee joint (**Figures 13(a)-(c)**).

The patient wore the external fixator for three months while receiving intravenous antibiotics.

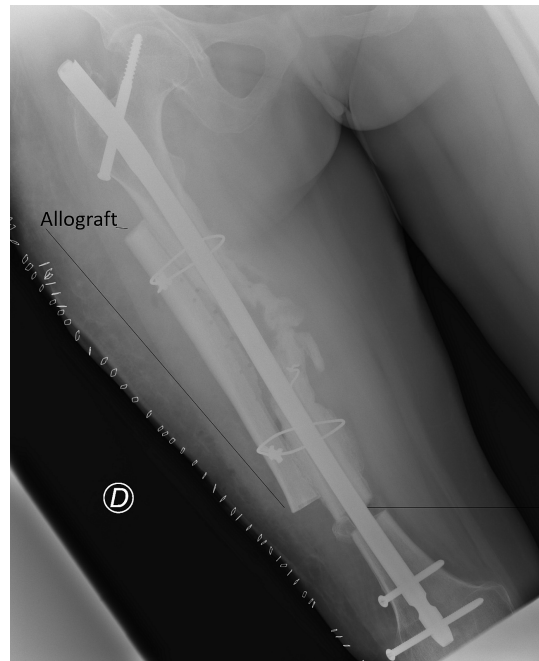


**Figure 10.** (a) Case no. 2. CT scan depicting the broken cortical graft and posterior located femur plate. (b) Case no. 2 Radiograph after the broken plate removal and posterior strut allograft placement. Two crossing 7.3 mm crossing screws were used to stabilise the knee joint.

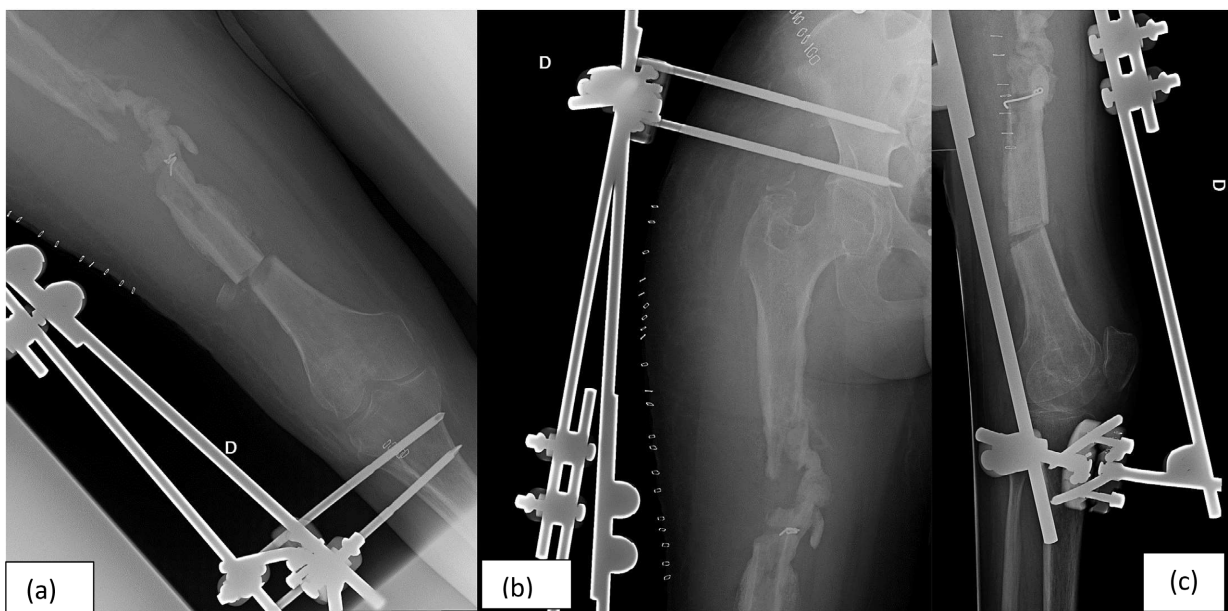


**Figure 11.** Case no. 3. Radiographs, two years after open nailing of a closed femur fracture.



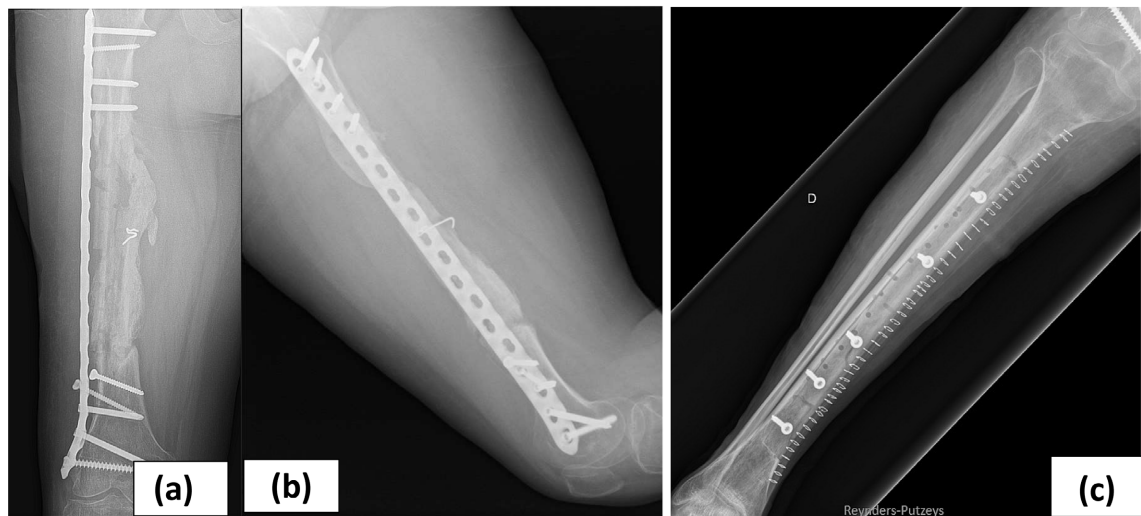

**Figure 12.** Case no. 3. Radiograph after the first revision surgery. Locking nail together with a lateral orientated allograft en lengthening osteotomy, distal femur.

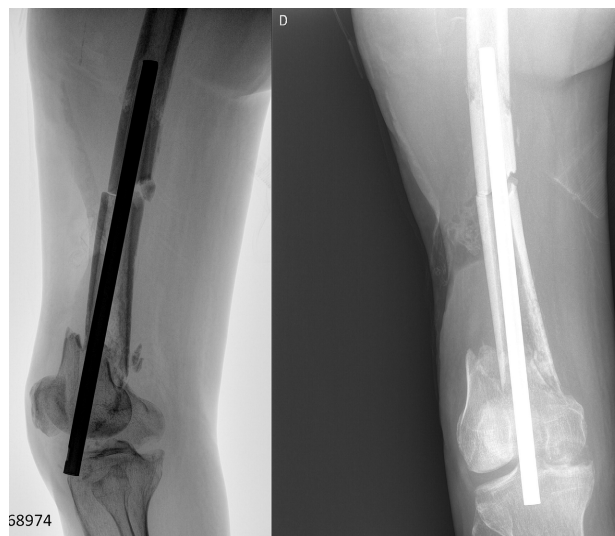


**Figure 13.** Case no. 3. Radiographs after removal of all implants. Placement of a pelvo-tibial spanning external fixator.

After this period, the external fixator was removed and replaced by a 4.5 mm locking plate, which protected a 25 cm long autologous tibia on-lay graft (**Figure 14(a)** & **Figure 14(b)**). The contralateral tibia served as the donor side. Full weight-bearing activities were possible six months after the last surgery. During this period, she received oral antibiotics (ciprofloxacin 500 mg twice a day together with 160 mg trimethoprim/800mg sulfamethoxazol/once a day). Full integration of the cortical graft was visible one year after the last surgery. Five years



**Figure 14.** ((a), (b)) Case no. 3. Radiographs, two years after cortical bone graft transplantation; (c) Case no. 3. Radiograph of the tibial donor site at two years after surgery. Allograft is held in the donor defect with 4.5 mm cortical screws.



**Figure 15.** Case no. 4. Situation after suboptimal placement of a cloverleaf nail of the nail protruding into the knee joint.

after her last surgery, she remains infection free but does walk with a slight limp. She has a shortening of 2.5 cm, which she compensates with inlay shoe soles. Her knee flexion is 110° for a full extension and her hip function is normal. Her donor tibia site is pain-free on full weight bearing with complete peripheral integration of the allograft (**Figure 14(c)**).

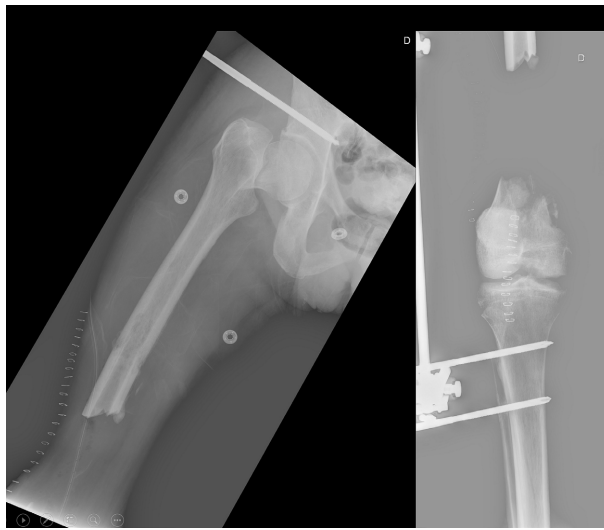
#### 2.4. Case 4

A 54-year-old man was involved in a motorcycle accident abroad. He sustained an open bifocal femur fracture and a closed base-cervical femur fracture on the same side—the cloverleaf nail protracted from his knee when he returned to Europe (**Figure 15**). Pus was pouring out the level of the bone segment and his

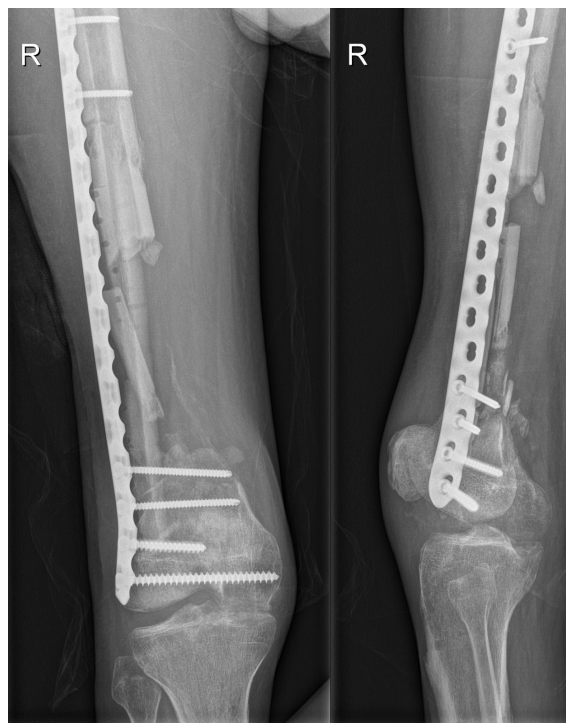knee joint. The intertrochanteric fracture went unnoticed and was not stabilised. A mixed flora of *Escherichia coli*, *Actinobacteria baumannii* and a multiresistant *Proteus mirabilis* was found after deep tissue sampling.

The nail and bone sequester were removed, and his leg was placed in an external fixator, spanning his hip and knee (**Figure 16**).

After three months, an autologous tibial cortical graft was placed inside the bone gap, and the bone was stabilised with a femoral plate (**Figure 17**). Reinfection then

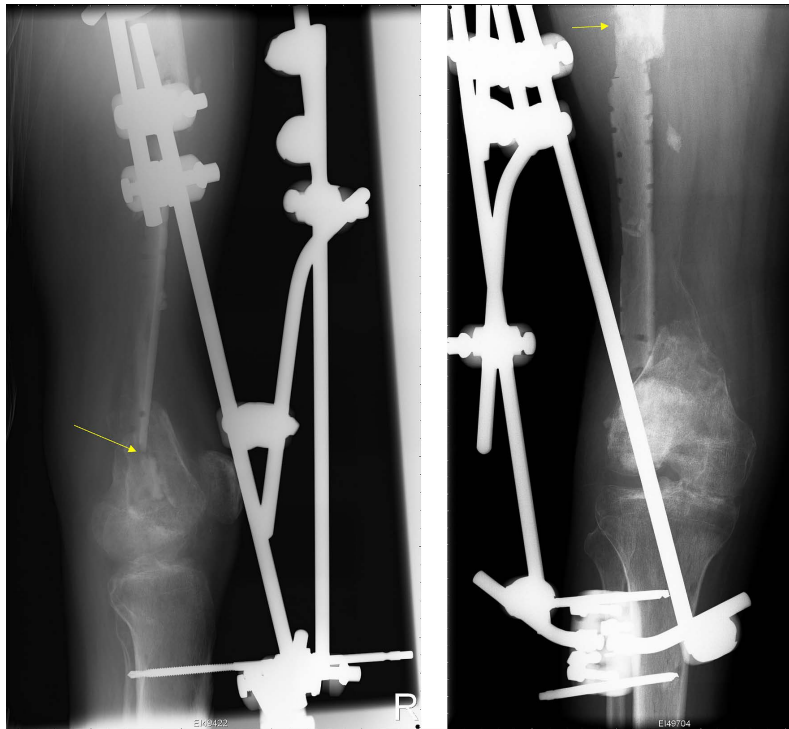


**Figure 16.** Case no. 4. Radiographs after removing the intramedullary nail. The infected femur sequester was also removed.

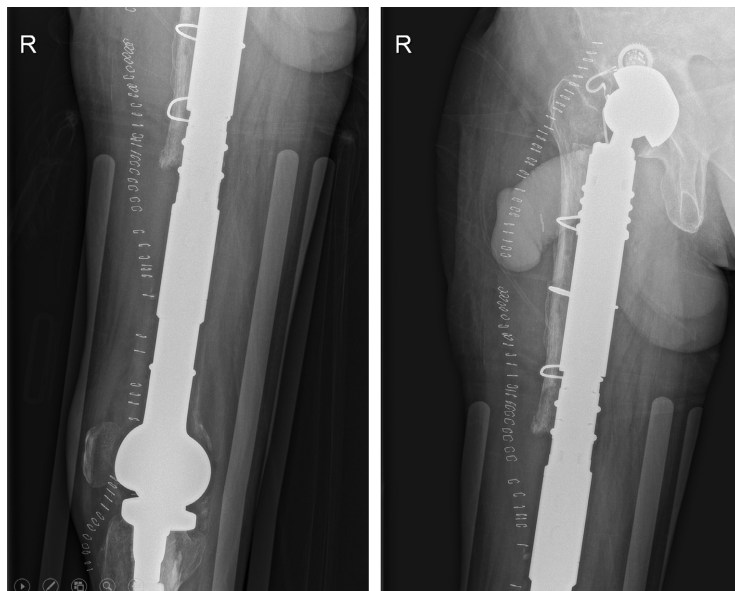


**Figure 17.** Case no. 4. Radiographs immediately after placement of the autologous tibial strut graft and femurplate.

occurred, which was treated with antibiotics and removal of the hard ware. The femur was stabilized by an external fixator. Spontaneous breakage of the cortical graft was noted two months after the placement (**Figure 18**). An oncological resection of the infected bone and soft tissue was carried out, and a mega prosthesis was done, including his hip and knee joints, at another institution (**Figure 19**).



**Figure 18.** Case no. 4. Breakage of the tibia graft after plate removal (yellow arrow).

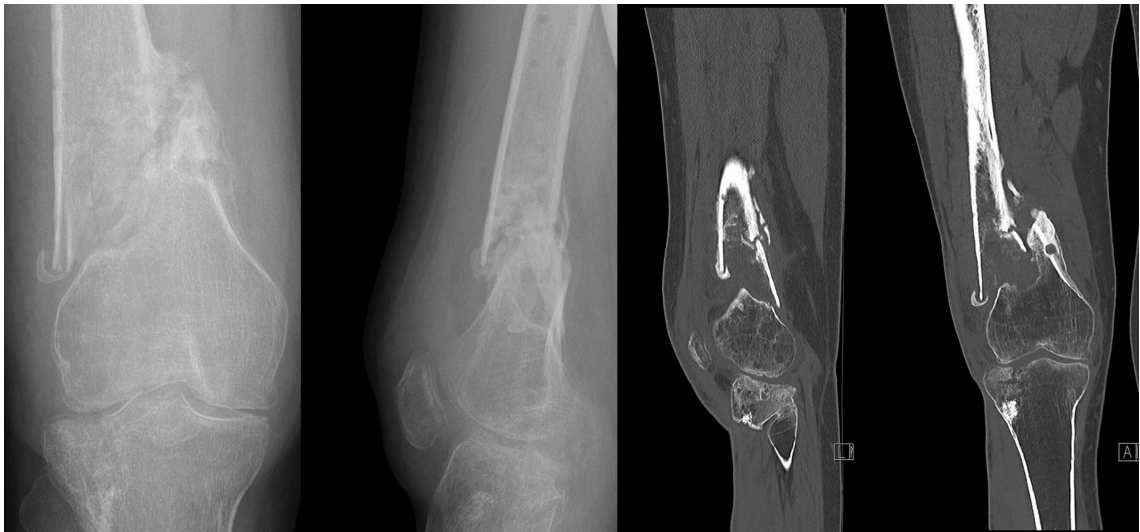

**Figure 19.** Case no. 4. Oncological type of bone resection of all infected parts and placement of a tumour prosthesis in a second time.

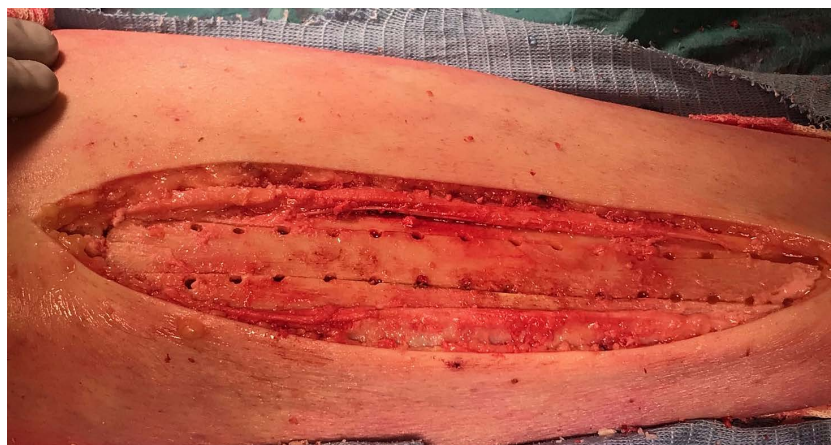## 2.5. Case 5

A 28-year-old man fell on slippery ice and broke the distal third of his femur. It was a closed fracture. A locked plate (LISS DePuy-Synthes) was used to stabilise the distal femur fracture. Unfortunately, the plate had to be removed two months later because of a deep infection (*Staphylococcus aureus*). The femoral fracture was stabilised by an external fixator, and antibiotics were given. After eight months, the external fixator was removed because of an ongoing pin tract infection (**Figure 20**). Thirteen months after the initial trauma, revision surgery was performed using a contralateral autologous cortical tibia graft.

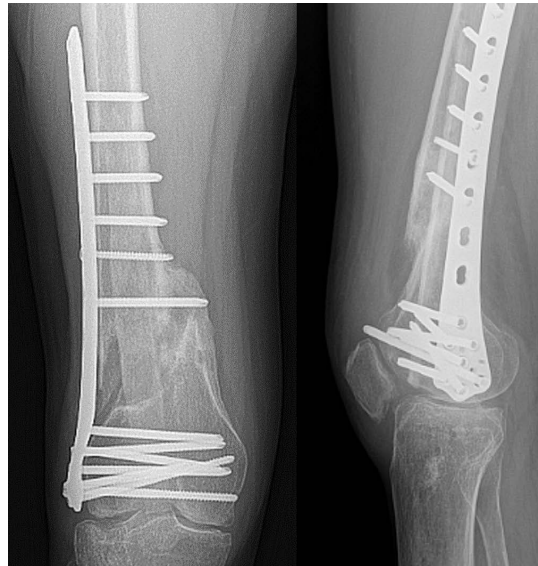
The cortical strut graft (**Figure 21**) was brought into the medullary cavity by the retrograde way (from his knee on) and stabilised by a lateral placed locked plate. Six months after the last surgery, graft integration was also seen with fracture healing (**Figure 22**). However, some function of his knee was lost: 20° of flexion. At his follow up at three years, no infection was seen. The patient refused further surgery. He now walks with a cane.



**Figure 20.** Case no. 5. Radiographs of a nonunion of the distal femur.



**Figure 21.** Case no. 5. Prelevation of the autologous cortical graft by drilling technique.



**Figure 22.** Case no. 5. Radiographs three years after the initial trauma.

### 3. Discussion

In these five patients, an autologous tibial strut graft was used to enhance bone healing. Autologous cortical grafts are notorious for their slow integration in the surrounding bone tissue of the host when compared to autologous cancellous bone grafts. Cortical bone is dense and contains less than 10% soft tissue. Cancellous bone is more porous and interspersed between bone marrow, which represents more than 75% of its volume. Cancellous bone is four times more active than cortical bone [15].

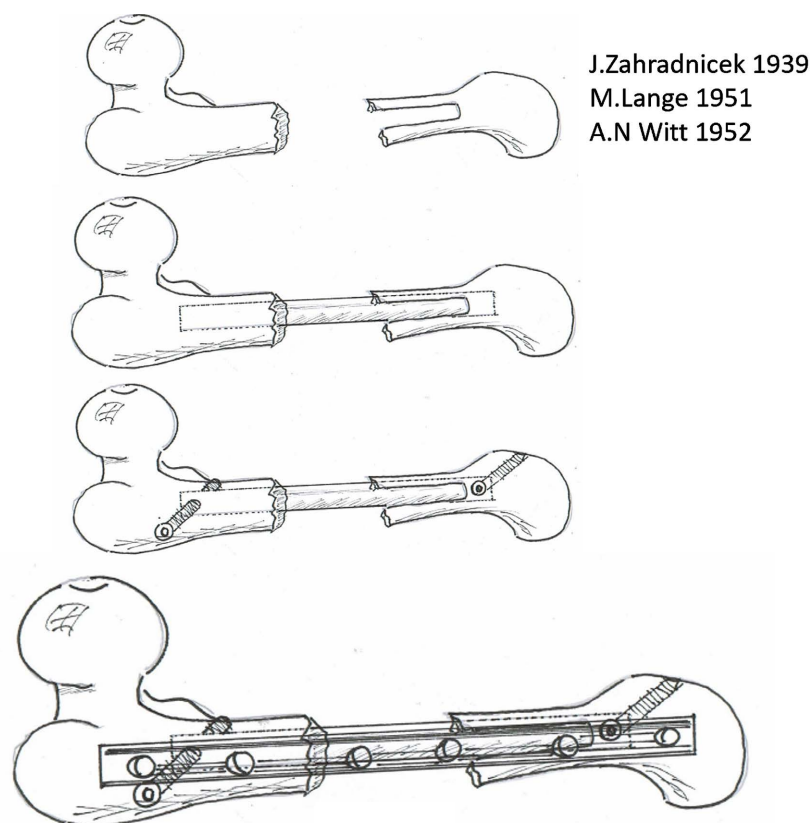
The primary healing mechanism of autogenous cortical bone grafts is osteoconductive (scaffolding). Autologous cortical bone has nearly no biologic active cells (fewer osteogenic properties) compared to cancellous bone.

Cortical bone is less porous and has less surface area and less cellular matrix than cancellous bone. Therefore, cortical bone grafts take longer to revascularise. Cortical bone grafts is a good choice when there is need to span a bone defect. Cortical grafts need to be resorbed by osteoclasts and progressively replaced by mesenchymal cells and eventually new viable bone in a process called creeping substitution, which can take many years. Fatigue fractures of these grafts are seen in 25% of the cases [16].

The surgical technique of using autologous cortical strut graft was popularised by the Slovak surgeon J. Zahradnicek in 1939, by M. Lange in 1951 and by A. N. Witt in 1952 [17] (**Figure 23**). Probably due to the Iron Curtain, which divided Europe in two after World War II, this technique found little acceptance in Western European countries.

In this series of five patients, this technique was used to enhance bone healing by biological means while increasing the mechanical support of the nonunion.

In all the patients, multiple surgical interventions were needed because of recurrent deep bone infections.



**Figure 23.** Case no. 5. Draft explaining the technique used. First, a slot is made in the bone (distally or proximally) then the strut graft is placed inside the bone and secured with two screws and on top of that a plate.

In three cases, a structural failure of the cortical graft was seen. In these three cases, the stability of the bone construct was given by an external fixator. Mechanical stability, good vascularisation and intimate contact between the graft and the recipient bone are essential [17]. In one case, the mechanical failure of the graft together with an uncontrollable bone infection was the cause of a total failure. An oncological resection of all infected bone was necessary as was the placement of a tumour prosthesis on his hip, femur and knee joint.

In the two cases with the intramedullary placement of the cortical graft, there was an intense endosteal integration of the cortical graft. In part, endo-medullary reaming could possibly explain this endosteal bone formation. But this is not in concordance with endosteal reaming in trauma cases of long bones, where such an endosteal bone formation is rarely seen. Nor is this endosteal bone formation seen after harvesting intra-medullary bone graft by the Reamer Irrigator Aspirator system (RIA: DePuy-Synthes) [4] [18].

This robust endosteal reaction around the graft was seen early in the healing process, which contradicts the creeping substitution theory as a mechanism for graft integration. In one of these two cases, the broken graft healed with endosteal cancellous bone formation. The continuity of the cortex of the broken side of the graft was however not restored.

The two weaknesses of this paper are the lack of a control group and its small size. The ideal approach would be to compare this technique with the use of cortical strut allografts. However, the described lesions are rare and heterogeneous in nature, which makes comparison with other treatment protocols difficult.

#### 4. Conclusions

The use of an autologous cortical strut graft is a possible technique to enhance the biological process of the nonunion healing of a long bone of the lower limb.

All the grafts stabilised with an external fixator failed (fatigue fracture), underlining the importance of a solid stabilisation of the nonunion with a plate. Creeping substitutions is the mechanism for integration and remodelling of the graft when used as an on-lay graft. When the graft is used as a biological nail (endo-medullary position), an early and extensive endo-medullary bone formation is seen around the graft. The latter gives the impression of a different and faster bone integration and remodelling mechanism when placing the cortical graft in the endo-medullary cavity.

#### Ethics Approval

The study was approved by the local ethical committee, CE2023/108 and had been performed in accordance with the ethical standards laid down in the 1964 Declaration of Helsinki and its later amendments, including applicable ethical regulation of the Free University of Brussels, Belgium.

#### Conflicts of Interest

The authors whose names are listed certify that they have no affiliations with or involvement in any organization or entity with any financial interest (such as honoraria, educational grants, membership, employment, consultancies, stock ownership, or other equity interest, and expert testimony or patent-licensing arrangements), or non-financial interest (such as personal or professional relationships, affiliations, knowledge or beliefs) in the subject matter or materials discussed in this manuscript.

#### References

- [1] Dheenadhayadan, J., Devendra, A., Velmurugesan, P., Shanmukha Babu, T., Ramesh, P., Zackariya, M., *et al.* (2022) Reconstruction of Massive Segmental Distal Femoral Metaphyseal Bone Defects after Open Injury. *The Journal of Bone and Joint Surgery*, **104**, 172-180. <https://doi.org/10.2106/JBJS.21.00065>
- [2] Delloye, C., Cornu, O., Druetz, V. and Barbier, O. (2007) Bone Allografts: What They Can Offer and What They Cannot. *The Bone & Joint Journal*, **89-B**, 574-579. <https://doi.org/10.1302/0301-620X.89B5.19039>
- [3] Masquelet, A.C., Fitoussi, F., Begue, T. and Muller, G.P. (2000) Reconstruction of the Long Bones by the Induced Membrane and Spongy Autograft. *Annales de Chirurgie Plastique Esthétique*, **45**, 346-353. (In French)
- [4] Spiegelberg, B., Parratt, T., Dheerendra, S.K., Khan, W.S., Jennings, R. and Marsh,



- D.R. (2010) Ilizarov Principles of Deformity Correction. *The Annals of the Royal College of Surgeons of England*, **92**, 101-105.  
<https://doi.org/10.1308/003588410X12518836439326>
- [5] Ilizarov, G.A. (1989) The Tension-Stress Effect on the Genesis and Growth of Tissues: Part I. The Influence of Stability of Fixation and Soft Tissue Preservation. *Clinical Orthopaedics and Related Research*, **238**, 249-281.  
<https://doi.org/10.1097/00003086-198901000-00038>
- [6] Ilizarov, G.A. (1989) The Tension-Stress Effect on the Genesis and Growth of Tissues: Part II. The Influence of the Rate and Frequency of Distraction. *Clinical Orthopaedics and Related Research*, **239**, 263-285.  
<https://doi.org/10.1097/00003086-198902000-00029>
- [7] Ilizarov, G.A. (1990) Clinical Application of the Tension-Stress Effect for Limb Lengthening. *Clinical Orthopaedics and Related Research*, **250**, 8-26.  
<https://doi.org/10.1097/00003086-199001000-00003>
- [8] Bumbasirevic, M., Stevanovic, M., Bumbasirevic, V., Lesic, A. and Atkinson, H.D.E. (2014) Free Vascularised Fibular Grafts in Orthopaedics. *International Orthopaedics*, **38**, 1277-1282. <https://doi.org/10.1007/s00264-014-2281-6>
- [9] Augat, P., Merk, J., Ignatius, A., Margevicius, K., Bauer, G., Rosenbaum, D., et al. (1996) Early, Full Weightbearing with Flexible Fixation Delays Fracture Healing. *Clinical Orthopaedics and Related Research*, **328**, 194-202.  
<https://doi.org/10.1097/00003086-199607000-00031>
- [10] Glatt, V., Evans, C.H. and Tetsworth, K. (2021) Reverse Dynamisation: A Modern Perspective on Stephan Perren's Strain Theory. *European Cells and Materials*, **41**, 668-679. <https://doi.org/10.22203/eCM.v041a43>
- [11] Panjabi, M.M., White, A.A. and Wolf, J.W. (1979) A Biomechanical Comparison of the Effect of Constant and Cyclic Compression on Fracture Healing in Long Rabbit Bones. *Acta Orthopaedica Scandinavica*, **50**, 653-661.  
<https://doi.org/10.3109/17453677908991288>
- [12] Lanyon, L.E., Hampson, W.G., Goodship, A.E. and Shah, J.S. (1975) Bone Deformation Recorded *in Vivo* from Strain Gauges Attached to the Human Tibial Shaft. *Acta Orthopaedica Scandinavica*, **46**, 256-268.  
<https://doi.org/10.3109/17453677508989216>
- [13] Papanagiotou, M., Dailiana, Z.H., Karachalios, T., Varitimidis, S., Vlychou, M., Hantes, M. and Malizos, K.N. (2015) RhBMP-7 for the Treatment of Non-Union of Fractures of Long Bones. *The Bone & Joint Journal*, **97-B**, 997-1003.  
<https://doi.org/10.1302/0301-620X.97B7.35089>
- [14] Hong, Z., Clever, D.C., Tatman, L.M. and Miller, A.N. (2022) The Effect of Social Deprivation on Fracture Healing and Patient Reported Outcomes following Intramedullary Nailing of Tibial Shaft Fractures. *The Journal of Bone and Joint Surgery*, **104**, 1968-1976. <https://doi.org/10.2106/JBJS.22.00251>
- [15] Monier-Faugere, M.-C. and Malluche, H.H. (1998) Bone Biopsies: A Modern Approach. In: Avioli, L.V. and Krane, S.M., Eds., *Metabolic Bone Disease and Clinically Related Disorders*, 3rd Edition, Elsevier, Amsterdam, 237-273.  
<https://doi.org/10.1016/B978-012068700-8/50009-8>
- [16] Schmidt, A.H. (2021) Autologous Bone Graft: Is It Still the Gold Standard? *Injury*, **52**, S18-S22. <https://doi.org/10.1016/j.injury.2021.01.043>
- [17] Marti, R.K. and van der Werken, C. (2011) Principles: Bone Graft. Autogenous Bone Grafting in the Treatment of Nonunion. In: Marti, R.K. and Kloen, P., Eds., *Concepts and Cases in Nonunion Treatment*, Gero Thieme Verlag, Stuttgart.

<https://doi.org/10.1055/b-0034-86366>

- [18] Jakma, T.S.C., Röling, M.A., Punt, B. and Reynders-Frederix, P. (2014) More Adverse Events than Expected in the Outcome after Use of the Reamer-Irrigator-Aspirator. *European Journal of Trauma and Emergency Surgery*, **40**, 337-341.

<https://doi.org/10.1007/s00068-013-0345-8>