

# Arthroscopic Assessment of Intra-Articular Injury in Patients with Acute Unstable Malleolar Fracture

Noor Mahazrinna Hayadin<sup>1\*</sup>, Yi Hui Foo<sup>2</sup>, Vijay Babu Subramaniam<sup>2</sup>, Mohd Izani Ibrahim<sup>2</sup>, Mohd Asni Alias<sup>3</sup>

<sup>1</sup>Hospital Tuanku Fauziah, Perlis, Malaysia

<sup>2</sup>Hospital Raja Permaisuri Bainun, Perak, Malaysia

<sup>3</sup>Pantai Hospital Manjung, Perak, Malaysia

Email: \*norma\_hsb@yahoo.com

**How to cite this paper:** Hayadin, N.M., Foo, Y.H., Subramaniam, V.B., Ibrahim, M.I. and Alias, M.A. (2020) Arthroscopic Assessment of Intra-Articular Injury in Patients with Acute Unstable Malleolar Fracture. *Open Journal of Orthopedics*, 10, 179-192.

<https://doi.org/10.4236/ojo.2020.108021>

**Received:** July 16, 2020

**Accepted:** August 21, 2020

**Published:** August 24, 2020

Copyright © 2020 by author(s) and Scientific Research Publishing Inc. This work is licensed under the Creative Commons Attribution International License (CC BY 4.0).

<http://creativecommons.org/licenses/by/4.0/>



Open Access

## Abstract

**Introduction:** Purpose to study prevalence of the intraarticular chondral lesion in the malleolar fracture by using ankle arthroscopy to fully understand the severity and complexity of the injury. **Methods:** Cross sectional study of 32 patients diagnosed with ankle fracture and undergone open reduction and internal fixation with arthroscopic assessment performed simultaneously. The mechanism of injury, patterns of injury and intraarticular chondral injury were documented. **Results:** Mean age was 38 years (SD = 14.1, range 18 - 68 years). Eighteen were female and 14 were male. Fifteen involved syndesmotic disruption, 22 had Danis-Weber B injury and 16 had supination external rotation (SER). Ten (31.2%) had positive intraoperative cartilage injury. Significant correlation between the Lauge-Hansen classifications with positive findings with 6 had SER, 2 had pronation adduction and 2 had pronation external rotation. **Conclusion:** The prevalence of chondral injury in ankle fracture was quite high and may leads to poor outcome. Arthroscopy procedure allow surgeon to assess intraarticular surface and reduction of the ankle fracture which prompt further intervention that may improve the clinical outcomes and prognosis of the patients.

## Keywords

Ankle Fracture, Malleolar Fracture, Ankle Arthroscopy, Arthroscopy Assessment, Chondral Injury, Articular Injury, Cartilage Injury, Intraarticular Injury

## 1. Introduction

Ankle fractures are commonly seen in trauma settings consists 55% of all frac-

tures in the foot and ankle region [1]. The ankle fracture can be treated by operative or non-operative method depending on the severity of the injury [2]. The prognosis however is uncertain. The recent outcomes showed improvement following anatomic restoration of the ankle joints but problems such as chronic pain, limited ankle motions and perceived instability are the poor long terms sequales that happens unpredictably [3].

Besides fracture malunion, undiagnosed syndesmosis injury and associated ligamentous or chondral lesions may also lead to the poor surgical outcome. This may arise from limitation of preoperative radiographs and intraoperative fluoroscopic stress view in addressing the syndesmosis disruption and ligamentous tear [4]. In recent years, accuracy of diagnosing the exact ankle injuries has been increase with new development of imaging [5]. Ankle arthroscopy which can provide direct vision of the intraarticular chondral condition and syndesmostic distruption is becoming popular both as the diagnostic and therapeutic tools in addressing ankle fracture [6] [7] [8] [9]. With recent development of camera system, distraction techniques and specialized instruments, ankle arthroscopy become a safe and less invasive technique than open technique in detecting tibiotalar aricular surface and syndesmostic joint injury [9] [10] [11].

Despite after good fixation and well united fracture, sometime patients still have pain with limitation of functions. This give rise to the concern of whether the diagnosis is exact and proper treatment has been given [12]. Recent studies of radiography assessment pre and intraoperative accuracy showed the shortfalls of both assessments [4] [5]. Undiagnosed injury may become the culprit that debilitates patients. Magnetic resonance imaging (MRI) may provide more accurate diagnosis however not feasible to be done in terms of limited resource and it is only a diagnostic tools. Contrary to ankle arthroscopy, the assessment of the articular surface and occult chondral injury can be done by MRI [13].

Although the instrument and techniques of arthroscopy improved tremendously making the procedure safer and beneficial nowadays, arthroscopic assessment of intra-articular is not routinely done. By performing the assessment, proper treatment of any detected lesion can be given in one setting which is may lead to better outcome [14] [15]).

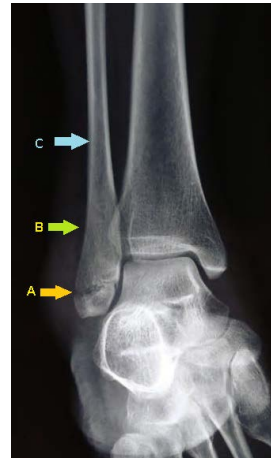This study was conducted to determine the prevalence of the intraarticular chondral lesion in the malleolar fracture by using ankle arthroscopy to fully understand the severity and complexity of the injury.

## 2. Methodology

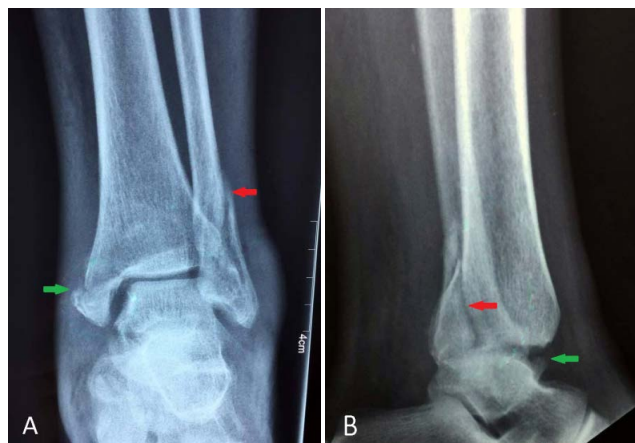A cross sectional study was conducted from April 2017 until December 2018 involving all patients diagnosed to have malleolar fracture that presented to Orthopaedics department of Hospital Raja Perempuan Bainun in Perak, Malaysia which is unstable and need surgical intervention as decided by doctors in charge of the patients including closed fracture of lateral malleolus, medial malleolus, bimalleolar and trimalleolar with or without subluxation and any undisplaced fracture that might displaced once the swelling reduced.

The exclusion criteria were open fracture, ankle dislocation, underlying diagnosis of inflammatory and degenerative arthritis and unfavourable soft tissue condition. After all the inclusion and exclusion criteria being fulfilled, consent was taken.

Evaluation of the pattern of injury further classified into isolated or bimalleolar fracture, Lauge-Hansen classification and Danis-Weber classification based on pre-operative radiograph film [2] [16] [17] as shown in examples of cases below in **Figure 1** and **Figure 2**.



**Figure 1.** One of the cases that had Danis-Weber A fracture which classified based on location of fibular fracture. (A, Infrasyndesmotic (generally not associated with ankle instability); B, Transsyndesmotic; C, Suprasyndesmotic).



**Figure 2.** One of cases that had supination external rotation of the Lauge-Hansen classification system that based on position of the foot and direction of force during injury. (A, Anteroposterior view of ankle; B, Lateral view; red arrow, lateral malleolus fracture; green arrow, medial malleolus fracture).

Patient was put in supine position and tourniquet applied. Reduction of fracture was done and fixed according to the fracture using plate or screw. The soft tissue was assessed intraoperative and only in favourable soft tissue arthroscopy examination was done. Ankle arthroscopy was done by a foot and ankle trainee

supervised by consultants of Foot and Ankle team in this centre.

Standard portal of anteromedial and anterolateral was used. Ankle arthroscopy was done using 2.7 mm 30 degrees arthroscope. Motorised shaver and probe used to assess the chondral surface and chondralmalacia was graded using Outerbridge classification [18]. The Outerbridge classification is a grading system for joint cartilage breakdown that has been validated and accepted by international sport associations as shown below (Table 1).

**Table 1.** Outerbridge classification.

Grade	Description
0	Normal
1	Cartilage with softening and swelling
2	Partial-thickness defect with fissures on the surface that do not reach subchondral bone or exceed 1.5 cm in diameter
3	Fissuring to the level of subchondral bone in an area with a diameter more than 1.5 cm
4	Exposed subchondral bone

Gravitational inflow and outflow irrigation system was used. Stability of the syndesmostic joint was assessed using shaver (drive through sign). Any chondral injury detected subsequently treated by microfracture and debridement done depending on surgeon's discretion. No further follow up was done as this study was a prevalence study to see the injury.

Data entry and statistical analysis was done using SPSS software version 22.0 (IBM Corp., 2013). The data was presented as mean and standard deviation (SD) for numerical variables and frequency with their percentage (%) for categorical variables. Univariate analysis was done using Pearson Chi Square or Fisher Exact test to analyse the association between categorical variables. *P* values  $\leq 0.05$  is deemed statistically significant. This research was approved by reviewed and approved by Malaysian Medical Research & Ethical Committee (NMRR-17-307-34256).

### 3. Results

There were 32 patients involved in this study with mean age was 38 years (SD = 14.1, range 18 - 68 years). Of all patients, 18 were female and 14 were male. All of them had only one side of the ankle involved. The sociodemographic characteristics are as showed in Table 2. Fourteen out of 18 female patients sustained the injuries after fall while eleven out of 14 male patients mostly involved in road traffic accidents. There is significant association between sexes of the patients with mechanism of injuries (*p* value = 0.004). Six out of 18 female patients sustained chondral injuries while four out of 14 male patients sustained chondral injuries. There is no significant association between sexes of the patients with chondral injuries (*p* value = 1.000).

**Table 2.** Socio-demographic characteristics (n = 32).

Variables	Frequency (%)	Mean (SD)
Age (year)		38.03 (14.16)
Sex		
Male	14 (43.8)	
Motorvehicle accidents	11 (78.6)	
Fall	3 (21.4)	
Female	18 (56.2)	
Motorvehicle accidents	14 (77.8)	
Fall	4 (22.2)	
Sex		
Male	14 (43.8)	
Chondral injury	4 (28.6)	
No chondral injury	10 (71.4)	
Female	18 (56.2)	
Chondral injury	6 (33.3)	
No chondral injury	12 (66.7)	

The patterns of injuries were described into different aspects and classification. The injuries were divided into involvement syndesmostic joints, numbers of malleolus, Danis-Weber classification of lateral malleolus and Lauge-Hansen classification. The patterns of injuries then were analysed to see the relationship with mechanism of injuries as in **Table 3**.

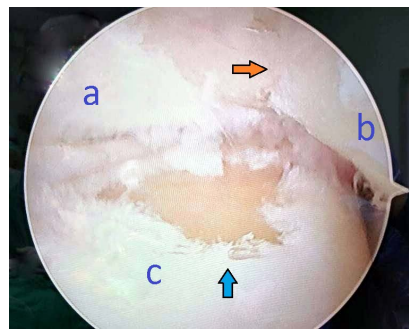
**Table 3.** Relationship of fracture pattern in relation to mechanism of injury (n = 32).

Variables	Group Frequency (% of total sample)		$\chi^2$ (df)	p value
	Fall (n = 17)	MVA (n = 15)		
Syndesmosis joint				
Intact	11 (64.7)	6 (40.0)	1.95 (1)	0.287 <sup>a</sup>
Diathesis	6 (35.3)	9 (60.0)		
Involved malleolus				
Medial only	1 (3.1)	4 (12.5)	4.31 (0)	0.228 <sup>b</sup>
Lateral only	3 (9.4)	2 (6.2)		
Bimalleolar	8 (25.0)	8 (25.0)		
Trimalleolar	5 (15.6)	1 (3.1)		
Danis-Weber				
Intact fibula	1 (3.1)	4 (12.5)	3.78 (0)	0.271 <sup>b</sup>
A	1 (3.1)	2 (6.2)		
B	14 (43.8)	8 (25.0)		
C	1 (3.1)	1 (3.1)		
Lauge-Hansen				
SER	10 (31.2)	6 (18.8)	5.73 (0)	0.112 <sup>b</sup>
PER	1 (3.1)	1 (3.1)		
PA	5 (15.6)	2 (6.2)		
SA	1 (3.1)	6 (18.8)		

**Note:** <sup>a</sup>Pearson Chi Square; <sup>b</sup>Fisher Exact test. (SER, supination external rotation; SA, supination adduction; PA, pronation abduction; PER, pronation external rotation).

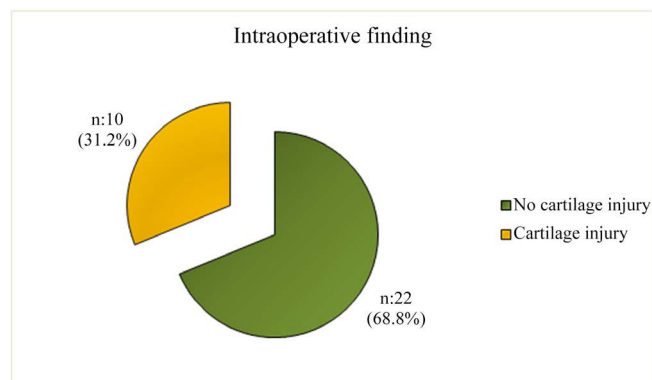
Results showed number of syndesmotic joint injury almost equally occurred in patients after motor vehicle accidents but most patients in fall group had intact syndesmotic joint. Half of the patients had bimalleolar fractures which contribute by both mechanism of injury equally. Around 79% of patients presented with fibula fracture at the level of syndesmotic joint (Danis-Weber B) with majority from fall group patients. By Lauge-Hansen classification, 50% of the patient had supination external rotation injury. However none of the pattern of injuries had significant association with mechanism of injuries.

**Figure 3** showed example of case that had positive findings intraoperative. Arthroscopic examination of the intraarticular lesions was done after the reduction and internal fixations of the fracture done. In cases that intraarticular surface was not well reduced, the reduction was repeated until satisfactory articular surface achieved.



**Figure 3.** Arthroscopic view of the right ankle showed grade 3 cartilage injuries exposing the subchondral bone. (a, Tibia plafond; b, Medial malleolus; c, Talus dome; orange arrow, fracture line of medial malleolus; blue arrow, intraarticular chondral lesion).

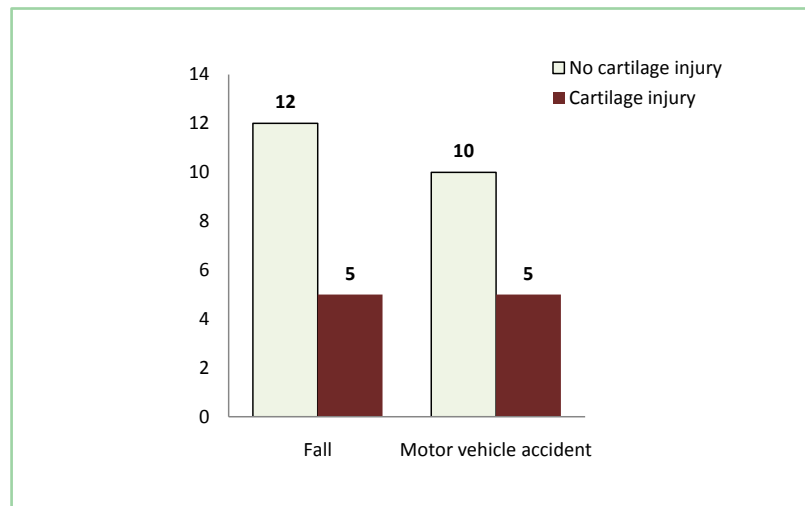
Arthroscopy assessment of the ankle joint in 32 patients revealed that 31.2% (n = 10) of patients had intraarticular injury as shown in **Figure 4**. Twenty two patients did not have intraarticular injury.



**Figure 4.** Prevalence of cartilage injuries in 32 patients.

They were equally contributed by both group of mechanism of injuries fall (n

= 5) and motor vehicle accidents (n = 5). No significant correlation between mechanism of injury and intraarticular cartilage injury ( $p$  value = 0.555) as shown in **Figure 5**.



**Figure 5.** Prevalence of cartilage injury in different type of mechanism of injuries.

The types of fracture pattern in relation to intraoperative findings of cartilage injury as in **Table 4**.

**Table 4.** The types of fracture pattern in relation to intraoperative findings of cartilage injury (n = 32).

Variables	Group Frequency (% of total sample)		$\chi^2$ (df)	p value
	No Cartilage Injury (n = 22)	Cartilage Injury (n = 10)		
Syndesmosis joint				
Intact	13 (40.6)	4 (12.5)	1.01 (1)	0.450 <sup>a</sup>
Diathesis	9 (28.1)	6 (18.8)		
Involved malleolus				
Medial only	4 (12.5)	1 (3.1)	2.58 (0)	0.535 <sup>b</sup>
Lateral only	2 (6.2)	3 (9.4)		
Bimalleolar	11 (34.4)	5 (15.6)		
Trimalleolar	5 (15.6)	1 (3.1)		
Danis-Weber				
Intact fibula	4 (12.5)	1 (3.1)	4.73 (0)	0.148 <sup>b</sup>
A	3 (9.4)	0 (0.0)		
B	15 (46.9)	7 (21.9)		
C	0 (0.0)	2 (6.2)		
Lauge-Hansen				
SER	10 (31.2)	6 (18.8)	7.11 (0)	0.052 <sup>b</sup>
PER	0 (0.0)	2 (6.2)		
PA	5 (15.6)	2 (6.2)		
SA	7 (21.9)	0 (0.0)		

**Note:** <sup>a</sup>Pearson Chi Square; <sup>b</sup>Fisher Exact test. (SER, supination external rotation; SA, supination adduction; PA, pronation abduction; PER, pronation external rotation).

Most of the patients that had intact syndesmotiic joint did not have intraarticular injury. Six (18.8%) out 15 patients that had syndesmotiic disruption had intraarticular injury. Half of the patients had bimalleolar fracture and 5 (15.6%) of them had intraarticular injury which was the highest number. Seven (21.9%) patients from Danis-Weber B fibula fracture had intraarticular injury but not significant statistically.

Fifty percent of patients sustained supination external rotation injury and 6 (18.8%) had intraarticular injury. A Fisher's exact test indicated that the prevalence of intraarticular injury among type of fracture in Lauge-Hansen classification were significantly different,  $p$  value = 0.05. Therefore there was significant association between type of fracture in Lauge-Hansen classification and intraarticular cartilage injury.

Further descriptions of intraarticular injuries were shown in the **Table 5** below.

**Table 5.** Descriptive data intraoperative finding with mechanism of injury and Lauge Hansen classification in the group of patients with cartilage injury. All the cartilage injuries were grade 1 unless stated otherwise.

ID PATIENTS	MECHANISM OF INJURY	LAUGE-HANSEN	TIBIA SURFACE	TALUS SURFACE
1	Fall	SER	-	Center
3	Fall	PA	-	Medial
11	MVA	SER	-	Center (Grade 2)
12	MVA	PA	Center	Center, medial
13	Fall	SER	Medial	-
14	MVA	SER	Medial	Center
19	MVA	SER	-	Medial (Grade 3)
21	Fall	SER	-	Medial
24	Fall	PER	-	Medial (Grade 2)
27	MVA	PER	-	Medial (Grade 3)

(MVA, motor vehicle accident; SER, supination external rotation; SA, supination adduction; PA, pronation abduction; PER, pronation external rotation).

Among the 10 patients with cartilage injury, 7 patients had lesion only at talus and one patient had injury only at tibia surface. Two patients had lesion both in talus and tibia cartilage with one of them had kissing lesion involving center part both tibia and talus. Six patients had chondral lesion over the medial part of the talar dome and 3 subjects had lesion over the center of the talar dome. The degree of injuries varies in term of severity and most of them had grade one cartilage injury. Two patients had grade 2 injury and 2 patients had grade 3.



## 4. Discussions

The results of this study showed almost a third of the patients had intraarticular injury when arthroscopy assessments were done. Previous papers had wide range of positive findings from 63% (8, 9) to 79.2% [19]. The low percentage found in this study could be due to the low energy injuries as the more severe injuries either severe soft tissue problem or dislocation were excluded from the study. Although the percentages of positive intraoperative findings were widely ranged, we learnt that the outcome of ankle fracture might be affected by cartilage injury.

In this study, ankle fractures were mainly caused by motor vehicle accidents and fall. These two different mechanisms of injuries had different load of energy and direction [20] [21]. Most of the time when patient had a fall, the foot been twisted and energy was loaded in rotational direction. However in road traffic accident, usually the ankle was hit with direct high energy impact. In our local setting, motorcycles are among one of the popular mode of transportation that carry higher risk of injury to foot and ankle region.

In this study, female patients prone to injury after fall while male patients mostly had motor vehicle accidents. Previous study of epidemiology showed 53.5% of cases occurred on the street [1] and in this study 46.9% injuries had occurred involving motor vehicle accidents. From this study, there was no significant association between mechanism of injury and pattern of injury. Both group of mechanism also had same amount of subjects that had intraarticular chondral injury. Berndt and Hardy [22] based on radiography finding postulated that the principal force was torsional impaction. When tibia was internally rotated, shear force potentially displacing a lateral osteochondral fragment was produced by forced dorsiflexion and inversion leading to impacted and compressed the lateral talar margin against the medial articular surface of the fibula. However with the tibia in external rotation, shear force at the medial dome was caused by plantarflexion and inversion that impacted the medial articulation of the talus against the posteromedial tibia.

From our data, there was significant correlation between Lauge-Hansen classifications with chondral injury. Supination external rotation had the 6 (18.8%) subjects with intraarticular positive findings. However the observation among the chondral injury group revealed that most chondral lesions injury occurred at talus articular surface with 6 at the medial surface of the dome, 3 at the center part of dome and one had both site injured.

No exact mechanism that causing chondral injury is conclusively known [10] [19] [23] [24]. In our series, supination external rotation caused 5 injuries at talus cartilage and 2 injuries at tibia (one of subject had both surface affected). Our data seemed to be in line with the theory postulated by Berndt and Hardy as the supination external rotation had more injury on the medial side of the ankle. Hintermann [19] reviewed 288 consecutive patients had 79.2% osteochondral injury and reported the incidence of talar dome lesions of 69.4% which was

much higher than our sample group.

Leontaritis [25] with 84 patients had 73% of intraarticular chondral injury and 61% in talar side. They described in details regarding the location of injury with the severity of ankle fracture pattern based on the Lauge-Hansen classification. They were able to demonstrate that the severity of the acute ankle fractures based on the Lauge-Hansen criteria is associated with an increased number of chondral lesions in the ankle. They noted that in pronation external rotation and supination external rotation type-IV ankle fracture is 8.1 and 9.7 times more likely than a type-I or a type-II ankle fracture associated with two chondral lesions or more. In our study both pronation external rotation and supination external rotation fracture had presented with more severe injury both grade 2 and 3 each but we did not specified the stage of injury each pattern while in their study only the numbers of lesion counted and did not mention the depth of the lesions,. Cheng [26] developed arthroscopic staging of the talar osteochondral lesions as in **Table 6**.

**Table 6.** Arthroscopic staging of talar osteochondral lesions.

STAGE	DESCRIPTIONS
A	Articular cartilage is smooth and intact but soft
B	Articular cartilage surface is rough
C	Fibrillation or fissuring of the cartilage is present
D	Osteochondral flap is present or bone is exposed
E	Osteochondral fragment is detached but undisplaced
F	Osteochondral fragment is detached and displaced

Therefore based on the previous study and our data, it is justified to perform routine inspection of the talar dome during the surgical treatment of ankle fractures. Ackerman [6] reported the trends of treatment of ankle fracture with arthroscopy procedures were changing over 5-year period between 2007 and 2011. During these period surgeons performed arthroscopic treatment simultaneously during open repair of ankle fractures with significant increased prevalence while prevalence of arthroscopic ankle treatments occurring in a subsequent procedure after any ankle fracture treatment decreased significantly. This was due to earlier detection and treatment of cartilaginous injuries in acute ankle fractures and able to promote better healing and outcome.

Hence subsequent more studies were done to evaluate the effectiveness of doing arthroscopy simultaneously with open reduction and internal fixation [15] [27] [28] [29] [30]. In few of the studies that compared the outcome of the procedure against the conventional methods without arthroscopy assistance, it was difficult to justify that arthroscopic assistance fixations improves the outcomes of the fracture. No clear suggestion should arthroscopy become routinely incorporated with open reduction and internal fixation or selectively done with certain indications to guide the treatment algorithm for optimum outcomes.

Ackerman [6] noted however the need of second surgery much reduced in recent years as the numbers of integrated arthroscopic procedures increased. More data in term of long term outcomes need to be obtained by future research as post traumatic cartilage degenerative progress over period of time. The comparison of complication rates and total operating times of open reduction and internal fixation with or without arthroscopy assistance was unclear and data was lacking in order to strongly suggest the potential of arthroscopy role in treating ankle fracture.

The complications of ankle arthroscopy procedure may deter the good outcomes [30] [31]. The most common complication is superficial peroneal nerve injury. Others were post-operative infection, swelling, complex regional pain syndrome and further insult to the cartilage. Therefore proper indications and training are needed before considering incorporating the procedures as it might worsen the outcomes. Arthroscopy is useful in assessing the osteochondral lesions but it is unable to completely assess underlying bony lesions which is better visualised in magnetic resonance imaging.

Limitations of this study were small sample size and did not properly quantify the sizes of the lesions. No complications data was documented and may need prospective long term outcome study for more impact.

## 5. Conclusion

The prevalence of chondral injury in ankle fracture was quite significant and may lead to poor outcome. Arthroscopy procedure allow surgeon to assess intra-articular surface and reduction of the ankle fracture which prompt further intervention that may improve the clinical outcomes and prognosis of the patients.

## Acknowledgements

The authors would like to thank clinical research centres, Hospital Raja Permaisuri Bainun and Hospital Tuanku Fauziah for the advice and help on statistical analysis and evaluation. We are grateful to Dr Manoharan (Head of Orthopaedic Department) for his support.

## Conflicts of Interest

The authors declare no conflicts of interest regarding the publication of this paper.

## References

- [1] Shibuya, N., Davis, M.L. and Jupiter, D.C. (2014) Epidemiology of Foot and Ankle Fractures in the United States: An Analysis of the National Trauma Data Bank (2007 to 2011). *The Journal of Foot & Ankle Surgery*, **53**, 606-608. <https://doi.org/10.1053/j.jfas.2014.03.011>
- [2] Westerman, R. and Porter, K. (2007) Ankle Fractures in Adults: An Overview. *Trauma*, **9**, 267-272. <https://doi.org/10.1177/1460408607088292>
- [3] Roberts, V., Mason, L.W., Harrison, E., Molloy, A.P. and Mangwani, J. (2018) Does

Functional Outcome Depend on the Quality of the Fracture Fixation? Mid to Long Term Outcomes of Ankle Fractures at Two University Teaching Hospitals. *European Foot and Ankle Society*. <https://doi.org/10.1016/j.fas.2018.04.008>

- [4] Beumer, A., Hemert, W.L.W., Niesing, R., Entius, C.A.C., Ginai, A.Z., Mulder, P.G.H., *et al.* (2004) Radiographic Measurement of the Distal Tibiofibular Syndesmosis Has Limited Use. *Clinical Orthopaedics and Related Research*, **423**, 227-234. <https://doi.org/10.1097/01.blo.0000129152.81015.ad>
- [5] Femino, J.E., Vaseenon, T., Phistkul, P., Tochigi, Y., Anderson, D.D. and Amendola, A. (2013) Varus External Rotation Stress Test for Radiographic Detection of Deep Deltoid Ligament Disruption with and without Syndesmotic Disruption: A Cadaveric Study. *Foot & Ankle International*, **34**, 251-260. <https://doi.org/10.1177/1071100712465848>
- [6] Ackermann, J., Fraser, E.J., Murawski, C.D., Desai, P., Vig, K. and Kennedy, J.G. (2016) Trends of Concurrent Ankle Arthroscopy at the Time of Operative Treatment of Ankle Fracture: A National Database Review. *Foot & Ankle Specialist*, **9**, 107-112. <https://doi.org/10.1177/1938640015599034>
- [7] Chan, K.B. and Lui, T.H. (2016) Role of Ankle Arthroscopy in Management of Acute Ankle Fracture. *Arthroscopy: The Journal of Arthroscopic and Related Surgery*, **32**, 2373-2380. <https://doi.org/10.1016/j.arthro.2016.08.016>
- [8] Cunha, R.J.D., Karnovsky, S.C., Schairer, W. and Drakos, M.C. (2018) Ankle Arthroscopy for Diagnosis of Full-Thickness Talar Cartilage Lesions in the Setting of Acute Ankle Fractures. *Arthroscopy: The Journal of Arthroscopic and Related Surgery*, **34**, 1950-1957. <https://doi.org/10.1016/j.arthro.2017.12.003>
- [9] Loren, G.J. and Ferkel, R.D. (2002) Arthroscopic Assessment of Occult Intra-Articular Injury in Acute Ankle Fractures. *Arthroscopy: The Journal of Arthroscopic and Related Surgery*, **18**, 412-421. <https://doi.org/10.1053/jars.2002.32317>
- [10] Takao, M., Ochi, M., Uchio, Y., Naito, K., Kono, T. and Oae, K. (2003) Osteochondral Lesions of the Talar Dome Associated with Trauma. *Arthroscopy: The Journal of Arthroscopic and Related Surgery*, **19**, 1061-1067. <https://doi.org/10.1016/j.arthro.2003.10.019>
- [11] Glazebrook, M.A., Ganapathy, V., Bridge, M.A., Stone, J.W. and Allard, J.-P. (2009) Evidence-Based Indications for Ankle Arthroscopy. *Arthroscopy: The Journal of Arthroscopic and Related Surgery*, **25**, 1478-1490. <https://doi.org/10.1016/j.arthro.2009.05.001>
- [12] Nilsson, G.M., Jonsson, K., Ekdahl, C.S. and Eneroth, M. (2005) Unsatisfactory Outcome Following Surgical Intervention of Ankle Fractures. *Foot and Ankle Surgery*, **11**, 11-16. <https://doi.org/10.1016/j.fas.2004.10.004>
- [13] Sijbrandij, E.S., Gils, A.P.G., Louwerens, J.W.K. and Lange, E.E. (2000) Posttraumatic Subchondral Bone Contusions and Fractures of the Talotibial Joint: Occurrence of "Kissing" Lesions. *American Journal of Roentgenology*, **175**, 1707-1710. <https://doi.org/10.2214/ajr.175.6.1751707>
- [14] Yasui, Y., Shimozone, Y., Hung, C., Marangon, A., Wollstein, A., Gianakos, A.L., *et al.* (2019) Postoperative Reoperations and Complications in 32,307 Ankle Fractures with and without Concurrent Ankle Arthroscopic Procedures in a 5-Year Period Based on a Large U.S. Healthcare Database. *The Journal of Foot & Ankle Surgery*, **58**, 6-9. <https://doi.org/10.1053/j.jfas.2018.03.030>
- [15] Min, L.K., Sonya, A., Seok, P.M., Hyuk, S.K., Yeol, L.S. and Seungbum, K. (2017) Effectiveness of Arthroscopically Assisted Surgery for Ankle Fractures: A Meta-Analysis. *Injury*, **48**, 2318-2322.

- [16] Tartaglione, J.P., Rosenbaum, A.J., Abousayed, M. and DiPreta, J.A. (2015) Classifications in Brief: Lauge-Hansen Classification of Ankle Fractures. *Clinical Orthopaedics and Related Research*, **473**, 3323-3328. <https://doi.org/10.1007/s11999-015-4306-x>
- [17] Fonseca, L.L., Nunes, I.G., Nogueira, R.R., Martins, G.E.V., Mesencio, A.C. and Kobatac, S.I. (2018) Reproducibility of the Lauge-Hansen, Danis-Weber, and AO Classifications for Ankle Fractures. *Revista Brasileira de Ortopedia*, **53**, 101-106. <https://doi.org/10.1016/j.rboe.2017.11.013>
- [18] Slattery, C. and Kweon, C.Y. (2018) Classifications in Brief: Outerbridge Classification of Chondral Lesions. *Clinical Orthopaedics and Related Research*, **476**, 2101-2104. <https://doi.org/10.1007/s11999-0000000000000255>
- [19] Hintermann, B., Regazzoni, P., Lampert, C., Stutz, G. and Gächter, A. (2000) Arthroscopic Findings in Acute Fractures of the Ankle. *Journal of Bone and Joint Surgery*, **82**, 345-351. <https://doi.org/10.1302/0301-620X.82B3.0820345>
- [20] Lawson, K.A., Ayala, A.E., Morin, M.L., Latt, L.D. and Wild, J.R. (2018) Ankle Fracture-Dislocations: A Review. *Foot & Ankle Orthopaedics*, **3**, 1-8. <https://doi.org/10.1177/2473011418765122>
- [21] Kwon, J.Y., Chacko, A., Kadzielski, J., Appleton, P. and Rodriguez, E.K. Correlating Injury Mechanism with Fracture Patterns of the Ankle: Challenging Long-Standing Orthopaedic Dogma Using Injury Videos. *OrthoJournalhms*, **11**, 74-78.
- [22] Berndt, A.L. and Harty, M. (1959) Transchondral Fractures (Osteochondritis Dissecans) of the Talus. *The Journal of Bone and Joint Surgery. American Volume*, **41**, 988-1020. <https://doi.org/10.2106/00004623-195941060-00002>
- [23] Stufkens, S.A.S., Bekerom, M.P.J., Kerkhoffs, G.M.M.J., Hintermann, B. and Dijk, C.N. (2011) Long-Term Outcome after 1822 Operatively Treated Ankle Fractures: A Systematic Review of the Literature. *Injury*, **42**, 119-127. <https://doi.org/10.1016/j.injury.2010.04.006>
- [24] Sorrento, D.L. and Mlodzienski, A. (2000) Incidence of Lateral Talar Dome Lesions in SER IV Ankle Fractures. *The Journal of Foot & Ankle Surgery*, **39**, 354-358. [https://doi.org/10.1016/S1067-2516\(00\)80070-8](https://doi.org/10.1016/S1067-2516(00)80070-8)
- [25] Leontaritis, N., Hinojosa, L. and Panchbhavi, V.K. (2009) Arthroscopically Detected Intra-Articular Lesions Associated with Acute Ankle Fractures. *The Journal of Bone and Joint Surgery. American Volume*, **91**, 333-339. <https://doi.org/10.2106/JBJS.H.00584>
- [26] Cheng, M.S., Ferkel, R.D. and Applegate, G.R. (1995) Osteochondral Lesions of the Talus: A Radiological and Surgical Comparison. *Annual Meeting of the American Academy of Orthopaedic Surgeons*, Orlando, 2-26 February 1995.
- [27] Turhan, E., Doral, M.N., Demirel, M., Atay, A.O., Bozkurt, M., Bilge, O., et al. (2013) Arthroscopy-Assisted Reduction versus Open Reduction in the Fixation of Medial Malleolar Fractures. *European Journal of Orthopaedic Surgery & Traumatology*, **23**, 953-959. <https://doi.org/10.1007/s00590-012-1100-2>
- [28] Thordarson, D.B., Bains, R. and Shepherd, L.E. (2001) The Role of Ankle Arthroscopy on the Surgical Management of Ankle Fractures. *Foot & Ankle International*, **22**, 123-125. <https://doi.org/10.1177/107110070102200207>
- [29] Gonzalez, T.A., Macaulay, A.A., Ehrlichman, L.K., Drummond, R., Mittal, V. and DiGiovanni, C.W. (2015) Arthroscopically Assisted versus Standard Open Reduction and Internal Fixation Techniques for the Acute Ankle Fracture. *Foot & Ankle International*, **37**, 554-562. <https://doi.org/10.1177/1071100715620455>
- [30] Ono, A., Nishikawa, S., Nagao, A., Irie, T., Sasaki, M. and Kouno, T. (2004) Arth-

roscopically Assisted Treatment of Ankle Fractures: Arthroscopic Findings and Surgical Outcomes. *Arthroscopy: The Journal of Arthroscopic and Related Surgery*, **20**, 627-631. <https://doi.org/10.1016/j.arthro.2004.04.070>

- [31] Zekrya, M., Shahbana, S.A., Gamala, T.E. and Plattb, S. (2018) A Literature Review of the Complications Following Anterior and Posterior Ankle Arthroscopy. *Foot and Ankle Surgery*, **25**, 553-558.