

# Bilateral Multi-Level Pedicle Fractures in the Lumbar Spine Secondary to Trauma: A Case Report and Literature Review

Noukhoum Koné 

Department of Neurosurgery, Kiffa Hospital Center, Kiffa, Mauritania

Email: colo10fr@hotmail.com

**How to cite this paper:** Koné, N. (2020) Bilateral Multi-Level Pedicle Fractures in the Lumbar Spine Secondary to Trauma: A Case Report and Literature Review. *Open Journal of Modern Neurosurgery*, 10, 422-426.

<https://doi.org/10.4236/ojmn.2020.104044>

**Received:** May 31, 2020

**Accepted:** October 10, 2020

**Published:** October 13, 2020

Copyright © 2020 by author(s) and Scientific Research Publishing Inc. This work is licensed under the Creative Commons Attribution International License (CC BY 4.0).

<http://creativecommons.org/licenses/by/4.0/>



Open Access

---

## Abstract

Pedicle fractures are among the least common; those involving bilateral pedicle fractures are rare. To our knowledge, there are no previous reports of bilateral multi-level pedicle fractures in the lumbar spine secondary to trauma concerning adolescents. We report a 14-year-old male with bilateral multi-level traumatic pedicle fractures (BMTPF) of lumbar spine (LS) three and five (L3, L5) and spondylolisthesis of L3 on L4 (classified Meyerding grade II). Posterior lumbar instrumentation from L1 to S1 was performed. Post-operative recovery was uneventful. The aims of the study were to provide the first documentation of this pattern of injury in adolescents LS secondary to trauma and to review literature. The patient's parents were informed that non-identifying information from the case would be submitted for publication, and they provided consent.

## Keywords

Pedicle, Traumatic Fracture, Lumbar Spine, Screws

---

## 1. Introduction

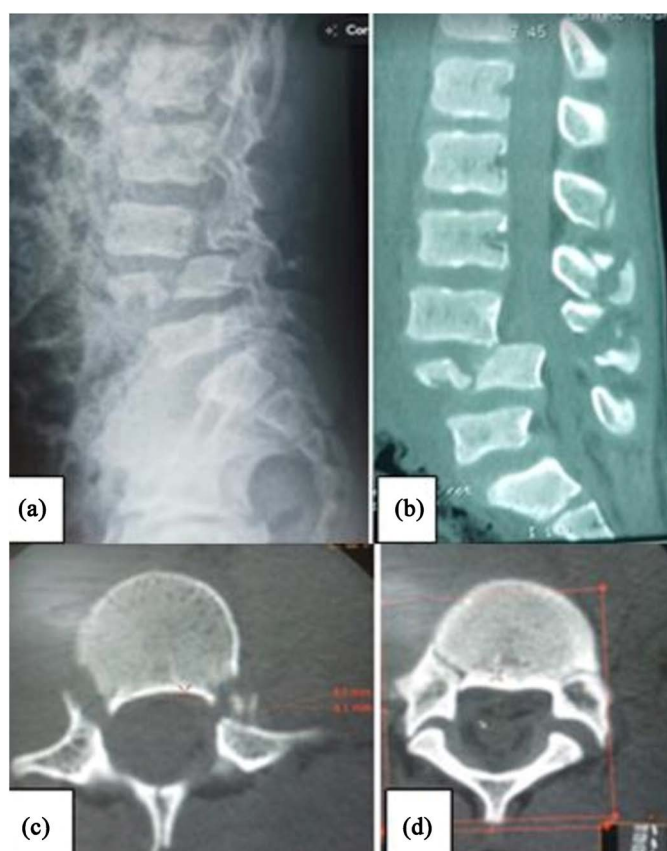A combination of several mechanical factors, such as vertical compression, distraction, extension, rotational and shear forces can cause various types of fracture dislocations of the spine [1] [2]. Shear fracture-dislocation lumbar spine (LS) below the level of LS two (L2) is rare [3] [4] [5]. Of the injuries involving LS, pedicle fractures are among the least common; those involving bilateral pedicle fractures are rare. Only 2 cases of bilateral multi-level traumatic pedicle fractures (BMTPF) of lumbar vertebrae were reported [5] [6]. We are not aware of previous reports of this pattern of injury concerning adolescent LS. The aims

of this present study were to provide the first documentation of this pattern of injury in adolescents LS secondary to trauma and to review literature.

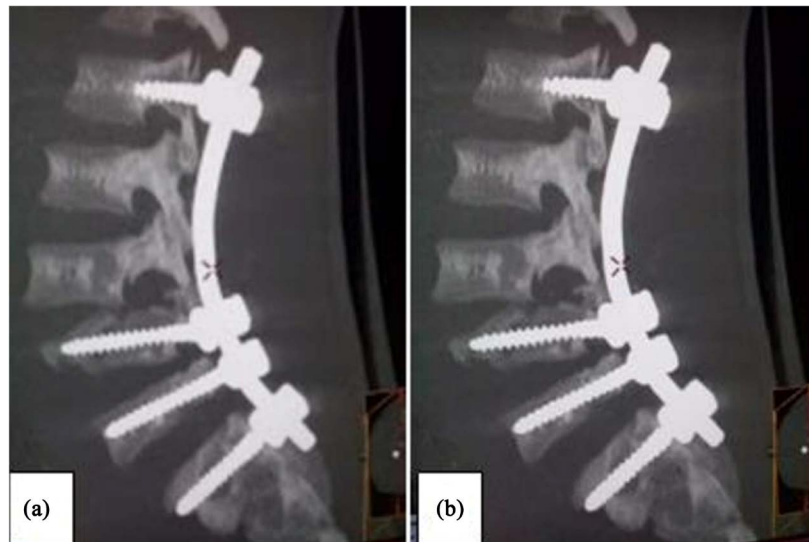
## 2. Case Presentation

A 14-year-old male was referred to our hospital with a story of LS trauma following a fall from a tree about 3.5 meters high with reception on the buttocks and then receives the tree trunk on the LS (the patient's trunk slightly deflected during the second trauma). At the time of presentation, he complained of low back pain, motor weakness of grade 3/5 of the iliopsoas, quadriceps and tibialis anterior on both side, hypoesthesia at higher level LS three (L3), no sphincter disorder. Radiograph of the LS with lateral view (**Figure 1(a)**) revealed L3 pedicle fracture and complex fracture of LS four (L4).

Computed tomography (CT) scan in sagittal (**Figure 1(b)**) and axial (**Figure 1(c)** and **Figure 1(d)**) sections showing a complex L4 fracture (**Figure 1(a)** and **Figure 1(b)**), spondylolisthesis of L3 on L4 (classified Meyerding grade II) (**Figure 1(a)** and **Figure 1(b)**), spinals processes L2, L3 and L4 fractures (**Figure 1(b)**); bipedicular fracture of L3 (**Figure 1(c)**) and L5 (**Figure 1(d)**).



**Figure 1.** (a) Radiograph of the lumbar spine with lateral view revealed L3 pedicle fracture and complex fracture of L4; (b) Lumbar CT scan in sagittal section showing a complex L4 fracture, spondylolisthesis of L3 on L4 (classified Meyerding grade II), spinous processes L2, L3 and L4 fractures and axial. Lumbar CT scan in axial sections (c) (d) showing a bipedicular fracture of L3 (c) and L5 (d).



**Figure 2.** Lumbar postoperative CT scan showing osteosynthesis material in place in right (a) and left (b) pedicle sagittal sections.

After posterior decompression of nerve structures by laminectomy of L3, L4 and L5, we noted a flow of cerebrospinal fluid, the dural tear was repaired. Posterior articular were removed from L4 to S1, and then stabilisation with mono- and poly-axial screws associated with pre-lordosed rods were performed from L1 to S1 (**Figure 2(a)** and **Figure 2(b)**).

The interfractural gap of the L3 pedicles (6.1 mm on the left and 8 mm on the right) being important, that's why L3 could not be instrumented.

Fixation of L4 was not planned but intraoperative data oblige, L5 was fixed only on one side, the other was laborious. Since the pedicles of L4 were intact and it is a question of one growing bone, we allowed to fix L4 in order to better stabilize the assembly.

Postoperative recovery was uneventful and the patient was discharged with a thoracolumbar corset 2 weeks after without leg pain and with intact neurological function of both legs. CT scan confirmed good instrumentation. We noted a partial reduction of the L3 on L4 spondylolisthesis.

### 3. Discussion

To our knowledge, this is the first case report of BMTPF concerning adolescents LS and the third case in the literature review. Our patient presented also shear fracture-dislocation of L3 on L4. However only few cases of fracture-dislocation below the level of L2 have been reported [3] [4]. Miyamoto *et al.* [5] reported in 2004 the first case of BMTPF of LS from L2 to L5 associated to L5 on S1 spondylolisthesis in a 20-year-old woman, secondary to hit on her back by a truck when she was riding a motorcycle. The absence of injuries to the anterior and middle columns except at L5/S1 according to the author motivated conservative treatment.

Chin KR *et al.* [6] reported in 2009 the second case of BMTPF at L4 and L5

secondary to gunshot in a 20-year-old man who had in addition the bullet lodged within the L4 inferior endplate and disc space of L4 - L5, bony and metallic fragment into the central canal. Given concerns of progressive neurologic deficits, the presence of massive dural tear (CT myelogram), and dissociation of the anterior and the posterior columns, surgical decompression with fixation pedicle fractures by lag screw were performed [6].

The rarity of this injury is likely because of unusually high-energy mechanism that might be required to produce such a fracture pattern.

Traumatic, unstable lumbar spine fractures can be quite difficult to manage. Over the past 10 years, motion preservation surgery has become much more popular as an alternative means to fusion in an effort to prevent degenerative disease at adjacent levels [7]. However, with the progressive cauda equine syndrome and bilateral pedicle fractures, the literature suggests several surgical options. These include posterior instrumentation with fusion, combination anterior and posterior fusion with the use of pedicles screws by posterior approach.

In the case presented here, several factors contributed to surgical decision making including injury type and the age of the patient. Given the instability of the fracture, the compression of neural elements, and the patient's incomplete spinal cord injury. The surgeon, taking into account the on-board means, chose this method which was supposed to be simple. The result was satisfactory. Long-term follow-up will be necessary to assess clinical progress, the quality of bony fusion and instrumentation.

#### 4. Conclusions

BMTPF are rare, only two have been described in patients aged all 20 years. This is the first case encountered in an adolescent.

This pattern of injury is secondary to a high-energy trauma and responsible most often for spinal instability requiring spinal stabilization surgery with or without decompression of nerve structures.

#### Conflicts of Interest

The author declares no conflicts of interest regarding the publication of this paper.

#### References

- [1] Holdsworth, F.W. (1963) Fractures, Dislocations and Fracture-Dislocations of the Spine. *The Journal of Bone and Joint Surgery*, **45-B**, 6-20. <https://doi.org/10.1302/0301-620X.45B1.6>
- [2] Roaf, R. (1960) A Study of the Mechanics of Spinal Injuries. *The Journal of Bone and Joint Surgery*, **42-B**, 810-823. <https://doi.org/10.1302/0301-620X.42B4.810>
- [3] Barquet, A., Menendez, J., Dubra, A., Masliah, R. and Pereyra, D. (1993) Anterolateral Dislocation of the Lumbosacral Junction. *Canadian Association of Radiologists Journal*, **44**, 129-132.
- [4] Halm, H., Liljenqvist, U., Steinbeck, J. and Jeszensky, D. (1995) Lumbosacral Frac-

ture Dislocation in a Lumbarjack. *European Spine Journal*, **4**, 354-356.

<https://doi.org/10.1007/BF00300296>

- [5] Miyamoto, H., Sumi, M., Kataoka, O., Doita, M., Kurosaka, M. and Yoshiya, S. (2004) Traumatic Spondylolisthesis of the Lumbosacral Spine with Multiple Fractures of the Posterior Elements. *Journal of Bone and Joint Surgery-British Volume*, **86**, 115-118. <https://doi.org/10.1302/0301-620X.86B1.14122>
- [6] Chin, K.R., Bosseli, K. and Cairone, S. (2009) Lag Screw Fixation of Remote Bilateral Pedicle Fractures of the Fourth and Fifth Lumbar Vertebrae after a Single Gunshot Wound: A Case Report and Technical Pearl. *The Spine Journal: Official Journal of the North American Spine Society*, **10**, 136-140. <https://doi.org/10.1016/j.spinee.2009.10.007>
- [7] Murtagh, R. and Castellvi, A.E. (2014) Motion Preservation Surgery in the Spine. *Neuroimaging Clinics of North America*, **24**, 287-294. <https://doi.org/10.1016/j.nic.2014.01.008>