

Neuroblastoma in Children: Intraoperative Goal Directed Therapy, Intraoperative and Postoperative Outcomes

Claudine Kumba 

Department of Pediatric Anesthesia and Critical Care, Hôpital Universitaire Necker Enfants Malades, Assistance Publique Hôpitaux de Paris, APHP, Université de Paris, Paris, France
Email: claudine.kumba@gmail.com; claudine.kumba@aphp.fr

How to cite this paper: Kumba, C. (2021) Neuroblastoma in Children: Intraoperative Goal Directed Therapy, Intraoperative and Postoperative Outcomes. *Open Journal of Internal Medicine*, 11, 220-230.
<https://doi.org/10.4236/ojim.2021.114018>

Received: October 9, 2021

Accepted: November 30, 2021

Published: December 3, 2021

Copyright © 2021 by author(s) and Scientific Research Publishing Inc.
This work is licensed under the Creative Commons Attribution International License (CC BY 4.0).

<http://creativecommons.org/licenses/by/4.0/>



Open Access

Abstract

Background: Neuroblastoma is the most common tumor in children. Anesthetic management can be challenging due to the localization and catecholamine-secreting characteristics of the tumor. We undertook a secondary analysis in a previous study to describe patients who underwent neuroblastoma resection. **Objective:** To describe intraoperative and postoperative outcomes in patients who underwent neuroblastoma resection and to propose optimal intraoperative management for postoperative outcome improvement. **Methods:** This was a secondary analysis of children who underwent neuroblastoma resection in the initial retrospective study. **Results:** There were 16 patients with a mean age of 39.3 ± 22.1 months. Seven (43.8%) patients presented with intraoperative or postoperative complications. One (6.3%) patient had intraoperative broncho-laryngospasm and difficult intubation. Two (12.5%) patients had intraoperative hemorrhagic shock. One patient (6.3%) had postoperative renal failure. Two patients (12.5%) had postoperative respiratory failure, and 3 (18.8%) patients had postoperative cardiocirculatory failure. One (6.3%) had postoperative pulmonary sepsis and septicemia. Thirteen (81.3%) patients were intraoperatively transfused. There was no in-hospital mortality. **Conclusion:** In this cohort, 43.8% of the patients had intraoperative and or postoperative complications in terms of organ dysfunction or sepsis. 81.3% of the patients received intraoperative transfusion. Neuroblastoma surgery can be a challenging situation where cardiovascular instability, high blood loss and transfusion requirements can be encountered. Consequently, preoperative preparation and optimal intraoperative management with validated tools in children could be necessary for a better postoperative outcome in this surgical setting.

Keywords

Neuroblastoma, Children, Intraoperative Goal Directed Therapies, Postoperative Outcomes

1. Introduction

Neuroblastoma is the most common tumor in children, with an incidence of 10.2 per million children under 15 years old, and is responsible for 13% - 15% of deaths due to cancer in children [1] [2] [3] [4]. Long-term prognosis depends on the characteristics of the tumor, with five-year survival in low-risk and high-risk neuroblastoma varying from 90% - 95% to 40% - 50%, respectively [2] [5]. Surgical complications after surgery depend on the localization of the tumor and can include chylo-abdomen, chylo-thorax, Horner syndrome, pneumothorax, injury of the renal blood vessels, and injury of the inferior vena cava [6] [7].

Neuroblastoma can present different localizations as an abdominal mass from medulla adrenergic cells in 35% of cases, as spinal paraspinal ganglia in 35% of cases, as posterior mediastinal masses in 20% of cases, and as pelvis and neck masses in 5% of cases [1]. Therapeutic management of these tumors is multidisciplinary and can include surgery, chemotherapy, autologous stem cell transplant, radiotherapy, and immunotherapy depending on the characteristics of the tumor [1].

Anesthetic management of neuroblastoma surgery can be challenging due to catecholamine secreting characteristics, such as a mediastinal presentation, which can cause cardiocirculatory collapse at the induction of anesthesia and increased blood loss if the tumor is close to great vessels [6] [7] [8] [9] [10]. This emphasizes the importance of preoperative preparation of these tumors for optimal intraoperative management.

In a previously published retrospective study in 594 patients that reported predictors of intraoperative and postoperative outcomes, there were sixteen patients (representing 2.7% of the entire initial cohort) who underwent neuroblastoma surgery [11].

We aimed to describe intraoperative and postoperative outcomes in a specific surgery, namely neuroblastoma surgical patients included in the initial study as a secondary analysis since in the initial study we emphasized more on predictors of adverse outcomes [12]. The secondary objective of this analysis was to propose intraoperative management for optimal postoperative outcome in this surgical setting where intraoperative cardiocirculatory instability, blood loss and fluid therapy requirements can be high. Echocardiography is a validated tool in children for fluid responsiveness assessment and fluid therapy [12] [13] [14] [15] [16]. We have elaborated a research protocol with echocardiography to guide fluid and hemodynamic therapy in pediatric surgical patients [17]. This research protocol has the objective to clarify the impact of goal directed fluid and hemo-

dynamic therapy with echocardiography on postoperative outcome in pediatric surgical patients [17].

2. Methods and Materials

A secondary analysis of patients who underwent neuroblastoma surgery was included in the initial study and described in this manuscript [11].

The study was approved by the Ethics Committee of Necker Enfants Malades University Hospital under the registration number 2017-CK-5-R1 on 21 March 2017.

Patients were retrospectively included from 1 January 2014 to 17 May 2017 by analyzing medical records.

Figure 1 illustrates the inclusion and exclusion flow chart.

The inclusion criteria were patients who underwent neuroblastoma resection aged less than 18 years old and who were included in the initial study.

The exclusion criteria were patients who did not undergo neuroblastoma surgery and aged more than 18 years old included in the initial study.

Outcomes were defined in terms of intraoperative and postoperative organ dysfunction, infection or sepsis, length of stay in the intensive care unit (LOSICU), length of hospital stay in the standard hospitalization ward (LOS), total length of hospital stay (TLOS = LOSICU + LOS), duration of mechanical ventilation (LMV) and transfusion. Patients were followed-up until they were discharged from hospital. Organ dysfunction and sepsis were defined per system with clinical, laboratory and imaging findings as a state of organ alteration that was not present in the preoperative period or present preoperatively with postoperative deterioration or increase. Multiple organ dysfunction or multiple organ sepsis was defined as a state of more than one organ alteration with clinical, laboratory, and/or imaging findings.

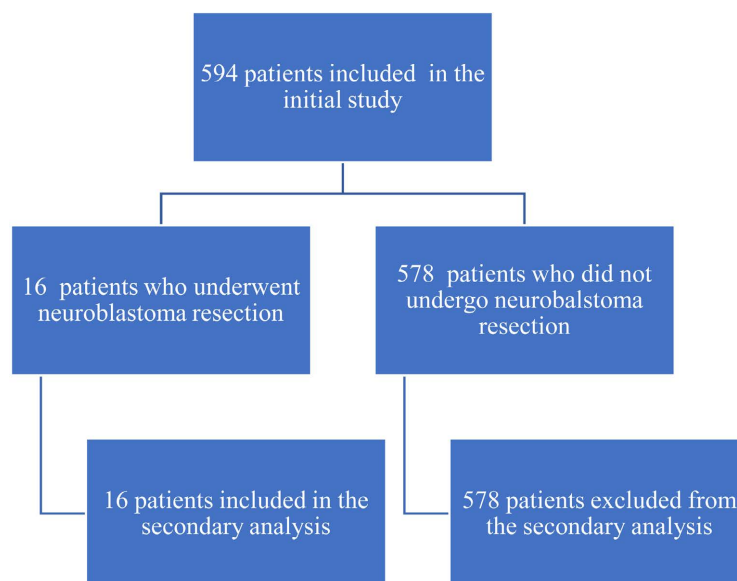


Figure 1. Inclusion and exclusion criteria flow chart.

Preoperative, intraoperative and postoperative patient management: In our hospital, patients who were scheduled for catecholamine-secreting neuroblastoma surgery were managed according to a defined protocol described here.

Preoperatively, patients had prazosin at 0.015 mg/kg to 0.5 mg/kg/day administered three times orally (as a maximum prazosin dose of 5 mg × 3/day).

Labetalol could be administered at 5 to 15 mg/kg/day in 2 - 3 times orally or 0.5 - 1 mg/kg/h as an intravenous (IV) infusion in cases of secondary tachycardia with alpha-blocking agents.

Acetabutozolol could be administered at 5 - 15 mg/kg/day twice in cases of secondary tachycardia with alpha-blocking agents or refractory hypertension.

Nicardipine could be administered preoperatively as an intravenous (IV) infusion at 0.5 - 2 µg/kg/minute for refractory hypertension.

Surgery was scheduled at least 14 days after antihypertensive therapy was started and hypertension controlled. All patients had a preoperative echocardiography, a complete blood cell count, coagulation tests depending on the patient's status, blood urea nitrogen, creatinine plasmatic levels, complete plasmatic electrolyte levels, available cross-match and packed red blood cells in case of intraoperative transfusion.

Before induction of anesthesia, an intravenous peripheral line was available.

Induction of anesthesia was performed in a smooth manner with sevoflurane in a mixture of air and oxygen and intravenous sufentanil at a 0.2 µg/kg bolus. Airway was secured with endotracheal intubation. Maintenance of anesthesia was performed with sevoflurane in air-oxygen, IV sufentanil at 0.05 µg/kg bolus, muscle relaxation for surgical reasons could be performed with IV cisatracurium at 0.15 mg/kg or atracurium at 0.5 mg/kg or rocuronium at 0.6 mg/kg bolus.

Antibiotic therapy was performed with cefazolin as 50 mg/kg intravenously.

Two large-bore peripheral intravenous lines were inserted, and an indwelling bladder catheter, nasogastric tubing, a central core temperature probe, and a muscle relaxation monitoring device were inserted. All patients had a rapid fluid infusion pump and a fluid warming device available.

After the induction of anesthesia, an arterial catheter and a central venous line were inserted. According to the surgical technical approach (laparotomy versus laparoscopy), an epidural catheter or paravertebral catheter was inserted for intraoperative and postoperative analgesia. Analgesia with an epidural catheter or paravertebral catheter was performed with ropivacaine 0.2% or 0.1% or levobupivacaine 0.125% or 0.0625% at 0.2 - 0.3 ml/kg/h (low concentrated local anesthetics were reserved for children less than 10 kg).

Intraoperatively, intravenous urapidil was administered at 2 mg/kg/h as a starting infusion dose and at 0.8 mg/kg/h as a maintenance infusion dose to manage hypertension.

Intravenous esmolol in cases of tachycardia or refractory hypertension could be started as an infusion at 25 - 200 µg/kg/h.

Intravenous labetalol as an infusion at 0.25 - 2 mg/kg/h could be administered as an alternative to urapidil or esmolol.

Intraoperative fluid therapy with crystalloids (Ringer Lactate® or chloride sodium 0.9%) or with colloids (plasmion® or voluven®) was managed with the aims of avoiding catecholamine-induced hypovolemia, vasodilation due to antihypertensive medications and hypotension after tumor resection.

Glycemia was monitored, and 5% glucose-containing crystalloids were administered to avoid hypoglycemia after tumor resection.

Postoperative analgesia was performed with IV acetaminophen 15 mg/kg/6h, epidural or paravertebral catheter with ropivacaine 0.2% or 0.1% or levobupivacaine 0.125% or 0.0625% at 0.1 - 0.2 ml/kg/h (low concentrated local anesthetics were reserved for children less than 10 kg), IV nalbuphine at 0.2 mg/kg/6h or IV morphine as patient-controlled analgesia bolus if necessary.

Patients were extubated in the operating room and transferred to the postinterventional care unit and afterwards to the pediatric intensive care unit for surveillance.

Statistics were analyzed with XLSTAT 2020.4.1 software. Continuous variables were expressed as medians with ranges or means with standard deviations. Category variables were described in proportions.

3. Results

Table 1 illustrates general characteristics.

There were 16 patients with a mean age of 39.3 ± 22.1 months and a median weight of 13 [5.2 - 22] kilograms. There were one (6.3%), three (18.8%), and twelve (75%) ASA grade 1, 2 and 3 patients, respectively. All patients had elective surgery. There were no reoperations. Seven (43.8%) patients presented with intraoperative or postoperative complications. One (6.3%) patient had intraoperative broncho-laryngospasm and difficult intubation. Two (12.5%) patients had intraoperative hemorrhagic shock. One patient (6.3%) had postoperative renal failure. Two patients (12.5%) had postoperative respiratory failure, and 3 (18.8%) patients had postoperative cardiocirculatory failure. One (6.3%) had postoperative pulmonary sepsis and septicemia. Thirteen (81.3%) patients were intraoperatively transfused with packed red blood cells (PRBCs) and/or fresh frozen plasma (FFP) and/or concentrated platelet units (CUPs). There was no in-hospital mortality.

The mean preoperative and postoperative hemoglobin levels were 10.1 ± 0.9 g/dL and 11.1 ± 2.2 g/dL, respectively. The median crystalloid and colloid volumes were 1300 [100 - 2900] ml and 305 [60 - 1000] ml, respectively. The median LOSICU was 7 [0 - 16] days. The median LOS was 8.5 [1 - 17] days. The median TLOS was 15 [3 - 33] days. The median LMV was 0.5 [0 - 5] days.

Table 2 illustrates co-morbidities.

The most common comorbidity was cancer in eight (50%) patients, followed by chronic renal failure in one (6.3%) patient.

Table 1. General characteristics.

Characteristic	N = 16
Mean age \pm standard deviation in months	39.3 \pm 22.1
Median weight [range] in kilograms	13 [5.2 - 22]
ASA I n (%)	1 (6.3)
ASA II n (%)	3 (18.8)
ASA III n (%)	12 (75)
Emergency surgery n (%)	0 (0)
Elective surgery n (%)	16 (100)
Re-operation n (%)	0 (0)
Patients with intra-operative and or postoperative complications (organ failure or sepsis) n (%)	7 (43.8)
Intraoperative broncho-laryngospasm n (%)	1 (6.3)
Intraoperative difficult intubation n (%)	1 (6.3)
Intraoperative hemorrhagic shock n (%)	2 (12.5)
Postoperative renal failure n (%)	1 (6.3)
Postoperative cardio-circulatory failure n (%)	3 (18.8)
Postoperative respiratory failure n (%)	2 (12.5)
Postoperative pulmonary sepsis n (%)	1 (6.3)
Postoperative septicemia n (%)	1 (6.3)
In-hospital mortality n (%)	0 (0)
Transfusion n (%)	13 (81.3)
Median packed red blood cells volume in ml [range]	1 [0 - 2]
Median fresh frozen plasma volume in ml [range]	0 [0 - 5]
Median concentrated platelet units [range]	0 [0 - 1]
Mean preoperative hemoglobin levels \pm standard deviation in g/dL	10.1 \pm 0.9
Mean postoperative hemoglobin levels \pm standard deviation in g/dL	11.1 \pm 2.2
Median crystalloid volume in ml [range]	1300 [100 - 2900]
Median colloid volume in ml [range]	305 [60 - 1000]
Median length of intensive care unit stay in days [range]	7 [0 - 16]
Median length of hospital stay in days [range]	8.5 [1 - 17]
Median total length of hospital stay in days [range]	15 [3 - 33]
Median total length of mechanical ventilation in days [range]	0.5 [0 - 5]

Table 2. Co-morbidities.

Co-morbidity	Number of patients (%)
Cancer	8 (50)
Chronic renal failure	1 (6.3)

4. Discussion

43.8% of the patients presented intraoperative and or postoperative complications as organ dysfunction or infection. 81.3% of the patients were transfused intraoperatively with packed red blood cells or fresh frozen plasma or with platelets. Intraoperative patient management in neuroblastoma surgery can be a challenging situation because of the possible hemodynamic instability that can be observed in catecholamine-secreting tumors, due to the anatomic position of the tumor, which can be near great vessels with possible increased blood loss and transfusion requirements during surgery. Intraoperative fluid and hemodynamic therapy guided with validated tools in children could be mandatory in this surgical setting. Esophageal Doppler probes and transthoracic echocardiography to assess fluid responsiveness with aortic peak flow velocity are validated tools in children and could be integrated in intraoperative patient management in this setting [12]-[17]. Non-optimal regional renal oxygen saturation, cerebral oxygen saturation (as assessed with near infrared spectroscopy NIRS), lactate levels and mixed central venous oxygen saturation values have been correlated with adverse postoperative outcomes in terms of morbidity, mortality and LOS in children; thus, these parameters should be part of the monitoring in neuroblastoma surgery [18].

Neuroblastoma resection is a potential hemorrhagic surgery, as illustrated by the results of this study, where the transfusion rate was high. Transfusion goal-directed therapy with point-of-care viscoelastic assays needs to be part of patient blood management in this surgery to optimize blood product administration and postoperative outcome in terms of morbidity and LOS [19] [20] [21] [22]. As described previously in other potential hemorrhagic surgeries, point-of-care viscoelastic methods serve as a guide to transfuse the right product at that right time with results available within five to ten minutes, which is faster than conventional coagulation tests [23] [24] [25] [26].

Intraoperative goal-directed therapies with validated tools need to be part of patient management in major surgery in children for intraoperative and postoperative optimization [27]-[32].

In adult surgical patients, goal-directed fluid and hemodynamic therapy improved postoperative outcomes in terms of morbidity, mortality and length of hospital stay in high risk patients and surgery [33]. In children goal-directed fluid and hemodynamic therapy is not well developed and there are no studies to date that have shown its impact on postoperative outcomes in children. Goal-directed therapies include fluid and hemodynamic therapy with validated tools in children, transfusion protocols guided with point-of-care tests. These therapies aim to optimize the relation between oxygen consumption and oxygen delivery [34] [35]. Cardiac output and hemoglobin levels are among other determinants of oxygen delivery. We aimed with this secondary analysis to propose a research protocol where goal-directed fluid and hemodynamic therapy will be guided with trans-thoracic echocardiography [17]. This research protocol has

the objective to clarify the impact of goal-directed fluid and hemodynamic therapy with echocardiography on postoperative outcomes in pediatric surgical patients. The aim of goal-directed fluid and hemodynamic therapy with echocardiography is to optimize cardiac output, a determinant of oxygen delivery.

The limit of this secondary analysis was the sample size and the strength was the homogeneity of the analyzed population, namely neuroblastoma surgical pediatric patients.

5. Conclusions

Neuroblastoma surgery can be a challenging situation where cardiovascular instability, high blood loss and transfusion requirements can be encountered. Consequently, preoperative preparation and optimal intraoperative management with validated means in children could be necessary for a better postoperative outcome. We have conceptualized a research protocol where goal-directed fluid and hemodynamic therapy will be guided with transthoracic echocardiography intraoperatively.

This research protocol will clarify the impact of this therapy on postoperative outcomes in pediatric surgical patients.

Author Contributions

Claudine Kumba conceptualized and designed the study and drafted the initial manuscript. She designed the data collection instruments, collected data, carried out initial and final analyses.

Presentation of Preliminary Results

This manuscript has been registered as a preprint under the DOI identification number <https://doi.org/10.21203/rs.3.rs-785499/v2> on Research Square, a preprint platform.

Ethics Approval

This study received approval from the Ethics Committee of Necker on 21 March 2017 under registration number 2017-CK-5-R1 and waived patient consent.

Conflicts of Interest

The author declared no conflicts of interest.

References

- [1] Hallett, A. and Traunecker, H. (2011) A Review and Update on Neuroblastoma. *Paediatrics and Child Health*, **22**, 103-107. <https://doi.org/10.1016/j.paed.2011.08.005>
- [2] Colon, N.C. and Chung, D.H. (2011) Neuroblastoma. *Advances in Pediatrics*, **58**, 297-311. <https://doi.org/10.1016/j.yapd.2011.03.011>
- [3] Gomez-Rios, M.A., Nuno, F.C. and Barreto-Calvo, P. (2017) Anesthetic Manage-

- ment of an Infant with Giant Abdominal Neuroblastoma. *Brazilian Journal of Anesthesiology*, **67**, 210-213. <https://doi.org/10.1016/j.bjane.2014.07.012>
- [4] Louis, C.U. and Shohet, J.M. (2015) Neuroblastoma: Molecular Pathogenesis and Therapy. *Annual Review of Medicine*, **66**, 49-63. <https://doi.org/10.1146/annurev-med-011514-023121>
- [5] Schengrund, C.L. (2020) Gangliosides and Neuroblastomas. *International Journal of Molecular Sciences*, **21**, Article No. 5313. <https://doi.org/10.3390/ijms21155313>
- [6] Liu, T., Lv, Z., Xu, W., Liu, J. and Sheng, Q. (2020) Role of Image-Defined Risk Factors in Predicting Surgical Complications of Localized Neuroblastoma. *Pediatric Surgery International*, **36**, 1167-1172. <https://doi.org/10.1007/s00383-020-04731-y>
- [7] Malek, M., Mollen, K.P., Kane, T.D., Shah, S.R. and Irwin, C. (2010) Thoracic Neuroblastoma: A Retrospective Review of Our Institutional Experience with Comparison of the Thoracoscopic and Open Approaches to Resection. *Journal of Pediatric Surgery*, **45**, 1622-1626. <https://doi.org/10.1016/j.jpedsurg.2010.03.018>
- [8] Cheung, S.L.W. and Lerman, J. (1998) Mediastinal Masses and Anesthesia in Children. *Anesthesiology Clinics of North America*, **16**, 893-910. [https://doi.org/10.1016/S0889-8537\(05\)70068-7](https://doi.org/10.1016/S0889-8537(05)70068-7)
- [9] Kumba, C. (2019) Pheochromocytoma, Paraganglioma, Neuroblastoma, Catecholamine Secreting Tumor Perioperative and Anesthetic Management in Children. *International Journal of Pediatrics & Neonatal Care*, **5**, Article ID: IJPNC-156. <https://doi.org/10.15344/2455-2364/2019/156>
- [10] Stricker, P.A., Gurnaney, H.G. and Litman, R.S. (2010) Anesthetic Management of Children with an Anterior Mediastinal Mass. *Journal of Clinical Anesthesia*, **22**, 159-163. <https://doi.org/10.1016/j.jclinane.2009.10.004>
- [11] Kumba, C., Cresci, F., Picard, C., Thiry, C., Albinni, S., *et al.* (2017) Transfusion and Morbi-Mortality Factors: An Observational Descriptive Retrospective Pediatric Cohort Study. *Journal of Anesthesia & Critical Care. Open Access*, **8**, Article No. 00315. <https://doi.org/10.15406/jaccoa.2017.08.00315>
- [12] Tibby, S.M., Durward, A. and Murdoch, I.A. (2001) Are Transoesophageal Doppler Parameters a Reliable Guide to Paediatric Haemodynamic Status and Fluid Management? *Intensive Care Medicine*, **27**, 201-205. <https://doi.org/10.1007/s001340000795>
- [13] Murdock, I.A., Marsh, M.K., Tibby, S.M. and McLuckie, A. (1995) Continuous Haemodynamic Monitoring in Children: Use of Transoesophageal Doppler. *Acta Paediatrica*, **84**, 761-764. <https://doi.org/10.1111/j.1651-2227.1995.tb13751.x>
- [14] Weber, T., Wagner, T., Neumann, K. and Deusch, E. (2015) Low Predictability of Three Different Noninvasive Methods to Determine Fluid Responsiveness in Critically Ill Children. *Pediatric Critical Care Medicine*, **16**, e89-e94. <https://doi.org/10.1097/PCC.0000000000000364>
- [15] Gan, H., Cannesson, M., Chandler, J.R. and Ansermino, J.M. (2013) Predicting Fluid Responsiveness in Children: A Systematic Review. *Anesthesia & Analgesia*, **117**, 1380-1392. <https://doi.org/10.1213/ANE.0b013e3182a9557e>
- [16] Pereira de Souza Neto, E., Grousson, S., Duflo, F., Ducreux, C., Joly, H., Convert, J., *et al.* (2011) Predicting Fluid Responsiveness in Mechanically Ventilated Children under General Anaesthesia Using Dynamic Parameters and Transthoracic Echocardiography. *British Journal of Anaesthesia*, **106**, 856-864. <https://doi.org/10.1093/bja/aer090>
- [17] Kumba, C. (2020) Goal Directed Fluid and Hemodynamic Therapy and Postopera-

- tive Outcomes in Children: Value of Transthoracic Echocardiographic Aortic Blood Flow Peak Velocity Variation: A Multi-Centre Randomized Controlled Trial Protocol. *Advances in Pediatric Research*, **7**, Article No. 35. <https://doi.org/10.35248/2385-4529.20.7.35>
- [18] Kumba, C., Willems, A., Querciagrossa, S., Harte, C., Blanc, T., De Cock, A., *et al.* (2019) A Systematic Review and Meta-Analysis of Intraoperative Goal Directed Fluid and Haemodynamic Therapy in Children and Postoperative Outcome. *Journal of Emergency and Critical Care Medicine*, **5**, 1-9. <https://doi.org/10.13188/2469-4045.1000020>
- [19] El Kenz, H. and Van der Linden, P. (2014) Transfusion-Related Acute Lung Injury. *European Journal of Anaesthesiology*, **31**, 345-350. <https://doi.org/10.1097/eja.0000000000000015>
- [20] Mulder, H.D., Augustijn, Q.J., Van Woensel, J.B., Bos, A.P., Juffermans, N.P. and Wösten-van Asperen, R.M. (2015) Incidence, Risk Factors, and Outcome of Transfusion-Related Acute Lung Injury in Critically Ill Children: A Retrospective Study. *Journal of Critical Care*, **30**, 55-59. <https://doi.org/10.1016/j.jcrc.2014.10.005>
- [21] Muszynski, J.A., Spinella, P.C., Cholette, J.M., Acker, J.P., Hall, M.W., Juffermans, N.P., *et al.* (2016) Transfusion-Related Immunomodulation: Review of the Literature and Implications for Pediatric Critical Illness. *Transfusion*, **57**, 195-206. <https://doi.org/10.1111/trf.13855>
- [22] Kumba, C., Querciagrossa, S., Harte, C., Willems, A., De Cock, A., *et al.* (2019) A Systematic Review and Meta-Analysis of Goal Directed Intra-Operative Transfusion Protocols Guided by Viscoelastic Methods and Perioperative Outcomes in Children. *International Journal of Recent Scientific Research*, **10**, 31466-31471.
- [23] Kumba, C. (2022) Liver Transplantation in Children and Impact of Intraoperative Goal-Directed Therapies on Postoperative Outcome. *SOJ Pedia Clin Neonato.*, **2**, 1-7. <https://doi.org/10.21203/rs.3.rs-744584/v1>
- [24] Kumba, C. and Miladi, L. (2021) Scoliosis in Children: Impact of Goal-Directed Therapies on Intraoperative and Postoperative Outcomes. *Open Journal of Orthopedics*, **11**, 315-326. <https://doi.org/10.4236/ojo.2021.1110030>
- [25] Kumba, C. (2021) Patient Blood Management in Craniostomosis Surgery. *Open Journal of Modern Neurosurgery*, **11**, 211-222. <https://doi.org/10.4236/ojmn.2021.114025>
- [26] Kumba, C., Gaume, M., Barbarian, A. and Péjin, Z. (2021) Intraoperative Goal-Directed Therapies in Femoral and Pelvic Osteotomies in Children and In-Hospital Postoperative Outcomes. *Open Journal of Orthopedics*, **11**, 327-334. <https://doi.org/10.4236/ojo.2021.1111031>
- [27] Kumba, C. (2021) Postoperative Complications after Major Abdominal Surgery in Preterm Infants: A Single Institute Record. *Open Journal of Pediatrics*, **11**, 413-420. <https://doi.org/10.4236/ojped.2021.113039>
- [28] Kumba, C., *et al.* (2021) Postoperative Outcome in Non-Preterm Infants Under One Year Old in Non-Cardiac Surgery. *Acta Scientific Paediatrics*, **4**, 11-23. <https://doi.org/10.31080/ASPE.2021.04.0432>
- [29] Kumba, C. (2021) Children Aged between 1 and 3 Years in Noncardiac Surgery and Postoperative Outcome. *EC Paediatrics*, **10**, 67-74.
- [30] Kumba, C. (2021) Postoperative Outcome in Children Aged between 3 and 6 Years in Abdominal Surgery, Neurosurgery and Orthopedics. *Pediatric Anesthesia and Critical Care Journal*, **9**, 43-47. <https://doi.org/10.14587/paccj.2021.7>
- [31] Kumba, C. (2021) Postoperative Outcome in Children aged between 6 and 10 Years

- in Major Abdominal Surgery, Neurosurgery and Orthopedic Surgery. *Open Journal of Pediatrics*, **11**, 636-645. <https://doi.org/10.4236/ojped.2021.114059>
- [32] Kumba, C. (2021) Major Abdominal Surgery, Neurosurgery, Orthopedic Surgery in Children Aged between 10 and 18 Years and Postoperative Outcome. *SOJ Pediatrics and Clinical Neonatology*, **1**, Article No. 000509. <https://doi.org/10.53902/SOJPCN.2021.01.000509>
- [33] Chong, M., Wang, Y., Berbenetz, N. and McConachie, I. (2018) Does Goal-Directed Haemodynamic and Fluid Therapy Improve Peri-Operative Outcomes? A Systematic Review and Meta-Analysis. *European Journal of Anaesthesiology*, **35**, 469-483. <https://doi.org/10.1097/EJA.0000000000000778>
- [34] Kumba, C. (2020) Physiology Principles Underlying Goal Directed Therapies in Children. *Research in Pediatrics & Neonatology*, **4**, Article No. RPN.000591. <https://doi.org/10.31031/RPN.2020.04.000591>
- [35] Kumba, C. (2020) Rationale of Goal Directed Therapies in Children. *Advances in Pediatric Research*, **7**, Article No. 42.