

Radio-Chemotherapy in Pre-Operative Rectal Adenocarcinoma at Dalal Jamm Hospital, Senegal

Mouhamadou Bachir Ba^{1*}, Fatimatou Néné Sarr¹, Adja Coumba Diallo², Maimouna Mané¹, Pape Massamba Diéne¹, Papa Macoumba Gaye¹

¹Radiotherapy Department, Dalal Jamm Hospital, UCAD, Dakar, Senegal

²Saint-Louis Regional Hospital, Saint-Louis, Senegal

Email: *mbbachir21@gmail.com

How to cite this paper: Ba, M.B., Sarr, F.N., Diallo, A.C., Mané, M., Diéne, P.M. and Gaye, P.M. (2021) Radio-Chemotherapy in Pre-Operative Rectal Adenocarcinoma at Dalal Jamm Hospital, Senegal. *Journal of Cancer Therapy*, 12, 221-231. <https://doi.org/10.4236/jct.2021.124021>

Received: March 20, 2021

Accepted: April 26, 2021

Published: April 29, 2021

Copyright © 2021 by author(s) and Scientific Research Publishing Inc. This work is licensed under the Creative Commons Attribution International License (CC BY 4.0).

<http://creativecommons.org/licenses/by/4.0/>



Open Access

Abstract

Background: Radiation therapy is an essential treatment for rectal cancer. In 2018, Senegal experienced a transition from two-dimensional to three-dimensional radiotherapy (RC3D). We are evaluating for the first time the impact of this RC3D in the treatment of rectal cancer in Senegal. **Objective:** To describe the epidemiological, clinical and diagnostic profile of rectum cancer in Senegal, to list the different radiotherapy techniques used, to evaluate the response as well as the outcome of patients. **Method:** We conducted a retrospective descriptive study on preoperative radio-chemotherapy of rectal adenocarcinoma at the Dalal Jamm University Hospital in Dakar from July 2018 to June 2020. **Results:** The 42 patients included, including 18 men and 24 women (Sex Ratio: 0.75), had an average age of 55.9 years. We found a family history of CRC (Colorectal cancer) in 7 cases and smoking in 5 cases. The clinical signs were dominated by rectal bleeding, noted in 92.8% of cases, with or without pain, and changes in transit in 57.1% and 50% respectively. The tumor was perceptible on digital rectal examination (DRE) in 76.1%. All patients had undergone endoscopy, which revealed a budding aspect in 69% of cases. The preferred location was the lower rectum (59.5%). The predominant histological type was liberkhunian adenocarcinoma (85.7%). T3 and T4 tumors accounted for 30.9% and 21.4% of cases respectively and stage III was predominant, 69%. The aim of radiotherapy was curative in 33 patients and palliative in 9 patients. Curative radiotherapy was preoperative in 29 patients and adjuvant in 2 patients. RC3D was the technique used in all our patients and the total dose of 50.4 Gy in 28 sessions of 5 days per week was the most used (69%). The incidents noted during radiotherapy were 12 cases of radiodermatitis, 15 cases of diarrhea, and no severe toxicity was noted. Thirty-one patients underwent surgery, 16 with anterior resection of the rectum and 3 with total proctectomy; the sphincter preservation rate was 61.2%. The surgical

resection was carcinological (R0) in 26 patients and microscopically incomplete (R1) in 5 patients. Post-operative evaluation of the pathological specimen showed a complete histological response in 21% of cases. The evolution was marked by a progressive disease in 4 cases, local recurrence in 3 cases, metastatic recurrence in 4 cases, death in 8 cases and remission in 23 cases. The average follow-up of our patients was 17.3 months. **Conclusion:** Rectal cancer is diagnosed late in Senegal; surgery remains the cornerstone of treatment. Radiotherapy increases the resectability and local control.

Keywords

Cancer, Rectum, Radiotherapy, Senegal

1. Introduction

Rectal cancer represents about 40% of colorectal cancers, or nearly 6% of all cancers [1]. In Africa, colorectal cancer is the 6th most common cancer, with a mortality rate of 4.4% in Senegal [2]. The strategy and therapeutic means dedicated to this cancer have evolved in the last decade. Surgery has been the historical curative treatment. The technique of total removal of the mesorectum (TME) has improved the local control rate and overall survival at five years to 65%, although local recurrence occurs in 10% to 20% of cases [3]. Preoperative radiotherapy has become a standard for locally advanced and operable tumors over the last two decades [4]. It decreases the recurrence rate from 30% to 9% [5] and increases the overall survival at 5 years from 48% to 58% [6]. We conducted a retrospective descriptive study, between July 2018 and June 2020, including 42 patients treated with radiotherapy for rectal adenocarcinoma at the radiotherapy department of the Dalal Jamm hospital in Dakar. The objective of our study was to describe in our context, the epidemiological, clinical and diagnostic profile of rectal cancer as well as to evaluate the place of radiotherapy in the treatment of rectal cancers. This retrospective study evaluating the management of rectal cancer with a modern radiotherapy technique (RC3D) is the first in our context and more generally in French-speaking West Africa countries where the transition from 2D radiotherapy to RC3D is being carried out recently.

2. Patients and Methods

The study was carried out at the Oncology-Radiotherapy Department of the Dalal Jamm University Hospital in Dakar between July 2018 and June 2020. It is equipped with two linear accelerators using a three-dimensional conformal technique, a brachytherapy and chemotherapy unit

2.1. Patients

All rectal adenocarcinoma files have been collected.

All records of patients with a histological diagnosis of rectal adenocarcinoma and treated with radiotherapy (curative or palliative) were included. Excluded were all records of patients whose histological diagnosis was not adenocarcinoma and all rectal adenocarcinoma lost after the first consultation and those who do not received radiotherapy. Using a data sheet, we studied the epidemiological, diagnostic, therapeutic and evolutionary data of the disease in all the selected patients. The objective was to describe the epidemiological, clinical and diagnostic profile of rectal cancer in Senegal, to list the different radiotherapy techniques used, to evaluate the response as well as the outcome of the patients.

We used the UICC classification (TNM 8th edition 2017); radiotherapy had used a three-dimensional conformal technique with 4 to 6 beams. Our dose constraints were thus set (**Table 1**). Post-radiotherapy evaluation was clinical and radiological according to RECIST criteria [7]. Complete histological response was defined by the absence of living tumors cells on the pathological reports.

2.2. Treatment

All patients received treatment by radiation therapy (curative/palliative) associated either with chemotherapy (neoadjuvante/adjuvant/Concomitant) or with surgery.

2.3. Follow-up

All patients were seen in consultation 1 and every 4 month after treatment or contacted by telephone for those who did not show up for their appointment.

2.4. Statistical Analysis

Data were entered into Epi Info from the Mosaiq medical records and analyzed in Microsoft Excel 2016. The categorical variables were calculated in mean, median. Non-categorical variables in number and percentage.

3. Results

We collected 62 consecutive cases of rectal adenocarcinoma during the study period. We selected 42 cases for this study. The mean age of our patients was 55.9 years, with a M/F sex ratio of 0.75. Smoking intoxication was found in 5 cases and a family history of CRC in 7 patients. The mean time to consultation was 8.9

Table 1. Risk organs and target volumes dose constraints in RC3D.

Risk organs/Target volumes	Dose constraint
bladder	Maximal dose ≤ 80 Gy V60 Gy $< 50\%$
Rectum	V60 Gy $< 50\%$ et/ou V72 Gy $< 25\%$
Femoral heads	V55 Gy $< 5\%$
Peritoneal sac	V45 Gy < 200 cc
Planning target volume (PTV)	$95\% < \text{PTV} < 107\%$

months. Symptomatology was dominated by rectal bleeding, found in 92.8% of cases, isolated or associated with pain in 57.1%, transit disorders in 50% of cases and a rectal syndrome in 50% of cases. The tumor was perceptible on DRE in 76.1% of the patients, circumferential in 22 cases, hemi-circumferential in 9 patients and stenosing in 10 cases (23.8%). The distance between the lower pole of the tumors and the anal margin was specified in 69% of cases and averaged 3.9 cm. The tumor was located in the lower rectum in 25 patients (59.5%), the middle rectum in 10 cases (23.8%), and the upper rectum in 7 cases (16.6%). The tumor was ulcerative in 11 cases (26.1%), budding in 29 cases (69%) and pedunculated polypoid in 2 cases (4.7%). Liberkhunian adenocarcinoma was the most frequent form with 85.7% of cases. It was well differentiated in 50% of cases, poorly differentiated in 26% of cases and moderately differentiated in 19% of cases. Seventeen patients (40.4% of the cases) had magnetic resonance imaging (MRI), 41 patients (97.6%) had thoracoabdomino-pelvic CT scans and one patient had a chest X-ray and an abdominal ultrasound. T3 and T4 tumours predominated in 30.9% and 21.4% of cases respectively. Stage III was predominant, accounting for 69% of cases. Chemotherapy was systemic neoadjuvant in 17 patients (40.4%) and concomitant with radiotherapy in 35 patients (83.3%). Adjuvant chemotherapy had been performed in 5 patients. The objective response to neoadjuvant chemotherapy was 82%. All our patients received external radiotherapy. The therapeutic strategy including radiotherapy was curative in 78.5% of cases and palliative in 21.4% of patients. Curative radiotherapy was preoperative in 29 patients and adjuvant in 2 cases. Three-dimensional conformal radiotherapy was the technique used in all our patients. The total dose of 50.4 Gy in 28 sessions of 5 days per week was the most used, found in 29 patients (69%), the total dose of 45 Gy in 25 sessions in 5 patients (11.9%), the total dose of 50 Gy in 25 sessions in 1 patient (2.3%) while the total dose of 39 Gy in 13 sessions in 6 patients (14.2%). Only one patient received a total dose of 25 Gy in 5 sessions of one week. Four-beam irradiation was performed in 29 patients, five-beam in 12 patients and six-beam in 1 patient. Complications of treatment were marked by grade I radiodermatitis in 9 patients, grade II in 3 patients, grade I diarrhea in 11 cases and grade II in 4 cases and cystitis in 7 patients. Post-operative radio-chemotherapy evaluation by DRE and IRM was performed in 14 patients and showed an objective clinical and radiological response in terms of tumor fixity (78.5%), circumferential extension (71.4%), distance from the lower pole of the tumor to the anal margin (85.7%) and the possibility of sphincter preservation (78.5%) (**Table 2**) The mean time from preoperative radio chemotherapy to surgery was 10.2 weeks (range 6 - 15 S). Surgery was performed in 31 patients (73.8%). It was a first surgery in 2 patients (4.7%) and post radio-chemotherapy in 29 patients (69%). The surgical techniques used were elective discharge colostomy in 10 cases, abdominoperineal amputation (APA) in 12 patients (38.7%), anterior rectal resection (ARR) in 16 patients (51%) and total proctectomy (TP) in 3 patients

(9.6%). The sphincter preservation rate was 61.2%. The surgical resection was carcinological (R0) in 26 patients and microscopically incomplete (R1) in 5 patients. Post-operative evaluation of the pathological specimen of the 29 patients who received concomitant radio-chemotherapy showed a complete histological response in 21%, partial in 76% and no response in 3% of cases (**Figure 1**). The patients who received palliative radiotherapy for haemostatic, analgesic and local control purposes, including 6 cases with hypofractionation (39 Gy/13fractions) and 3 cases with conventional fractionation (45 Gy), had an estimated 60% symptoms resolution. The follow-up of our patients was 17.3 months (12.4) with extremes of 6 months for the minimum and 26 months for the maximum. During this period of follow up, 23 patients or 55% of the cases were in remission without recurrence, 4 patients had a continuation of the disease, 7 patients had a recurrence and 8 patients died (**Figure 2**).

Table 2. Data from TR and IRM post -radio-chemotherapy pre-operatively.

	Number of people	Percentage (%)
Tumor fixation		
Yes	3	21.4%
No	11	78.5%
Circumferential extension		
>50%	4	28.5%
<50%	10	71.4%
Distance of lower pole and anal margin		
>5 cm	12	85.7%
<5 cm	2	14.2%
Sphincter conservation		
Yes	11	78.5%
No	3	21.4%

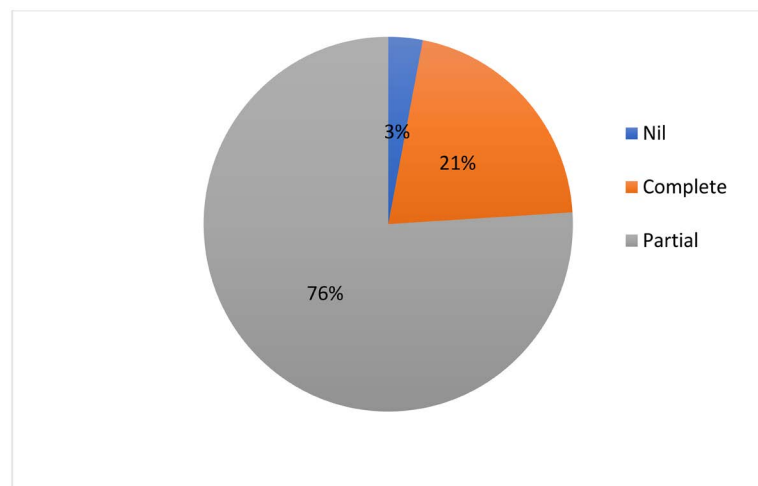


Figure 1. Results of response to pre-operative radio-chemotherapy on anatomopathological specimen.

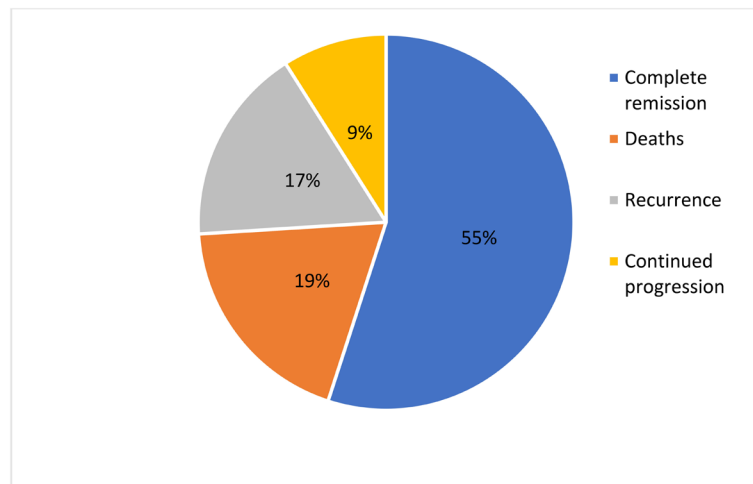


Figure 2. Treatment results in our series.

4. Discussion

The epidemiology of rectal cancer is inseparably linked with that of the colon. Colorectal cancer (CRC) is a major public health problem in some parts of the world such as North America, Europe and Oceania [8]. Despite this clear increase of incidence in Western countries, CRC is classically rare in South America, Asia and Africa [9] [10]. However, it is not exceptional and several series have been published [11] [12]. In Africa, rectal cancer occurs at a young age with an average age of 55.9 years, lower than most western series [9] [13]. Pelvic magnetic resonance imaging has a place of choice in local and locoregional evaluation, especially when neo-adjuvant treatment is envisaged. The rate of completion was 40.4% in our series. These data are higher than those of other African series published to date [11] [12] [14]. This may be explained by the greater availability of MRI and its importance in planning preoperative radiotherapy. Rectal adenocarcinoma is still found at a locally advanced stage in Africa. In our series, stage III accounted for 69% of cases.

Historically, abdominoperineal amputation was the rule for any rectal cancer seen on rectal examination and the rate of sphincter preservation varied from 10% to 30% [15]. This situation has led to studies to increase the chances of conservation without unacceptably increasing the risk of local recurrence while preserving satisfactory anorectal function [16]. As early as the 1990s, two large trials comparing primary surgery and preoperative radiotherapy confirmed the benefit of preoperative radiotherapy: the Swedish randomized trial reported a preservation rate of 41% for the surgery alone arm compared with 44% for the preoperative radiotherapy arm delivering a dose of 25 Gy in five sessions with less than one week between the end of radiotherapy and surgery [5]. The NSABP R.03 trial [17], which involved irradiation with a total dose of 40 to 50 Gy over five weeks and a delay of four to eight weeks before surgery, reported a conservation rate of around 50% for the radiotherapy arm compared with only 33% for the surgery alone arm. Thus, compared to surgery alone, preoperative radiothe-

rapy improves local control with a recurrence rate that falls from 30% to 9% [5] and an overall survival at 5 years from 48% to 58% [6]. The benefit of the addition of concomitant chemotherapy in the case of a long protocol has been demonstrated by two multicenter phase III trials [18] [19]. It increases the histological response rate and halves the local recurrence rate at 5 years compared with radiotherapy alone (8% vs 16%). Capecitabine, which gives results equivalent to those of 5 FU [20], is currently the standard. It gives more compliance with the same efficacy. All our patients received capecitabine orally on the days of radiotherapy. The choice between long chemoradiotherapy or short 25/5 radiotherapy is not clear-cut. A Polish trial [21] showed no difference but reported an unusual local recurrence rate of 16% with long chemoradiotherapy. An Australian trial [22] showed no significant difference in terms of immediate tolerability and a 3-year local recurrence rate of 7.5% after 25/5 and 4.4% after chemoradiotherapy (50.4 Gy/25 sessions) and 5-FU. Finally, the randomized study by Erlandsson *et al.* [23] showed that the short regimen was equivalent to the long regimen in terms of local control. Metastatic relapse-free survival and overall survival were also no different. There is also a so-called “intermediate” protocol with moderate hypofractionation (39 Gy/13 sessions) giving a biological dose equivalence approaching 45 Gy in 25 fractions. The standard remains long chemoradiotherapy, but the short 5 × 5 regimen can also be proposed on multidisciplinary consultation meeting, particularly in certain situations: elderly patients to limit the number of sessions, or metastatic patients to limit the duration without effective chemotherapy on the metastatic disease [24]. In our series, the long protocol was used most in 29 patients (69%) followed by the intermediate protocol in 6 patients (14.2%) and only one patient had benefited from the short protocol. The therapeutic strategy including induction chemotherapy would be interesting in locally advanced cancer, especially since the availability of preoperative radio-chemotherapy in time is often difficult to respect in our context. Induction chemotherapy with doublets or triplets can be discussed for unresectable tumors (T4), especially as the first results of randomized phase II induction chemotherapy are encouraging in terms of toxicity and compliance [25] [26]. Initial chemotherapy does not reduce the efficacy of secondary radio-chemotherapy [25]. The PRODIGE 23 trial, which randomized neoadjuvant polychemotherapy with FOLFIRINOX versus standard treatment, showed a superiority of this strategy with a benefit in terms of progression-free survival at 3 years (68.5% vs 75.7%), the rate of complete histological response (11.7% vs 27.5%), with no difference in surgical morbidity [27]. The RAPIDO trial evaluated the gain in distant metastasis-free survival and overall survival [28]. In our series, 40.4% of patients had neoadjuvant chemotherapy with an objective response of 82%. Three-dimensional conformal radiotherapy (3D-CRT) is the standard technique for rectal cancer. Intensity-modulated conformal radiotherapy can be considered for rectal cancer, especially postoperatively, as this technique offers better organ sparing [29]. All our patients were treated with 3D-CR and no acute grade III toxicity was observed.

Sphincter conservation is only problematic for tumors of the lower rectum in

the following situations where the predicted macroscopic distal margin is less than 1 cm, the predicted lateral margin is sub-millimeter, a juxta-anal tumor without internal sphincter invasion, or internal and external sphincter invasion. Preoperative chemoradiotherapy in the case of a good response may increase the chances of preservation. Several phase 2 trials suggest that it may modify the initial surgical indication in case of a good response and increase the sphincter preservation rate [30] [31]. In our series, the sphincter preservation rate was 61.2%. Since the introduction of preoperative radiotherapy as a standard in locally advanced cancer, this rate varies from 35% to 77% in the literature [11] [32] [33].

After preoperative radio-chemotherapy, a clinical tumor response is observed in 20% - 75% of cases, a histological response is observed in 30% - 60% of cases, and a complete histological response or ypT0 in 15% - 38% of cases [33] [34]. These rates vary depending on the definition of complete response adopted and the radio-chemotherapy protocol used. In our study, the histological complete response was 21%. Despite these results, our study has some limitations, including the relatively small number of patients, the lack of evaluation for all patients by MRI after preoperative radiotherapy. From a surgical point of view, a great variability in indications, techniques and operators is noted as well as the time between the end of preoperative radiotherapy and surgery.

5. Conclusion

Surgery remains the cornerstone of treatment for rectal cancer. Preoperative radio-chemotherapy increases local control, sphincter preservation and overall survival rates. RC3D remains the standard in rectal cancer, due to the relatively low doses indicated, even though IMRT could increase the tolerance of the treatment through significant bowel sparing, especially postoperatively.

Conflicts of Interest

The authors declare no conflicts of interest regarding the publication of this paper.

References

- [1] Dancourt, V. and Faivre, J. (2004) Epidemiology and Screening of Colorectal Cancers: Colorectal Cancers. *La Revue du Praticien*, **54**, 135-142.
- [2] Cancer Today [Internet]. <http://gco.iarc.fr/today/home>
- [3] Heald, R.J., Husband, E.M. and Ryall, R.D.H. (1982) The Mesorectum in Rectal Cancer Surgery—The Clue to Pelvic Recurrence? *British Journal of Surgery*, **69**, 613-616. <https://doi.org/10.1002/bjs.1800691019>
- [4] Valentini, V., Aristei, C., Glimelius, B., Minsky, B., Beets-Tan, R., Borras, J.M., *et al.* (2009) Multidisciplinary Rectal Cancer Management: 2nd European Rectal Cancer Consensus Conference (EURECA-CC2). *Radiotherapy and Oncology*, **92**, 148-163. <https://doi.org/10.1016/j.radonc.2009.06.027>
- [5] Folkesson, J., Birgisson, H., Pahlman, L., Cedermark, B., Glimelius, B. and Gunnars-

- son, U. (2005) Swedish Rectal Cancer Trial: Long Lasting Benefits from Radiotherapy on Survival and Local Recurrence Rate. *Journal of Clinical Oncology*, **23**, 5644-5650. <https://doi.org/10.1200/JCO.2005.08.144>
- [6] Jayne, D.G., Brown, J.M., Thorpe, H., Walker, J., Quirke, P. and Guillou, P.J. (2005) Bladder and Sexual Function Following Resection for Rectal Cancer in a Randomized Clinical Trial of Laparoscopic versus Open Technique. *British Journal of Surgery*, **92**, 1124-1132. <https://doi.org/10.1002/bjs.4989>
- [7] Eisenhauer, E.A., Therasse, P., Bogaerts, J., Schwartz, L.H., Sargent, D., Ford, R., *et al.* (2009) New Response Evaluation Criteria in Solid Tumours: Revised RECIST Guideline (Version 1.1). *European Journal of Cancer*, **45**, 228-247. <https://doi.org/10.1016/j.ejca.2008.10.026>
- [8] Colorectal Cancer—The Most Common Cancers [Internet]. <https://www.e-cancer.fr/Professionnels-de-sante/Les-chiffres-du-cancer-en-France/Epidemiologie-des-cancers/Les-cancers-les-plus-frequents/Cancer-colorectal>
- [9] Faivre, J., Bouvier, A.-M. and Bonithon-Kopp, C. (2002) Epidemiology and Screening of Colorectal Cancer. *Best Practice & Research: Clinical Gastroenterology*, **16**, 187-199. <https://doi.org/10.1053/bega.2001.0280>
- [10] New Global Cancer Data: GLOBOCAN 2018. UICC [Internet]. <https://www.uicc.org/news/new-global-cancer-data-globocan-2018#>
- [11] Dieng, M.M. (2019) Radiotherapy of Rectal Cancer: A Single-Centre Study in an African Cancer Institute, Institute Joliot Curie, Dakar, Senegal. *Revue Africaine de Médecine Interne*, **6**, 33-42.
- [12] Ebo, E.U. (2017) Rectal Cancer: Experience of the Oncology Surgery Department of the Hassan II Oncological Centre (A Propos de 83 Cases). These de Doctorat en Medecine, Sidi Ben Mohammed Abdallah University of Féz, Féz.
- [13] Boutron, R.M.C. and Laurant, P.P. (2005) Epidemiology, Carcinogenesis, Risk Factors, Prevention and Screening of Colorectal Cancer. *Traité Gastro-Entérologie*, 538-550.
- [14] Benani, I. (2017) Radiosurgical Treatment of Rectal Cancer at the Joliot (Curie) Institute in Dakar. Retrospective Study of 50 Cases. These de Doctorat en Medecine, UCAD, Dakar.
- [15] Maggiori, L. and Panis, Y. (2012) What Are the Right Indications for Radiochemotherapy in Rectal Cancer? *Colon Rectum*, **6**, 74-78. <https://doi.org/10.1007/s11725-012-0371-4>
- [16] Boulis-Wassif, S., Gerard, A., Loygue, J., Camelot, D., Buyse, M. and Duez, N. (1984) Final Results of a Randomized Trial on the Treatment of Rectal Cancer with Preoperative Radiotherapy Alone or in Combination with 5-Fluorouracil, Followed by Radical Surgery Trial of the European Organization on Research and Treatment of Cancer Gastrointestinal Tract Cancer Cooperative Group. *Cancer*, **53**, 1811-1818. [https://doi.org/10.1002/1097-0142\(19840501\)53:9<1811::AID-CNCR2820530902>3.0.CO;2-H](https://doi.org/10.1002/1097-0142(19840501)53:9<1811::AID-CNCR2820530902>3.0.CO;2-H)
- [17] Hyams, D.M., Mamounas, E.P., Petrelli, N., Rockette, H., Jones, J., Wieand, H.S., *et al.* (1997) A Clinical Trial to Evaluate the Worth of Preoperative Multimodality Therapy in Patients with Operable Carcinoma of the Rectum. *Diseases of the Colon & Rectum*, **40**, 131-139. <https://doi.org/10.1007/BF02054976>
- [18] Bosset, J.-F., Collette, L., Calais, G., Mineur, L., Maingon, P., Radosevic-Jelic, L., *et al.* (2006) Chemotherapy with Preoperative Radiotherapy in Rectal Cancer. *The New England Journal of Medicine*, **355**, 1114-1123. <https://doi.org/10.1056/NEJMoa060829>

- [19] Gérard, J.-P., Conroy, T., Bonnetain, F., Bouché, O., Chapet, O., Closon-Dejardin, M.-T., *et al.* (2006) Preoperative Radiotherapy with or without Concurrent Fluorouracil and Leucovorin in T3-4 Rectal Cancers: Results of FFCO 9203. *Journal of Clinical Oncology*, **24**, 4620-4625. <https://doi.org/10.1200/JCO.2006.06.7629>
- [20] Allegra, C.J., Yothers, G., O'Connell, M.J., Beart, R.W., Wozniak, T.F., Pitot, H.C., *et al.* (2015) Neoadjuvant 5-FU or Capecitabine plus Radiation with or without Oxaliplatin in Rectal Cancer Patients: A Phase III Randomized Clinical Trial. *Journal of the National Cancer Institute*, **107**, djv248. <https://doi.org/10.1093/jnci/djv248>
- [21] Bujko, K., Nowacki, M.P., Nasierowska-Guttmejer, A., Michalski, W., Bębenek, M., Pudelko, M., *et al.* (2004) Sphincter Preservation Following Preoperative Radiotherapy for Rectal Cancer: Report of a Randomised Trial Comparing Short-Term Radiotherapy vs. Conventionally Fractionated Radiochemotherapy. *Radiotherapy and Oncology*, **72**, 15-24. <https://doi.org/10.1016/j.radonc.2003.12.006>
- [22] Ngan, S.Y., Burmeister, B., Fisher, R.J., Solomon, M., Goldstein, D., Joseph, D., *et al.* (2012) Randomized Trial of Short-Course Radiotherapy versus Long-Course Chemoradiation Comparing Rates of Local Recurrence in Patients with T3 Rectal Cancer: Trans-Tasman Radiation Oncology Group Trial 01.04. *Journal of Clinical Oncology*, **30**, 3827-3833. <https://doi.org/10.1200/JCO.2012.42.9597>
- [23] Erlandsson, J., Holm, T., Pettersson, D., Berglund, A.A., Cedermark, B., Radu, C., *et al.* (2017) Optimal Fractionation of Preoperative Radiotherapy and Timing to Surgery for Rectal Cancer (Stockholm III): A Multicentre, Randomised, Non-Blinded, Phase 3, Non-Inferiority Trial. *The Lancet Oncology*, **18**, 336-346. [https://doi.org/10.1016/S1470-2045\(17\)30086-4](https://doi.org/10.1016/S1470-2045(17)30086-4)
- [24] TNCD. SNFGE.org—French Medical Society of Hepato-Gastroenterology and Digestive Oncology. <https://www.snfge.org/tncd>
- [25] Schrag, D., Weiser, M.R., Goodman, K.A., Gonen, M., Hollywood, E., Cercek, A., *et al.* (2014) Neoadjuvant Chemotherapy without Routine Use of Radiation Therapy for Patients with Locally Advanced Rectal Cancer: A Pilot Trial. *Journal of Clinical Oncology*, **32**, 513. <https://doi.org/10.1200/JCO.2013.51.7904>
- [26] Tebbutt, N.C., Wilson, K., Gebiski, V.J., Cummins, M.M., Zannino, D., Van Hazel, G.A., *et al.* (2010) Capecitabine, Bevacizumab, and Mitomycin in First-Line Treatment of Metastatic Colorectal Cancer: Results of the Australasian Gastrointestinal Trials Group Randomized Phase III MAX Study. *Journal of Clinical Oncology*, **28**, 3191-3198. <https://doi.org/10.1200/JCO.2009.27.7723>
- [27] Conroy, T., Lamfichekh, N., Etienne, P.-L., Rio, E., Francois, E., Mesgouez-Nebout, N., *et al.* (2020) Total Neoadjuvant Therapy with mFOLFIRINOX versus Preoperative Chemoradiation in Patients with Locally Advanced Rectal Cancer: Final Results of PRODIGE 23 Phase III Trial, a UNICANCER GI Trial. American Society of Clinical Oncology, Alexandria. https://doi.org/10.1200/JCO.2020.38.15_suppl.4007
- [28] Hospers, G., Bahadoer, R.R., Dijkstra, E.A., van Etten, B., Marijnen, C., Putter, H., *et al.* (2020) Short-Course Radiotherapy Followed by Chemotherapy before TME in Locally Advanced Rectal Cancer: The Randomized RAPIDO Trial. American Society of Clinical Oncology, Alexandria. https://doi.org/10.1200/JCO.2020.38.15_suppl.4006
- [29] Tey, J., Leong, C.N., Cheong, W.K., Sze, T.G., Yong, W.P., Tham, I.W.K., *et al.* (2017) A Phase II Trial of Preoperative Concurrent Chemotherapy and Dose Escalated Intensity Modulated Radiotherapy (IMRT) for Locally Advanced Rectal Cancer. *Journal of Cancer*, **8**, 3114. <https://doi.org/10.7150/jca.21237>
- [30] Luna-Pérez, P., Rodríguez-Ramírez, S., Hernández-Pacheco, F., Gutiérrez de la Barrera, M., Fernández, R. and Labastida, S. (2003) Anal Sphincter Preservation in Lo-

- cally Advanced Low Rectal Adenocarcinoma after Preoperative Chemoradiation Therapy and Coloanal Anastomosis. *Journal of Surgical Oncology*, **82**, 3-9.
<https://doi.org/10.1002/jso.10185>
- [31] Weiser, M.R., Quah, H.-M., Shia, J., Guillem, J.G., Paty, P.B., Temple, L.K., *et al.* (2009) Sphincter Preservation in Low Rectal Cancer Is Facilitated by Preoperative Chemoradiation and Intersphincteric Dissection. *Annals of Surgery*, **249**, 236-242.
<https://doi.org/10.1097/SLA.0b013e318195e17c>
- [32] Crane, C.H., Skibber, J.M., Feig, B.W., Vauthey, J.-N., Thames, H.D., Curley, S.A., *et al.* (2003) Response to Preoperative Chemoradiation Increases the Use of Sphincter-Preserving Surgery in Patients with Locally Advanced Low Rectal Carcinoma. *Cancer*, **97**, 517-524. <https://doi.org/10.1002/cncr.11075>
- [33] Fokas, E., Conradi, L., Weiss, C., Sprenger, T., Middel, P., Rau, T., *et al.* (2013) Preoperative Chemoradiation Therapy with Capecitabine/Oxaliplatin and Cetuximab in Rectal Cancer: Long-Term Results of a Prospective Phase 1/2 Study. *International Journal of Radiation Oncology, Biology, Physics*, **87**, 992-999.
<https://doi.org/10.1016/j.ijrobp.2013.09.011>
- [34] Lescut, N., Lepinoy, A., Schipman, B., Cerda, T., Guimas, V., Bednarek, C., *et al.* (2015) Pre-Operative Chemoradiotherapy of Rectal Cancer: Experience of One Centre. *Cancer Radiotherapy*, **19**, 98-105.
<https://doi.org/10.1016/j.canrad.2014.11.011>