

Interest of the Padding in the Prevention of Lymphocele Production after Mastectomy with Axillary Dissection for Breast Cancer at Joliot Curie Cancer Center

Mohamed Ezzet Charfi, Sidy Ka*, Jaafar Thiam, Adja Coumba Diallo, Papa Souleymane Dieng, Ahmadou Dem

Cheikh Anta Diop University, Dakar, Senegal
Email: *Sidy.ka@ucad.edu.sn

How to cite this paper: Charfi, M.E., Ka, S., Thiam, J., Diallo, A.C., Dieng, P.S. and Dem, A. (2020) Interest of the Padding in the Prevention of Lymphocele Production after Mastectomy with Axillary Dissection for Breast Cancer at Joliot Curie Cancer Center. *Journal of Cancer Therapy*, 11, 824-831.

<https://doi.org/10.4236/jct.2020.1112071>

Received: September 21, 2020

Accepted: December 26, 2020

Published: December 29, 2020

Copyright © 2020 by author(s) and Scientific Research Publishing Inc. This work is licensed under the Creative Commons Attribution International License (CC BY 4.0).

<http://creativecommons.org/licenses/by/4.0/>



Open Access

Abstract

Introduction: The principal postoperative complication of mastectomies with axillary dissection is the lymphocele that can last many months after surgery. The purpose of our study was to prevent its formation using the padding. **Methods:** Sixty-one patients have been included in our study. The follow-up was 6 months. The patients were divided in two groups through a random draw (simple drainage and drainage associated with padding). All patients had a mastectomy with axillary dissection following the Madden technique. All quantities of lymphoceles during postoperative hospitalization and ambulatory care have been noted. **Results:** Twenty-five patients had benefited from the padding and 36 of a simple axillary drainage. Six months after the surgery, the patients benefitting from the padding had a quantity of lymphocele equal to half that of the control group (761.83 mL against 1373.60 mL; $p = 0.01$). During the postoperative hospitalization, the quantities were of 362.80 mL for the padding group versus 630.83 mL; $p < 0.01$. The hospitalization period was shorter for the padding patients (3.72 days vs 5.14 days; $p = 0.01$). However, pain was greater for the padding group upon 6 months (0.26 vs 0.10; $p = 0.04$). On another note, padding does not influence the duration of the surgery. **Conclusion:** The production of postoperative lymphocele is heterogenous, varying from one patient to another. Nevertheless, the padding of the mastectomy compartment and of the axillary cavity allows a noticeable reduction of the produced quantity and of the hospitalization period at the expense of more pain.

Keywords

Mastectomy, Axillary Dissection, Lymphocele, Padding

1. Introduction

Breast cancer is the most widespread type of cancer in women worldwide [1]. In Senegal, it represents the second most frequent type of women cancer [1]. In many cases, patient treatment may require carrying out a mastectomy with axillary dissection [2] [3] [4]. The principal complication of this surgery is the lymphocele that can last several months after the surgery. It is the main source of morbidity after mastectomy, with or without axillary dissection, and it significantly affects the patient's quality of life. The lymphocele weighs down patient care and can delay the administering of adjuvant treatment [5]. Preventing a lymphocele currently relies on the use of a suction drain, to be used as long as there is a continuous production of lymphocele. This procedure elongates the duration of the postoperative hospitalization since the patients are hospitalized until ablation. Many teams have tried to remediate this problem by attempting to limit and close up this dead space created during surgery to limit the quantity of lymphocele produced [6]. It is under this light that the padding was adopted. It consists of suturing the skin flaps to the underlying muscles in the axillary fossa and the mastectomy compartment, allowing the closure of the dead space created by the breast surgery [7]. Thus, the primary objective of our study was to evaluate the effect of the padding on the production of lymphocele.

2. Methods

This was a prospective study with the aim to evaluate the padding in preventing the lymphocele after a mastectomy and axillary dissection. The period of inclusion was from 1st January to 30th June 2018. The inclusion criteria were: unilateral disease; unilateral surgery; the use of Madden procedure; no immediate reconstruction, and the possibility of complete skin coverage. Exclusion criteria were patients in whom skin closure was not possible and patients who did not have the total 6-month postoperative follow-up. All patients consented after informed information to participate in the study. Patients were divided in two groups through a random draw. The first group includes the patients benefitting from the padding of mastectomy compartment and of the axillary cavity as well as from an axillary suction drain. The second group (control group) only benefited from the axillary suction drain, without padding. Padding of the axillary cavity was done through slow-absorbing suture and starting under the axillary vein going down. This suture joins, in three points, the pectoral muscles internally, the latissimus dorsi in the back and the subcutaneous tissue externally. Then, padding of the mastectomy compartment was accomplished through a series of sutures spaced by 2 cm each and connecting the pectoralis major with the

superior and inferior skin flaps. All patients were hospitalized after surgery until the quantity of lymphocele produced by drainage is inferior or equal to 50 mL. Then, each patient was supervised for 6 months after the surgery. Pain evaluation has been measured according to the visual analogic scale. The statistical study was carried out using Salstat2 software 2.2 a2 version. Categorical variables were compared with the Chi2 test. The differences between continuous variables between two groups were analyzed with the Student's test and for all groups of the same parameter with analysis of variance (ANOVA). A p value ≤ 0.05 was considered statistically significant.

3. Results

The study occurred at Joliot Curie Institute of Dakar. The period of inclusion was from 1st January to 30th June 2018. In total, 61 patients have been included in our study and randomly sorted into two groups: 25 benefitted from padding while the remaining 36 were included in the control group. The characteristics of the patients are summed up in **Table 1**.

The mean quantity produced during the whole period of hospitalization was of 520.98 mL \pm 338.75 (40 - 1480). For the control group, it was of 630.83 ml \pm 328.98 (60 - 1480). However, for the padding group, this quantity was 362.80 mL \pm 291.34 (40 - 1400). We have noticed that quantity is noticeably weaker ($p < 0.01$) for the padding group. These same patients had a shorter hospitalization period (3.72 days \pm 1.95 (2 - 11) versus 5.14 days \pm 1.84 (2 - 10); $p = 0.01$).

Otherwise, the mean quantity of drained lymphocele during the ambulatory follow-up was 604.81 mL \pm 752.30 (0 - 3223). It was 748.93 \pm 758.90 (0 - 3098) for the control group versus 416.83 mL \pm 716.42 (0 - 3223) for the padding group. The total quantity punctured was lower but not significant ($p = 0.17$). The number of productive puncture was slightly less for the padding group (9.17 \pm 5.62 (5 - 32) vs 11.07 \pm 4.80 (5 - 21); $p = 0.29$).

Table 1. Patients characteristics.

Characteristics	Padding group (n = 25)	Control group (n = 36)
Patient		
Age	48.02	43.50
Gravidity	4.64	5.53
Menopause	11	13
BMI before chemotherapy	25.12	24.98
Antecedents		
Arterial hypertension	10	18
Diabetes	2	2
Anti-coagulant treatment	1	0

The total mean quantity of lymphocele produced during 6 months was 1108.11 mL \pm 911.88 (100 - 3603). The quantity produced for the padding group was noticeably weaker than that of the control group (761.83 mL \pm 788.13 (100 - 3603) versus 1373.60 mL \pm 922.91 (110 - 3418); $p = 0.02$).

The pain remained more elevated in the padding group, but it remains of a weaker rank given the administration of analgesics. For these padded patients, the pain lessens from 1.08 (at 7 days post-operatively) to 0.26 (at 6 months) while it lessens from 0.64 to 0.10 for the control group.

The mean duration of the operating time for the padding group was of 158.86 min \pm 35.18 (95 - 220) and of 153.33 min \pm 42.26 (80 - 265) for the control group. Thus, padding slightly increased the operating time, without this difference being too significant ($p = 0.77$) (Figures 1-3).

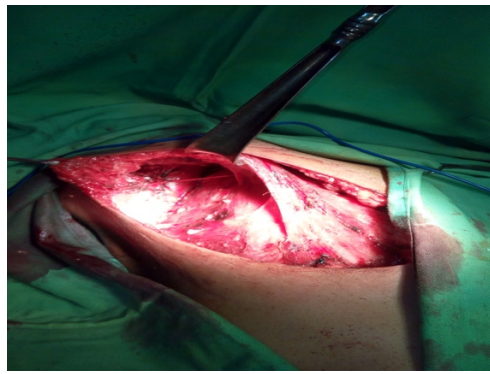


Figure 1. After mastectomy.

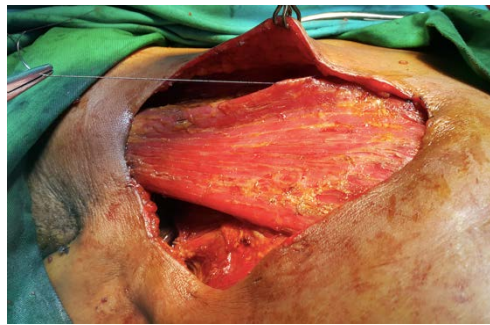

Figure 2. Padding of chest sector.

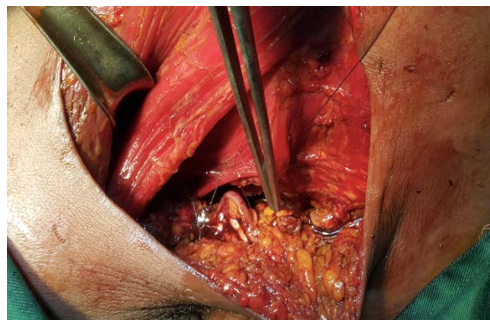


Figure 3. Padding of axillary sector.

The primary objective of this study was to evaluate the effect of the padding on the production of lymphocele.

Although the study should be of interest to Journal readers a few concerns arose during review that should be addressed.

4. Comments

1) This was a prospective study with the aim to evaluate the padding in preventing the lymphocele after a mastectomy and axillary dissection during which period?

2) “The inclusion criteria were: unilateral disease; unilateral surgery; the use of Madden procedure; no immediate reconstruction, and the possibility of complete skin coverage”, what were the exclusion criteria?

3) Ethical clearance of this study should be claimed.

4) Sample size calculation method should also be described in the method part.

5) Statistic analysis method should be described in the method part.

6) In **Table 1**, p value showing the comparison between the two groups should be added.

5. Discussion

The principal morbidities are linked to the axillary dissection. Besides the immediate complications due to a surgical lesion of regional anatomical elements, we distinguish complications that are early and others that are delayed. For the early complications, this mainly includes the lymphoceles which are lymphatic effusions from the armpit and mastectomy compartment [8]. Extremely frequent, they can vary in volume, being very abundant and even rebellious in some cases [9] [10] [11] [12]. They can be responsible for prolonging the duration of hospitalization, as well as for lymphedema, infections, disunion and so of a delay in administering adjuvant treatment. They can also originate plastic skin lesions and chronic pain [13] [14].

Currently, the prevention of lymphocele hinges on setting up a postoperative suction drain, but this procedure elongates the duration of hospitalization until its ablation [15]. Besides, many other techniques have been suggested in order to diminish the quantity of lymphocele produced and afterwards the duration of the postoperative hospitalization period. These techniques have in common the setting of skin flaps using the padding technique, tetracyclines, fibrin, thrombin or a biological adhesive [16] [17]. Many teams have applied this technique at the axillary level and the mastectomy compartment in order to lessen the quantity of lymphocele and the duration of postoperative drainage [18] [19] [20]. Padding can reduce the production since the first postoperative day [18] [19].

In a investigation of the effect of padding in 3 groups: simple mastectomy, mastectomy with or without axillary dissection and axillary dissection alone, results showed a marked decrease in postoperative lymphocele in all 3 groups and

concluded that longtime drainage can be avoided for mastectomies with an axillary act with excellent functional or aesthetic results [20] [21]. Especially when flap or glue are associated [22].

Padding allows a shorter post-operative hospital stay and faster patient discharge which can go up to 2 days [23] [24].

There is no benefit in terms of pain control and reduction of puncture number [18] [23]. For the operation duration, there is no difference when comparing the 2 procedures. It appears that the padding does not lengthen the operating time despite being an additional gesture during the closing of the plans [19] [20].

6. Conclusion

The padding halved the amount of lymphocele produced during the 6-month follow-up period. This decrease was already visible since the hospital period when the patients who benefited from the padding produced a quantity equal to half that of the non-padded patients. The padding also shortened the length of hospital stay by about 1.5 days. And despite the lower quantity and shorter hospital stay, the padded patients did not require more outpatient care. This technique did not extend the operating time. However, the pain was greater even though it was still the order of the weak.

Conflicts of Interest

The authors declare no conflicts of interest regarding the publication of this paper.

References

- [1] Coughlin, S.S. (2019) Epidemiology of Breast Cancer in Women. *Advances in Experimental Medicine and Biology*, **1152**, 9-29.
https://doi.org/10.1007/978-3-030-20301-6_2
- [2] Abass, M.O., Gismalla, M.D.A., Alsheikh, A.A. and Elhassan, M.M.A. (2018) Axillary Lymph Node Dissection for Breast Cancer: Efficacy and Complication in Developing Countries. *Journal of Global Oncology*, **4**, 1-8.
<https://doi.org/10.1200/JGO.18.00080>
- [3] Hennigs, A., Riedel, F., Feißt, M., Köpke, M., Rezai, M., Nitz, U., Moderow, M., Golatta, M., Sohn, C. and Heil, J. (2019) Evolution of the Use of Completion Axillary Lymph Node Dissection in Patients with T1/2N0M0 Breast Cancer and Tumour-Involved Sentinel Lymph Nodes Undergoing Mastectomy: A Cohort Study. *Annals of Surgical Oncology*, **26**, 2435-2443.
<https://doi.org/10.1245/s10434-019-07388-7>
- [4] Arisio, R., Borella, F., Porpiglia, M., Durando, A., *et al.* (2019) Axillary Dissection vs. No Axillary Dissection in Breast Cancer Patients with Positive Sentinel Lymph Node: A Single Institution Experience. *In Vivo*, **33**, 1941-1947.
<https://doi.org/10.21873/invivo.11689>
- [5] Marszalek, D., Noël, J.C. and Simon, P. (2016) Post Operative Complications after Neoadjuvant Systemic Therapy in Primary Breast Cancer Treatment—Case-Control Study. *Revue Médicale de Bruxelles*, **37**, 469-475.
- [6] Giard, S., Laurent, J.C., Dron, A.M. and Lefebvre, D. (1997) Axillary Lymphadenectomy

Prepared by Fat Aspiration versus Functional Axillary Lymphadenectomy: Preliminary Results of a Randomized Prospective Study. *Bulletin du Cancer*, **84**, 254-258.

- [7] Ouldamer, L., Bonastre, J., Brunet-Houdard, S., Body, G., Giraudeau, B. and Caille, A. (2016) Dead Space Closure with Quilting Suture versus Conventional Closure with Drainage for the Prevention of Seroma after Mastectomy for Breast Cancer (QUISERMAS): Protocol for a Multicentre Randomised Controlled Trial. *BMJ Open*, **6**, e009903. <https://doi.org/10.1136/bmjopen-2015-009903>
- [8] Trefoux-Bourdet, A., Body, G., Jacquet, A., Hébert, T., Kellal, I., Marret, H. and Ouldamer, L. (2015) Quilting Suture after Mastectomy in Prevention of Postoperative Seroma: A Prospective Observational Study. *Gynécologie Obstétrique & Fertilité*, **43**, 205-212. <https://doi.org/10.1016/j.gyobfe.2015.01.007>
- [9] van Bommel, A.J.M., van de Velde, C.J.H., Schmitz, R.F. and Liefers, G.J. (2011) Prevention of Seroma Formation after Axillary Dissection in Breast Cancer: A Systematic Review. *European Journal of Surgical Oncology*, **37**, 829-835. <https://doi.org/10.1016/j.ejso.2011.04.012>
- [10] Douay, N., Akerman, G., Clément, D., et al. (2008) Seroma after Axillary Lymph Node Dissection in Breast Cancer. *Gynécologie Obstétrique & Fertilité*, **36**, 130-135.
- [11] Katsumasa, K., Kojiro, S., Tetsuya, T., et al. (2005) Pathophysiology of Seroma in Breast Cancer. *Breast Cancer*, **12**, 288-293. <https://doi.org/10.2325/jbcs.12.288>
- [12] Zaidi, S. and Hinton, C. (2017) Breast Cancer Surgery without Suction Drainage and Impact of Mastectomy Flap Fixation in Reducing Seroma Formation. *European Journal of Surgical Oncology*, **43**, 32-37. <https://doi.org/10.1016/j.ejso.2017.01.129>
- [13] Classe, J.M., Dupre, P.F., François, T., et al. (2002) Axillary Padding as an Alternative to Closed Suction Drain for Ambulatory Axillary Lymphadenectomy: A Prospective Cohort of 207 Patients with Early Breast Cancer. *The Archives of Surgery*, **137**, 169-173. <https://doi.org/10.1001/archsurg.137.2.173>
- [14] Delmar, R., Aitken, M.D., John, P. and Minton, M.D. (1983) Complications Associated with Mastectomy. *Surgical Clinics of North America*, **63**, 1331-1352. [https://doi.org/10.1016/S0039-6109\(16\)43192-0](https://doi.org/10.1016/S0039-6109(16)43192-0)
- [15] Coveney, E.C., O'Dwyer, P.J., Geraghty, J.G. and O'Higgins, N.J. (1993) Effect of Closing Dead Space on Seroma Formation after Mastectomy—A Prospective Randomized Clinical Trial. *European Journal of Surgical Oncology*, **19**, 143-146.
- [16] Agrawal, A., Ayantunde, A.A. and Cheung, K.L. (2006) Concepts of Seroma Formation and Prevention in Breast Cancer Surgery. *ANZ Journal of Surgery*, **76**, 1088-1095. <https://doi.org/10.1111/j.1445-2197.2006.03949.x>
- [17] Pogson, C.J., Adwani, A. and Ebbs, S.R. (2003) Seroma Following Breast Cancer Surgery. *European Journal of Surgical Oncology*, **29**, 711-717. [https://doi.org/10.1016/S0748-7983\(03\)00096-9](https://doi.org/10.1016/S0748-7983(03)00096-9)
- [18] Mazouni, C., Mesnard, C., Cloutier, A.S., et al. (2015) Quilting Sutures Reduces Seroma in Mastectomy. *Clinical Breast Cancer*, **15**, 289-293. <https://doi.org/10.1016/j.clbc.2014.12.014>
- [19] Mancaux, A., Naepels, P., Mychaluk, J., et al. (2015) Padding for Post-Mastectomy Seroma Prevention. *Gynécologie Obstétrique & Fertilité*, **43**, 13-17. <https://doi.org/10.1016/j.gyobfe.2014.11.005>
- [20] Yu, J. and Forouhi, P. (2012) Quilting of Flaps Substantially Reduces Seroma Formation Following Mastectomy or Axillary Clearance. *European Journal of Surgical Oncology*, **38**, 454. <https://doi.org/10.1016/j.ejso.2012.02.165>
- [21] Khater, A., Elnahas, W., Roshdy, S., Farouk, O., et al. (2015) Evaluation of the Quilting

Technique for Reduction of Postmastectomy Seroma: A Randomized Controlled Study. *International Journal of Breast Cancer*, **2015**, Article ID: 287398.

<https://doi.org/10.1155/2015/287398>

- [22] Sajid, M.S., Betal, D., Akhter, N., Rapisarda, I.F. and Bonomi, R. (2011) Prevention of Postoperative Seroma-Related Morbidity by Quilting of Latissimus Dorsi Flap Donor Site: A Systematic Review. *Clinical Breast Cancer*, **11**, 357-363.

<https://doi.org/10.1016/j.clbc.2011.04.006>

- [23] Garbay, J.R., Picone, O., Baron-Merle, G., *et al.* (2004) Axillary Lymphadenectomy with Muscular Padding without Drainage. *Gynécologie Obstétrique & Fertilité*, **32**, 1039-1046. <https://doi.org/10.1016/j.gyobfe.2004.10.015>

- [24] Kuroi, K., Shimosuma, K., Taguchi, T., *et al.* (2006) Effect of Mechanical Closure of Dead Space on Seroma Formation after Breast Surgery. *Breast Cancer*, **13**, 260-265.

<https://doi.org/10.2325/jbcs.13.260>