

Retinal Damage of Hemoglobinopathies in Adults: About 181 Cases in Campus-Teaching Hospital of Lomé

Nidain Maneh^{1,2*}, Koffi Didier Ayena¹, Kossi Brice Dzidzinyo¹, Kokou Vonor¹, Komi Patrice Balo¹

¹Faculty of Health Sciences University of Lomé, Lomé, Togo

²Eye Department of Teaching Hospital, Campus of Lomé, Togo

Email: *manehnid@hotmail.fr

How to cite this paper: Maneh, N., Ayena, K.D., Dzidzinyo, K.B., Vonor, K. and Balo, K.P. (2017) Retinal Damage of Hemoglobinopathies in Adults: About 181 Cases in Campus-Teaching Hospital of Lomé. *Open Journal of Ophthalmology*, 7, 153-157.

<https://doi.org/10.4236/ojoph.2017.73021>

Received: April 28, 2017

Accepted: July 7, 2017

Published: July 10, 2017

Copyright © 2017 by authors and Scientific Research Publishing Inc. This work is licensed under the Creative Commons Attribution International License (CC BY 4.0).

<http://creativecommons.org/licenses/by/4.0/>



Open Access

Abstract

Aims: To study the frequency of sickle cell retinopathy and its severity. **Material and Methods:** Retrospective study over a period of 3 years (July 2013 thru June 2016) of cases of adults over 18 years old sent by the Hematology Department of the Campus-Teaching Hospital of Lomé in the context of a sickle-cell disease check-up. The parameters studied were age, sex, genotype, examination of the fundus by the Goldmann lens. The classification after the fundus was in non-proliferative retinopathy and in 5 proliferative stages according to Goldberg's classification. **Results:** Hundred and eighty-one patients were included with an average age of 29.39 ± 9.84 . The sex ratio was 0.72 in favor of female. The SC genotype was 50.3%; SS 37.6%; CC 11% and SF 1.1%. Sickle cell retinopathy was found in 22.7% of patients, among which 14.4% were proliferative and 8.3% non-proliferative. Seventy-three percent of patients with proliferative retinopathy were SC genotype, 23% SS and 3% CC genotype. Among SC patients, 20.9% had proliferative retinopathy; 8.8% SS; and 5% CC. Fifty percent of patients with proliferative retinopathy had Goldberg's stage ≥ 3 . **Conclusion:** We found 22.7% of sickle cell retinopathy which proliferative form was strongly represented by the SC genotype.

Keywords

Hemoglobinopathy, Sickle Cell Retinopathy, Adult, Lomé

1. Introduction

Hemoglobinopathies are due to the appearance of the pathological hemoglobin through structural modification of certain polypeptide chains of the normal hemoglobin (HbA). Sickle-cell disease is a frequent and severe hemoglobinopathy.

About 230,000 children affected by sickle-cell disease are born every year in the sub-Saharan region, 2600 in North America and 1300 in Europe [1]. The molecular mechanism is the replacement of the glutamic acid by valine at the level of the codon 6 of the β globin gene, resulting in the production of the abnormal hemoglobin, hemoglobin S (HbS). Sickle cell disease is transmitted through the autosomal recessive mode: homozygote SS, heterozygote AS, double heterozygotes or “composite heterozygotes” SC (AS + AC), $S\beta$ (AS + β heterozygote thalassemia).

AS heterozygotes are asymptomatic, SS homozygotes and double heterozygotes or “composite heterozygotes” SC, $S\beta$, SS + HPFH (hereditary persistence of fetal hemoglobin) are symptomatic and show the systemic manifestations of this disease. The ocular manifestations of sickle-cell disease are frequent and especially retinal with complications potentially associated with visual loss. Sickle cell retinopathy is frequently described in SS and SC homozygous forms and more rarely in AS [2] [3] and $S\beta$ [4] heterozygous forms. The study of Balo *et al.* [2] in Lomé showed that AS form was the most affected by retinopathy in 26.3%, followed by SS group in 11.05%.

The present study determines the frequency and severity of retinopathy among patients referred for ophthalmologic consultation by the Hematology Department, a reference unit for hemoglobinopathies care in Togo.

2. Material and Methods

This retrospective study over a period of three years (July 2013 thru June 2016) focused on the records of consecutive patients who are over 18 years old, sent to the Department of Ophthalmology for retinopathy by the Hematology Department. The diagnosis of sickle cell disease and genotypic accuracy were previously specified by the hematologist after hemoglobin electrophoresis: homozygote SS, heterozygote AS, double heterozygotes or “composite heterozygotes” SC (AS + AC), HPFH (hereditary persistence of fetal hemoglobin). All patients had a slit-lamp examination, the fundus by the Goldmann lens to assess the posterior pole and the entire retinal periphery. A distribution in the absence of sickle cell retinopathy, in non-proliferative sickle cell retinopathy (golden frosted, black sunburst) and in proliferative form according to Goldberg’s classification (Goldberg 1: peripheral arteriolar occlusions, Goldberg 2: peripheral arteriovenular anastomoses, Goldberg 3: preretinal peripheral neovascularization, Goldberg 4: intravitreal hemorrhage, Goldberg 5: retinal detachment) [5] had been made.

Patients with AS sickle-cell, an associated β -thalassemia or α -thalassemia were excluded from the study. The parameters analyzed in the study were age, sex, genotype (SS, SC, SF, and CC), and the severity of the retinopathy (non-proliferative and according to Goldberg).

The statistical analysis, χ^2 was carried out through Epi info software version 7.0 with a significance $p < 0.05$. For qualitative variables, a 95% confidence interval (CI) was calculated.

3. Results

Hundred and eighty-one patients among whom 105 women and 76 men (sex ratio = 0.72) were included in the study. The average age was 29.4 ± 9.84 years; [18 years; 70 years] **Table 1**.

Ninety-one patients were SS genotype (50.3%), sixty eight were SC (37.6%), twenty CC genotype and 2 were SF (1.1%) **Figure 1**.

Fifteen patients (8.3% CI [4.7 - 13.3]) showed a non-proliferative retinopathy (8 SS, 7 SC) and twenty-six patients (14.4% CI [9.6 - 20.3]) a proliferative sickle cell retinopathy.

Out of the twenty-six patients with the proliferative retinopathy, nineteen patients were SC genotype (20.9% of the SC), six patients were SS genotype (8.8% of the SS) and one patient of CC genotype (5% of the CC). 17.1% of female and 10.5% of male showed a PSR (Proliferative Sickle cell Retinopathy) **Table 2**. The average age of patients with a PSR form was 34 ± 8.5 years [18 years; 53 years].

These proliferative retinopathies were predominantly of stage 2 (34.6%), stage 3 (30.8%) and stage 4 (15.4%). The severe forms of proliferative retinopathy with a Goldberg's stage ≥ 3 were found in 13 patients. Seventy-five percent of male (5 cases) with proliferative retinopathy had a severe form, and 38.9% (7 cases) of female had a severe form. Eleven of the severe forms were SC genotype (57.9%) and 2 were SS genotype (33.3%) **Table 2**.

Table 1. The socio-demographic characteristics of the patients: age (years) and sex (female, male).

| | Female | Male | Total |
|--------------|--------|------|-------|
| [18 - 35[| 77 | 61 | 138 |
| [35 - 45[| 16 | 13 | 29 |
| [45 - 55[| 8 | 2 | 10 |
| >55 | 4 | 0 | 4 |
| Total | 105 | 76 | 181 |

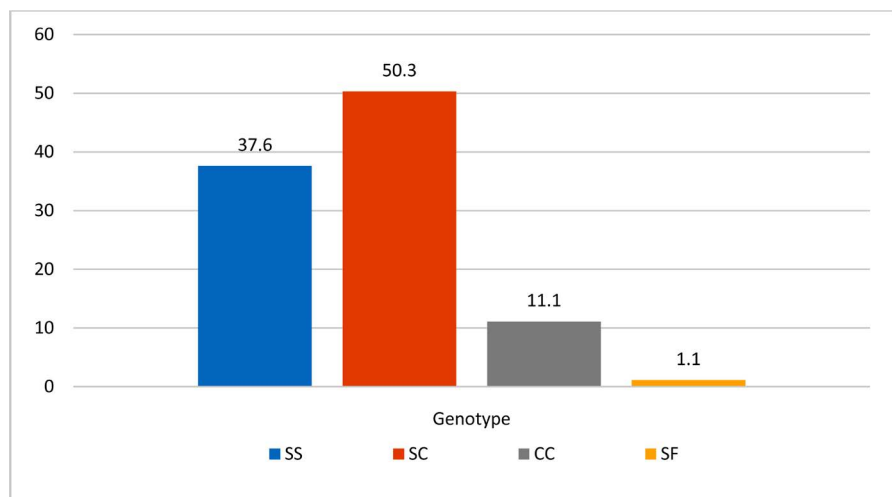


Figure 1. Distribution of the different genotypes.

Table 2. Distribution of genotypes according to the severity of the retinopathy.

| | Absence [#] | Non-proliferative retinopathy | Proliferative retinopathy (%) | | | | | Severe 3 + 4 + 5 |
|--------------|----------------------|-------------------------------|-------------------------------|---------|---------|---------|---------|---------------------|
| | | | Stage 1 | Stage 2 | Stage 3 | Stage 4 | Stage 5 | |
| SS | 54 | 8 | 2 | 2 | 1 | 0 | 1 | 2 (33.3) |
| SC | 65 | 7 | 1 | 7 | 7 | 4 | 0 | 11 (57.9) |
| CC | 20 | 0 | 1 | 0 | 0 | 0 | 0 | 0 |
| SF | 1 | 0 | 0 | 0 | 0 | 0 | 0 | 0 |
| Total | 140 (77.3) | 15 (8.3) | 26 (14.4) | | | | | |

[#]Absence of retinopathy.

4. Discussion

The absence of retinal angiography was a limit to our study.

In our study, we found a large proportion of the SS form (50.3%) followed by the SC form (37.6%) as reported in several studies [6] [7]. The study of Diallo *et al.* had reported in its series a predominance of the SC form in 79.8% then the SS form 20.2% [8]. Fourteen point four percent (14.4%) had proliferative sickle cell retinopathy, which was low compared to that of Diallo *et al.* [8] with 20% and Tran *et al.* [7] with 59%. These differences may be due to the selection criteria because the majority of our patients were already followed in the Hematology Department. The study showed that SC form was the most represented in the proliferative forms 20.9% SC vs. 8.8% SS; as in the review 22% to 43% SC vs. 14% SS [9] [10] [11]. SC form was also the most represented in the severe proliferative forms (57.9% SC vs. 33.3%SS) like in the study of Leveziel *et al.* [6] 54.4% SC vs. 18.1% SS. This confirms the findings that SC forms give retinal complications. In our study, male (75%) showed the severe forms more than female (38.9%). Male sex is a promoting factor for proliferation, as well as hemoglobin level higher than 12.5 g; blood hyperviscosity, hypoxemia, precarious medical treatment [12] [13].

5. Conclusion

Proliferative retinopathy was mainly found in SC genotype. More than half of proliferative sickle-cell retinopathies were severe with a male dominance. An early hematologic and ophthalmologic management and a regular follow-up will enable the reduction of blinding retinal complications.

Conflict of Interest

The authors declare no conflict of interest.

Ethical Approval

Approval for the study was obtained from the national medical ethic committee.

References

- [1] Modell, B. and Darlison, M. (2008) Global Epidemiology of Haemoglobin Disorders

- and Derived Service Indicators. *Bulletin of the World Health Organization*, **86**, 480-487. <https://doi.org/10.2471/BLT.06.036673>
- [2] Balo, K.P., Fany, A., Mihluedo, H., Djagnikpo, P.A. and Koffi-Gue, K.B. (1997) Atteinte rétinienne dans la drépanocytose au Togo: Corrélation entre l'âge, le génotype et la rétinopathie. *Journal Français d'Ophthalmologie*, **20**, 653-658.
- [3] Fany, A., Boni, S., Adjorlolo, C., et al. (2004) La rétinopathie chez le porteur du trait drépanocytaire AS: Mythe ou réalité? *Journal Français d'Ophthalmologie*, **27**, 1025-1030. [https://doi.org/10.1016/S0181-5512\(04\)96259-6](https://doi.org/10.1016/S0181-5512(04)96259-6)
- [4] Fany, A., Coulibaly, F., Gbe, K., et al. (2005) Les bêta thalassos drépanocytoses pourvoyeuses de rétinopathie ischémiques graves. *Journal Français d'Ophthalmologie*, **28**, 391-395. [https://doi.org/10.1016/S0181-5512\(05\)81070-8](https://doi.org/10.1016/S0181-5512(05)81070-8)
- [5] Goldberg, M.F. (1971) Classification and Pathogenesis of Proliferative Sickle Retinopathy. *American Journal of Ophthalmology*, **71**, 649-665. [https://doi.org/10.1016/0002-9394\(71\)90429-6](https://doi.org/10.1016/0002-9394(71)90429-6)
- [6] Leveziel, N., Lallouma, F., Bastuji-Garinc, S., et al. (2012) Rétinopathie drépanocytaire: Analyse rétrospective portant sur 730 patients suivis dans un centre de référence. *Journal Français d'Ophthalmologie*, **35**, 343-347. <https://doi.org/10.1016/j.jfo.2011.10.007>
- [7] Tran, T.H.C., Mekinian, A., Godinaud, M. and Rose, C. (2008) Rétinopathie drépanocytaire chez les adultes de la région Nord-Pas-de-Calais. *Journal Français d'Ophthalmologie*, **31**, 987-992. [https://doi.org/10.1016/S0181-5512\(08\)74745-4](https://doi.org/10.1016/S0181-5512(08)74745-4)
- [8] Diallo, J.W., Sanfo, O., Blot, I., et al. (2009) Etude épidémiologique et facteurs pronostiques de la rétinopathie drépanocytaire à Ouagadougou (Burkina Faso). *Journal Français d'Ophthalmologie*, **32**, 496-500. <https://doi.org/10.1016/j.jfo.2009.04.010>
- [9] Babalola, O.E. and Wambebe, C.O. (2005) Ocular Morbidity from Sickle Cell Disease in a Nigerian Cohort. *Nigerian Postgraduate Medical Journal*, **12**, 241-244.
- [10] Powars, D.R., Hiti, A., Ramicone, E., Johnson, C. and Chan, L. (2002) Outcome in Hemoglobin SC Disease: A Four-Decade Observational Study of Clinical, Hematologic, and Genetic Factors. *American Journal of Hematology*, **70**, 206-215. <https://doi.org/10.1002/ajh.10140>
- [11] Powars, D.R., Chan, L.S., Hiti, A., Ramicone, E. and Johnson, C. (2005) Outcome of Sickle Cell Anemia: A 4-Decade Observational Study of 1056 Patients. *Medicine (Baltimore)*, **84**, 363-376. <https://doi.org/10.1097/01.md.0000189089.45003.52>
- [12] Morel, C. (2001) Atteintes rétinienne des hémoglobinopathies. *Journal Français d'Ophthalmologie*, **24**, 987-992.
- [13] Hayes, R.I., Condon, P.I. and Serjeant, G.R. (1981) Hematological Factors Associated with Proliferative Retinopathy in Homozygotes Sickle Cell Disease. *British Journal of Ophthalmology*, **65**, 29-35. <https://doi.org/10.1136/bjo.65.1.29>

Submit or recommend next manuscript to SCIRP and we will provide best service for you:

Accepting pre-submission inquiries through Email, Facebook, LinkedIn, Twitter, etc.

A wide selection of journals (inclusive of 9 subjects, more than 200 journals)

Providing 24-hour high-quality service

User-friendly online submission system

Fair and swift peer-review system

Efficient typesetting and proofreading procedure

Display of the result of downloads and visits, as well as the number of cited articles

Maximum dissemination of your research work

Submit your manuscript at: <http://papersubmission.scirp.org/>

Or contact ojoph@scirp.org