

# Tarsal Tunnel Syndrome—A New Way to Diagnose an Old Problem

Conor O'Brien<sup>1</sup>, Rob Byrden<sup>2</sup>

<sup>1</sup>Neurophysiology Department, Sports Surgery Clinic, Santry, Dublin, Ireland

<sup>2</sup>Department of Engineering, University College, Dublin, Ireland

Email: drcob50@gmail.com

**How to cite this paper:** O'Brien, C. and Byrden, R. (2017) Tarsal Tunnel Syndrome—A New Way to Diagnose an Old Problem. *World Journal of Neuroscience*, 7, 172-180.

<https://doi.org/10.4236/wjns.2017.71012>

**Received:** January 4, 2017

**Accepted:** February 6, 2017

**Published:** February 9, 2017

Copyright © 2017 by authors and Scientific Research Publishing Inc. This work is licensed under the Creative Commons Attribution International License (CC BY 4.0).

<http://creativecommons.org/licenses/by/4.0/>



Open Access

## Abstract

Tarsal Tunnel Syndrome [TTS] is the most common lower limb focal neuropathy but it has a poor pick up rate in most Electrodiagnostic (EXD) Laboratories. There is no gold standard for assessing TTS. The tibial nerve has a complex branching system with 4 main branches and 9 different patterns of division. This study evaluated potential TTS with a similar and extensive assessment of the tibial nerve. The protocol involved 2 tibial motor studies to the Adductor Hallucis Longus (AH) and Adductor Digiti Quinti (ADQ) muscles, assessing amplitudes and distal latencies; medial plantar, lateral plantar and calcaneal sensory studies assessing amplitudes and distal latencies. A needle EMG to the tibial innervated AH and ADQ muscles was also performed. This protocol evaluated 12 different parameters which significantly increased the diagnostic yield. TTS has a low pick up rate using current standard assessment methods accounting for between 0.5% and 0.6% of positive cases referred to electrodiagnostic laboratories. This study had a pick up rate of 3.3% with 40 positive cases identified out of a population of 1210 patients referred to an electrodiagnostic laboratory in a calendar year. A combination of positive findings was observed. There were on average 4.3 positive parameters. The calcaneal sensory study and the needle EMG to the distal AH and ADQ muscles were the most sensitive tests. These 3 tests are not routinely performed in most labs. Of the 40 cases of TTS over 80% had a history of either prior injury or surgery to affected lower limb. This study suggests that this 12 parameter assessment will increase diagnostic sensitivity.

## Keywords

Tarsal Tunnel Syndrome, Electrodiagnostic, Tibial Nerve, Focal Neuropathy, Adductor Hallucis Longus, Adductor Digiti Quinti

## 1. Introduction

Tarsal Tunnel Syndrome is a compression neuropathy involving the tibial nerve

or its branches as they pass through the tarsal tunnel under the flexor retinaculum. Tarsal tunnel syndrome is the entrapment of the posterior tibial nerve or one of its branches. This entrapment typically occurs within or distal to the tarsal canal. This results in pain and/or sensory disturbance on the medial aspect of the ankle or on the plantar aspect of the foot. Tarsal Tunnel Syndrome is not recognized as readily as its counterpart in the wrist, Carpal Tunnel Syndrome, although the clinical presentation of painful burning sensation in the medial border of the foot and into the great toe in the case of the tibial nerve entrapment is analogous to the sensory alteration in the thumb, index, long and ring finger in cases of median nerve entrapment at the wrist. Tarsal tunnel syndrome frequently involves sensory changes in the heel and the lateral part of the sole of the foot as well as the remaining toes. In addition, it may lead to weakness of the intrinsic muscles of the foot. This syndrome often goes unrecognized or misdiagnosed as plantar fasciitis, sciatic neuropathy or an S1 radiculopathy, particularly in the athletic population.

It is also associated with weakness in the muscles supplied by the motor element of the tibial nerve in particular the adductor hallucis longus and the abductor digiti quinti.

The first reports of the posterior tibial nerve entrapment were in 1960 when Coppel and Thompson described the condition [1]. In 1962 Keck and Lam independently used the term Tarsal Tunnel Syndrome [2] [3].

The initial descriptions of tarsal tunnel syndrome described the entrapment of the posterior tibial nerve in the fibro-osseous tunnel behind the medial malleolus. This condition was considered to be rare. In the 1980's the identification of the lateral plantar nerve and its branches by Baxter and colleagues confirmed that the nerve could be entrapped at other sites [4]. In these individuals where the lateral plantar nerve or the calcaneal branch of the lateral plantar nerve is affected, patients can present with heel pain. This is frequently misdiagnosed as plantar fasciitis, the calcaneal branch of the nerve supplying the heel directly.

Tarsal tunnel syndrome is the most common entrapment neuropathy in the foot and ankle, with patients typically presenting with burning pain in the sole of the foot with a worsening of symptoms with prolonged standing or walking.

The results of surgical treatment for tarsal tunnel syndrome have been suboptimal. This is attributed to a poor understanding of the detailed anatomy of the "tarsal tunnel" and potential sites of nerve compression.

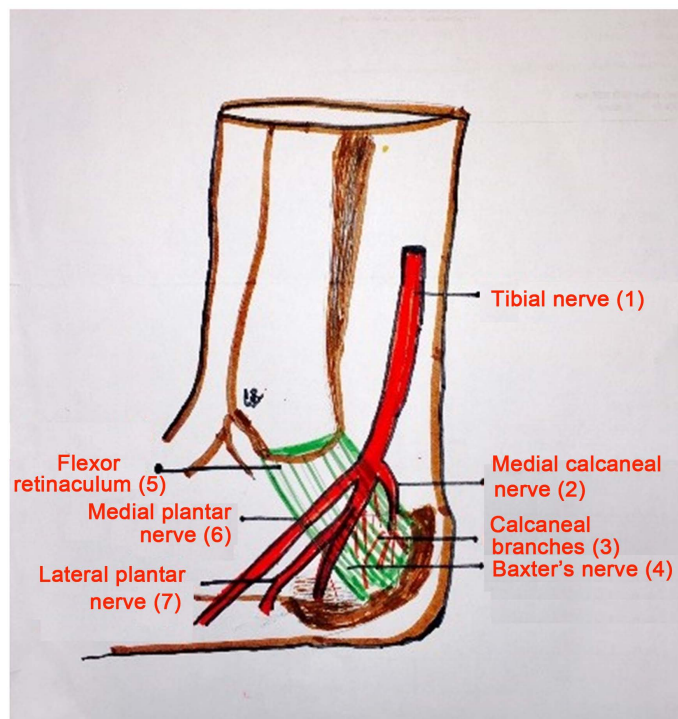
There is a slight female predominance in some studies; the range of ages is wide reporting from the age of 14 to 80 years. The condition is frequently associated with a previous injury to the lower limb or ankle, in a similar way to its near relation the carpal tunnel which can frequently present following a wrist or scaphoid fracture. The condition is common in non-athletes who sustain injuries; however Baxter noted the condition to be quite prevalent in long distance runners [4] where it is well recognized.

### 1.1. Anatomy

The posterior tibial nerve is a branch of the sciatic nerve with a nerve root

supply of L4, L5, S1, S2 and S3.

The nerve enters the leg between the two heads of the gastrocnemius muscle and the nerve lies deep to the soleus muscle in the deep posterior compartment of the leg. The nerve can be entrapped at this level in cases of a posteromedial compartment syndrome. In the lower leg the nerve travels between the flexor digitorum longus and the flexor hallucis longus. It then travels behind the medial malleolus through the proximal tarsal tunnel where it divides into its terminal branches (**Figure 1**), the medial plantar nerve, the lateral plantar nerve and the calcaneal nerve. In 93% of the cases the bifurcation occurs within 2cms of an imaginary line drawn between the middle of the medial malleolus and the mid calcaneus. The calcaneal branches have more variable anatomy. Most individuals (79%) have a single calcaneal nerve usually rising from the posterior tibial nerve but sometimes arising from the lateral plantar nerve. About 21% have multiple calcaneal branches originating from the posterior tibial nerve or the lateral plantar nerve or from a combination of these. The calcaneal branch travels over the adductor hallucis muscle and supplies sensation of the medial heel pad hence the confusion with cases of plantar fasciitis. The medial calcaneal nerve or terminal nerves penetrate the flexor retinaculum and innervates the skin over the medial and posterior heel.



**Figure 1.** Schematic drawing of the tibial nerve anatomy. Schematic drawing of the anatomy of the tibial nerve at the level of the medial ankle joint and tarsal tunnel. 1) tibial nerve, 2) medial calcaneal nerve, 3) calcaneal branches [which have significant variation], 4) Baxter's nerve, 5) flexor retinaculum, 6) medial plantar nerve, 7) lateral plantar nerve. There is significant variability in the branching pattern of the 4 main divisions of the tibial nerve around the tarsal tunnel, and variation in the number and location of the terminal calcaneal subdivisions.

The first branch of the lateral plantar nerve travels between the deep fascia of the abductor hallucis and the medial fascia of the quadratus plantae and then continues on to the deep digitorum brevis muscle. It usually has several branches one of which supplies the abductor digiti quinti [ADQ]. This first branch which supplies the ADQ is called the inferior calcaneal nerve, and is often described as the “Baxter Nerve”, branches separately from the main tibial nerve in 46% of feet [4]. The lateral plantar nerve typically provides a sensory branch to the medial calcaneal tuberosity and motor branch to the flexor digitorum brevis. It then provides a sensory branch to the lateral heel and a motor branch to the abductor digiti quinti muscle. This anatomy is important when making an accurate neurophysiological diagnosis.

There are three well-defined, tough fascial septae in the sole of the foot. In addition to the flexor retinaculum and the abductor hallucis, two of these septae represented potential sites of compression of the posterior tibial nerve and its branches. The medial plantar nerve may be entrapped under the medial septum. In a significant number of cases the medial plantar nerve does not traverse beneath the septum in comparison to the lateral plantar nerve which traverses beneath the medial septum in all specimens. The Baxter nerve to abductor digiti minimi may also be trapped under the medial and intermediate septum [4].

Various anomalies have been reported including a direct origination of all branches from the medial and lateral plantar nerves and from the posterior tibial nerve [4]. In N paper the bifurcation of the tibial nerve into the medial and lateral plantar nerves mostly occurred within the flexor retinaculum and the medial calcaneal branch showed many anatomical variations, the neurovascular bundle was separated from other tendon sheaths, and enclosed in its own tunnel [5]. Hence accurate needle EMG is a cornerstone is diagnosis of this condition as simply relying on the single nerve conduction studies will fails to identify an entrapment due to an anomalous anatomy.

The medial plantar nerve provides sensation to the median half of the foot and the middle  $3\frac{1}{2}$  digits, the nerve provides motor branches to the abductor hallucis, flexor digitorum brevis, flexor hallucis brevis as well as the first Lumbrical.

## 1.2. Aetiology

The tibial nerve can be entrapped anywhere along its course, the most common location is distal to the ankle. Entrapment above the ankle has been reported and can occur in the popliteal fossa or in association with a Baker's cyst or in the posteromedial compartment in cases of compartment syndrome. External compression through the tarsal tunnel causes would include ganglion cysts, lipomas, varicosities, as well as tumours.

Associated conditions that have been reported contributing to the development of tarsal tunnel syndrome include tenosynovitis of the adjacent tendons and in particular the three tendons that travel through the tarsal tunnel (P Tib, Flex Didi, AH) also rarely rupture of the medial tendons are associated with this condition Other conditions which are associated are obesity, ankylosing spondy-

litis, acromegaly and talocalcaneal coalition. There is also an association of tarsal tunnel syndrome in cases of Diabetes Mellitus. Rheumatoid arthritis can also be associated with this condition due to the proliferative synovitis. Direct blunt trauma to the nerve and traction injuries to the nerve as the result of trauma or a valgus heel are also well reported.

The association of tarsal tunnel syndrome and athletic activity was reported by Baxter & Thigpen [3] who described a biomechanical base for the entrapment of the first branch of the lateral plantar nerve in the athletic population. The association of posterior tibial nerve entrapment and athletic pursuit was first identified by Rask when he described it as Jogger's Foot in 1978 [5].

## 2. Methods

An audit was made of a one year period when 1210 patients were referred to a clinical neurophysiologist for a electro diagnostic evaluation of suspected peripheral nerve pathology. The population of patients was tertiary referrals from hospital based consultants, who were specialists in Orthopaedic Surgery, Rheumatology, Musculoskeletal Medicine and General Medicine. The age range was 20 - 83 years, with a female to male bias of 53% to 47%. Of these 65% were referred for assessment of suspected Carpal Tunnel Syndrome or Cervical Radiculopathy. 10% were referred for assessment of Lumbar Radiculopathy. Brachial plexopathy accounted for 8% of referrals. Suspected pudendal neuropathy accounted for 3% of referrals. The remaining 14% were referred for a variety of suspected polyneuropathies and focal neuropathies. Of these 59 patients [4.8%] were referred for assessment of possible Tarsal Tunnel Syndrome. This discrete subset of patients was assessed for both radiculopathy, peripheral neuropathy and had a full assessment of the function of the tibial nerve. Patients with Diabetes Mellitus were excluded. Patients with Rheumatoid arthritis were included

The tibial nerve assessment involved nerve conduction studies to the following nerves assessing amplitudes and distal latencies (10 parameters)

- Tibial motor study to the adductor hallucis muscle
- Tibial motor study to the adductor digiti quinti muscle
- Medial plantar sensory study
- Lateral plantar sensory study
- Calcaneal sensory study

A needle EMG to the tibial innervated Adductor Hallus muscle (AH) and Adductor Digiti Quinti muscle (ADQ) were also performed This EMG assessment analysed rest activity, insertional activity and recruitment pattern. The results were scored as either denervated or normal (2 parameter) The results were scored as either denervated or normal (2 parameter). All results were compared to standard laboratory values. In all 12 parameters were evaluated in the TTS assessment.

## 3. Results

Of the 59 patients referred for possible Tarsal tunnel Syndrome 40 patients

(68%) showing evidence of the abnormality. 18 of the cohort of 59 showed no evidence of TTS, of these 5 showed no abnormality and the remaining 14 showed evidence of a combination of radiculopathy, peripheral neuropathy or focal neuropathies.

Of the 40 TTS cases there was on average 4.3 positive test parameters present in each of the cases (**Figure 2**).

37.5% tested positive for at least 6 of the 12 electro-diagnostic parameters (**Table 1**).

67.5% of the Tarsal Tunnel Syndrome group had history of a previous injury or operation in the lower limb (**Table 2**).

30% had history of a previous operation alone. 52.5% had a prior injury to the lower limb. 6 individuals reported both a prior injury and ankle surgery.

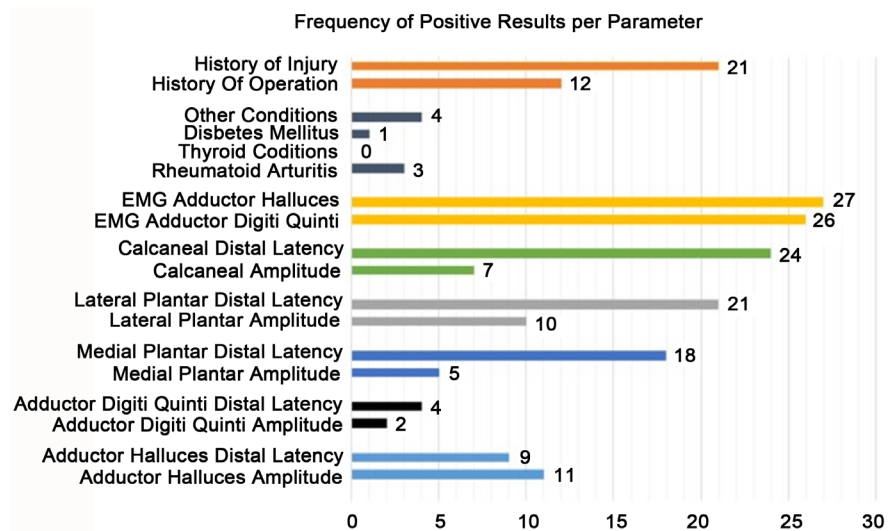
The 12 parameters assessment of TTS resulted in a diagnostic pick up rate of 3.3% with 40 positive cases out of 1210 patient referrals in a calendar year.

The calcaneal sensory study and the needle EMG to the AH and ADQ muscles proved to be the most sensitive tests. The calcaneal sensory study distal latency being prolonged in 60% of cases. The needle EMG to the AH muscle showed denervation in 65% of cases. The needle EMG to the ADQ muscle showed denervation in 67.5% of cases (**Table 2**).

Needle EMG to the AH and the ADQ and the calcaneal sensory study are not routinely performed in cases of suspected TTS. Their addition to the range of electro-diagnostic tests contributed to the increased detection rates shown in this study.

**Table 1.** Positive test parameters in cases of tarsal tunnel syndrome.

Test Number:	Test Parameter:	% Positive Results:	Number of positive results:
1	Tibial motor study to Adductor Halluces muscle: Amplitude of Response	27.5%	11
2	Tibial motor study to Adductor Halluces muscle: Distal Latency	22.5%	9
3	Tibial motor study to the Adductor Digiti Quinti muscle: Amplitude of response	5%	2
4	Tibial motor study to the Adductor Digiti Quinti muscle: Distal Latency	10%	4
5	Medial Plantar: Amplitude of Response	12.5%	5
6	Medial Plantar: Distal Latency	45%	18
7	Lateral Plantar: Amplitude of Response	25%	10
8	Lateral Plantar: Distal Latency	52.5%	21
9	Calcaneal: Amplitude of Response	17.5%	7
10	Calcaneal: Distal Latency	60%	24
11	Needle EMG to tibial innervated Adductor Halluces	65%	26
12	Needle EMG to tibial innervated Adductor Digiti Quinti	67.5%	27



**Figure 2.** Frequency of positive results per parameter in cases of TTS.

**Table 2.** Prior history of injury and or surgery in cases of TTS.

	% of total:	Total Number:
History of Previous Injury:	52.5%	21
History of previous Operation:	30.0%	12
History of injury or Operation:	67.5%	27

#### 4. Discussion

A patient with tarsal tunnel syndrome often describes vague discomfort and pain, specifically the pain posterior to the medial malleolus and radiating to the arch of the foot. There is usually sensory alteration in the sole of the foot in both the medial and lateral aspects. Commonly there is heel pain due to the involvement of the calcaneal branch. Frequently individuals will also describe weakness in the foot biomechanics both in abductor and adduction. Patients are often asymptomatic in the morning after taking the first two steps. Symptoms usually worsen with increased activity and towards the end of the day after long periods of walking or running. Also standing in the same place for long periods of time can also aggravate the problem. The pain and burning in the feet usually persist for half an hour or more after the patient has gone off his feet.

Tarsal Tunnel Syndrome patients are reported to have a previous traumatic injury to their foot or ankle. This study confirms this hypothesis with 67.5% of cases sustain an injury or surgical trauma. It is postulated that this occurs in a similar way to carpal tunnel syndrome where there can be tightening of the flexor reticulum in association with trauma, resulting in a post trauma neuropathy.

The diagnosis of Tarsal Tunnel Syndrome (TTS) is based on a detailed history and physical examination, as well as electro-diagnostic testing. The symptoms are often vague, and clinical signs are often difficult to elicit. The history should also take careful note of past medical history of ankylosing spondylitis, polyneuropathy, diabetes mellitus, as well as alcoholism, thyroid disease and peri-



pheral neuropathy, all of which are associated with an increased incidence of TTS [1]. A history of a previous trauma to the foot or ankle should also be sought, as the current study confirms the association of previous injury and surgery in cases of TTS.

Electro-diagnostic testing should be extensive and consistent and follow a similar pattern in every individual. This is to take into account the significant variability in the anatomy of the posterior tibial nerve. A limited examination, as has been recommended by some authors [2], is restricted to tibial motor, and medial and lateral plantar sensory studies. This limited approach will reduce the diagnostic yield. The current study confirms that the most sensitive EXD tests for TTS were the needle EMG to the AH and ADQ muscles and the calcaneal sensory study. These elements are not routinely performed in the EXD assessment of suspected cases of TTS.

This study recommends a 12-parameter test protocol: 3 sensory nerve conduction studies, 2 motor nerve conduction studies and a 2-muscle needle EMG assessment. This methodology is a detailed interrogation of the tibial nerve at the Tarsal Tunnel and is cognizant of the significant variability in the branching pattern of the nerve at this anatomical site, which therefore requires a detailed EXD examination. The approach resulted in a significant increase in the detection rate of TTS, annualized at 3.3% which is a 5-fold increase on reported diagnostic rates [6].

This study recommends a 12-parameter test protocol, 3 sensory nerve conduction studies, 2 motor nerve conduction studies and a 2 muscle needle EMG assessment. This methodology resulted in a significant increase in the detection rate of TTS, annualized at 3.3% which is a 5-fold increase on reported diagnostic rates [6].

A literature review of the of Tarsal Tunnel evaluation techniques [7] confirmed a significant lack of standardization in methodology, and little regard for the variability and complex nature of the anatomy of the tibial nerve in suspected cases. This extensive review of 317 articles and studies on the topic confirmed that that needle EMG to the Adductor Halluces and the Adductor Digiti Quinti was never used in the assessment of TTS. Calcaneal nerve conduction sensory studies were similarly not employed in evaluating this condition. The current study has highlighted that these 3 tests proved to be the most sensitive tests in this study for evaluation of TTS. Non standardization of assessment and failure to use available techniques may account for the poor detection rate of this the most common lower limb focal neuropathy.

This study suggests that a heightened index of suspicion in cases of foot sensory alteration where there is a prior history of lower limb trauma coupled with this 12 parameter assessment may improve detection rate for TTS whose true incidence may be under reported.

## References

- [1] Coppel, H.P. and Thompson, W.A.L. (1963) *Peripheral Entrapment Neuropathies*. Williams & Wilkins, Baltimore, Chapters 4 and 5, 23-33.



- [2] Keck, C. (1962) The Tarsal Tunnel Syndrome. *The Journal of Bone & Joint Surgery*, **44**, 180-184. <https://doi.org/10.2106/00004623-196244010-00015>
- [3] Lam, S.J. (1962) A Tarsal Tunnel Syndrome. *Lancet*, **2**, 1354-1355. [https://doi.org/10.1016/S0140-6736\(62\)91024-3](https://doi.org/10.1016/S0140-6736(62)91024-3)
- [4] Baxter, D.E. and Thigpen, M. (1984) Heel Pain Operative Results. *Foot Ankle*, **5**, 16-25. <https://doi.org/10.1177/107110078400500103>
- [5] Baxter, D.E. and Pferrer, G.B. (1992) Treatment of Chronic Heel Pain by Surgical Release of the First Branch of the Lateral Plantar Nerve. *Clinical Orthopaedics and Related Research*, **279**, 229-236. <https://doi.org/10.1097/00003086-199206000-00029>
- [6] Saeed, M.A. (2004) Tarsal Tunnel Syndrome. *Course C: Painful Foot and Ankle AAEM51<sup>ST</sup> Annual Scientific Meeting*, Savannah, Georgia, November 2004, 17-26.
- [7] Patel, A.T., Gaines, K., Malamut, R., Park, T., Del Toro, D. and Holland, N. (2005) Usefulness of Electrodagnostic Techniques in the Evaluation of Suspected Tarsal Tunnel Syndrome: An Evidence Based Review. *Muscle and Nerve*, **32**, 236-240. <https://doi.org/10.1002/mus.20393>



Scientific Research Publishing

**Submit or recommend next manuscript to SCIRP and we will provide best service for you:**

Accepting pre-submission inquiries through Email, Facebook, LinkedIn, Twitter, etc.

A wide selection of journals (inclusive of 9 subjects, more than 200 journals)

Providing 24-hour high-quality service

User-friendly online submission system

Fair and swift peer-review system

Efficient typesetting and proofreading procedure

Display of the result of downloads and visits, as well as the number of cited articles

Maximum dissemination of your research work

Submit your manuscript at: <http://papersubmission.scirp.org/>

Or contact [wjns@scirp.org](mailto:wjns@scirp.org)

