

# Silent Contained Rupture of an Inflammatory IgG4-Related Abdominal Aortic Aneurysm

Elpiniki Tsolaki<sup>1\*</sup>, Francesca Papadopulos<sup>2</sup>, Vincenzo Gasbarro<sup>1</sup>, Pierfilippo Acciarri<sup>1</sup>,  
Francesco Mascoli<sup>1</sup>

<sup>1</sup>Unit of Vascular and Endovascular Surgery, Department of Surgical Anesthesiological and Radiological Sciences,  
University of Ferrara, Ferrara, Italy

<sup>2</sup>Department of Specialistic Surgery and Anesthesiological Sciences, University of Bologna S. Orsola-Malpighi Hospital,  
Bologna, Italy

Email: \*niki.tsolaki@gmail.com

Received May 17, 2013; revised June 15, 2013; accepted June 29, 2013

Copyright © 2013 Elpiniki Tsolaki *et al.* This is an open access article distributed under the Creative Commons Attribution License, which permits unrestricted use, distribution, and reproduction in any medium, provided the original work is properly cited.

## ABSTRACT

This report describes a case of a 66-year-old male patient with accidental diagnosis of chronic contained rupture of an aortic aneurysm. Surgery was performed through a median laparotomy. A thick periaortic tissue with fibrosis and lymphnodes covered the AAA. Immunohistochemical examination of the aneurismatic aortic wall revealed intense positivity for inflammatory markers and a large number of immunoglobulin G4 (IgG4) positive cells. The postoperative course was uneventful and patient was discharged in the fifth postoperative day. Patient was then followed periodically at the outpatient rheumatologic clinic. No adverse events occurred during 3 and 6 months follow up. Conclusion: Identification of IgG4-inflammatory aneurysms as an expression of the IgG4-related systemic disease is essential both for clinical follow up and surgical and pharmacological treatment considering the possibility of aneurysm rupture and the involvement of other organs.

**Keywords:** Inflammatory Aortic Aneurysm; IgG4-Related Systemic Disease

## 1. Introduction

This report describes a case of chronic contained rupture of an IgG4 related inflammatory aortic aneurysm that is treated surgically.

## 2. Case Report

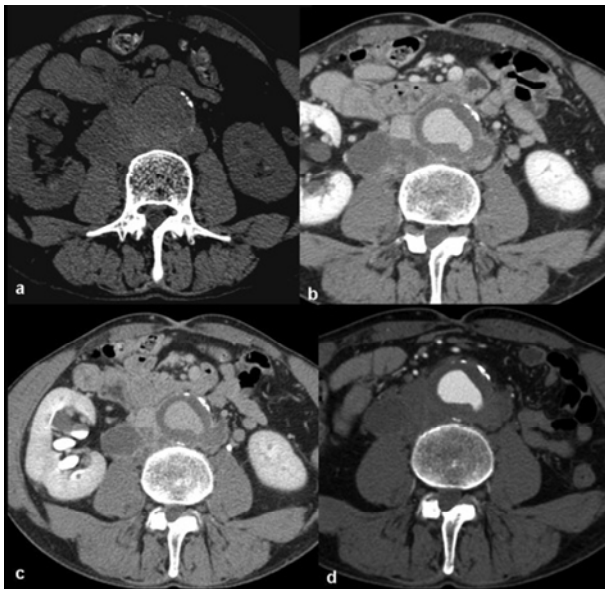
A 66-year-old male patient with a clinical history of a solitary pulmonary nodule underwent a routine follow up with a thoracic CT scan. Since the patient had a previous diagnosis of renal colic, due to kidney stones, the CT scan examination was extended to the abdomen. In addition, the patient also had a history of hypertension and smoking. The CT scan showed an infrarenal abdominal aortic aneurysm (AAA) of 42 × 40 mm (maximum diameter) with thick periaortic fibrotic tissue, especially on the left, lateral side. The aortic margins were poorly defined at the lower left and right posterior abdominal wall (**Figures 1(a)-(d)**). In addition, they appeared indistinguishable from periaortic soft tissue lobulated masses

that presented variable contrast enhancement. In particular, ulceration of the posterior aortic wall was observed (**Figures 1(c), (d)**). Physical examination revealed abdominal tenderness, a pulsating periumbilical mass and moderate pain in the mesogastric region and at the lower quadrants, during deep palpation. Bilateral peripheral pulses were present. Blood pressure was 140/70 mmHg and laboratory exams showed haemoglobin levels to be 17 g/dl; white blood cells were 9.600/l, D-Dimer was at 1275 ng/ml, fibrinogen at 436 mg/dl, creatinine at 0.8 mg/dl and CRP at 0.9 mg/dl. Both blood and urine culture tests were negative.

The CT scan and clinical examination findings suggested a chronic contained rupture of an AAA with few inflammatory features; therefore an urgent surgical approach was decided upon, since an appropriate endovascular device was not available and the patient was at low risk for surgical complications

Surgery was performed through a median laparotomy. There were no signs of hemorrhage in the peritoneum or in the retroperitoneum. A thick periaortic tissue with fibrosis and lymphnodes covered the AAA. Once the

\*Corresponding author.

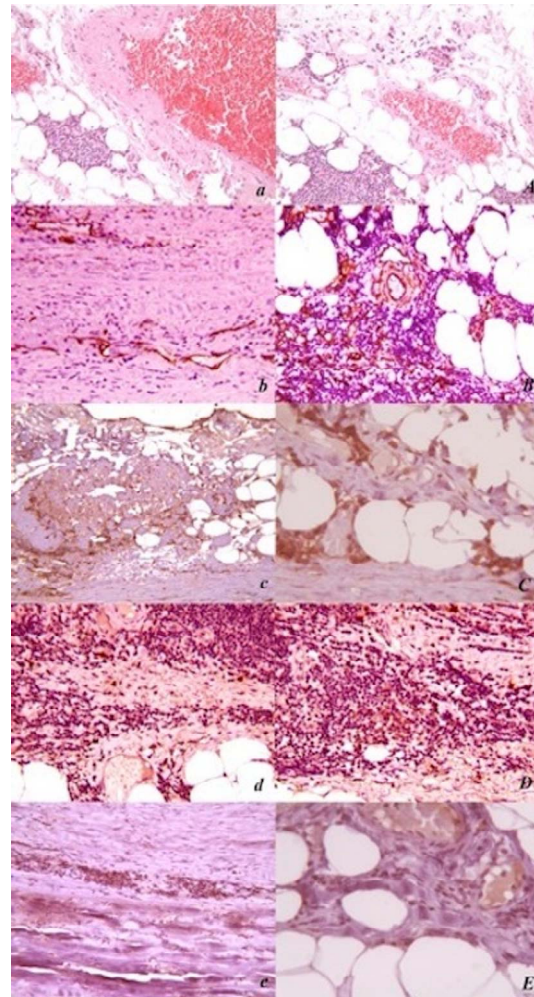


**Figure 1.** (a)-(d) Aortic margins appeared poorly defined in the lower left and right posterior abdominal walls; (c), (d) Periaortic soft tissue lobulated mass with variable contrast enhancement and ulceration of the posterior aortic wall.

aneurismal sac was opened, besides the presence of an organised thrombus, 3 different sites of rupture on the left and right lower posterior wall were discovered and appeared to contain blood clots. The AAA was repaired with a straight Dacron graft.

Histological and immunohistochemical tests, together with culture tests, were performed on the aortic wall specimens in order to complete diagnosis. For conventional histopathological analysis, the sections were stained with haematoxylin & eosin (H&E), according to routine histological procedures and were observed with light microscopy. Immunohistochemical studies were completed using specific antibodies to detect inflammatory pathogenic mechanisms typical of the aortic aneurism pathology. The specimens were processed using Novolink Reagents (NovoLink™ Polymer Detection System, Novocastra) according to the manufacturer's instructions. Histological examination demonstrated the presence of intense inflammatory mononuclear infiltrate associated with lymphoid follicles. Immunohistochemical examination of the aneurysmatic aortic wall revealed intense positivity for inflammatory markers such as CD34, CD44 and Tryptase, especially in a specific area near the vasa vasorum. In addition, a large number of immunoglobulin G4 (IgG4)-positive cells were detected in the inflammatory infiltrates (**Figure 2**). Fungal and *mycobacteria* culture tests, together with a fluorescent treponemal antibody absorption test (FTA-Abs), were negative.

The postoperative course was uneventful and the patient was discharged in the fifth postoperative day. The



**Figure 2.** ((a), (A)) Immunohistochemistry of the aneurysmatic aortic wall: E/E; (b), (B) Positive results for inflammatory markers close to vasa vasorum area CD34; (c), (C) CD44; (d), (D) Tryptase; (e), (E) is showing a large number of immunoglobulin G4 (IgG4)-positive cells. Original images were taken at 10 X.

patient was then followed periodically at the outpatient rheumatologic clinic. No adverse events had occurred at the 3 and 6-month routine exams.

### 3. Discussion

Inflammatory aneurysms (IAAA) represent a subgroup of aortic aneurysms of controversial etiology and account for 5% - 10% of all cases of AAA. IgG4-related systemic disease (IgG4-RSD) is a disease of unknown pathogenesis and is characterised by high serum IgG4 concentrations, sclerosing inflammation with numerous IgG4-positive plasmacytes, responsiveness to steroid therapy and occurrence (synchronous or metachronous) in multiple organs such as the pancreas [1], hepatobiliary tract [2], Salivary gland [3], lung, retroperitoneum [4] and others. IgG4-RSD usually affects middle-aged and elder-

ly patients, with a larger proportion of cases occurring in males. Vascular lesions represent another expression of the disease. Kasashima *et al.* [5,6] recently identified a subtype of inflammatory aortic aneurysms (IAAA) with clinicopathological features of the IgG4-RSD, characterised by aortitis, IgG4-positive plasmacyte infiltration at the aneurismatic aortic wall and obliterative phlebitis [7].

Chronic contained rupture of an IgG4I-AAA is extremely rare. As far as we know there is only one case in the literature describing a rupture of a paravisceral AAA related to IgG4 aortitis [8]. Interestingly, in our case the patient was completely asymptomatic both for AAA rupture and for any autoimmune disease and only the CT findings led us to suspect rupture, to therefore perform a semi-urgent treatment, and finally confirm the contained rupture. Surgical treatment allowed the histological and immunohistochemical examination of the aortic wall tissue, and revealed the inflammatory state of the aortic wall, consisting of intense inflammatory mononuclear infiltrates, associated with lymphoid follicles, and the presence of IgG4-positive plasmacytes. Such findings were suggestive of the subtype of IAAA related to the IgG4-RSD. Since there were no signs of involvement of other organs and the IgG4 plasma levels were low, no immunosuppressive pharmacological therapy was administered. However, considering that IgG4-RSD progression may involve other organs and have a relapsing-remitting course, a closer follow up for this patient was established in order to control and prevent further complications of this systemic disease.

#### 4. Conclusion

Identification of IgG4-inflammatory aneurysms as a subtype of inflammatory aneurysms is essential for a patient's clinical follow up, considering the possibility of systemic involvement.

#### REFERENCES

- [1] H. Hamano, S. Kawa, A. Horiuchi, H. Unno, N. Furuya, T. Akamatsu, *et al.*, "High Serum IgG4 Concentrations in Patients with Sclerosing Pancreatitis," *New England Journal of Medicine*, Vol. 344, No. 10, 2001, pp. 732-738. [doi:10.1056/NEJM200103083441005](https://doi.org/10.1056/NEJM200103083441005)
- [2] Y. Nakanuma and Y. Zen, "Pathology and Immunopathology of Immunoglobulin G4-Related Sclerosing Cholangitis: The Latest Addition to the Sclerosing Cholangitis Family," *Hepatology Research*, Vol. 37, Suppl. S3, 2007, pp. S478-S486. [doi:10.1111/j.1872-034X.2007.00243.x](https://doi.org/10.1111/j.1872-034X.2007.00243.x)
- [3] J. T. Geyer, J. A. Ferry, N. L. Harris, J. H. Stone, L. R. Zukerberg, G. Y. Lauwers, *et al.*, "Chronic Sclerosing Sialadenitis (Küttner Tumor) Is an IgG4-Associated Disease," *The American Journal of Surgical Pathology*, Vol. 34, No. 2, 2010, pp. 202-210. [doi:10.1097/PAS.0b013e3181c811ad](https://doi.org/10.1097/PAS.0b013e3181c811ad)
- [4] Y. Zen, D. Inoue, A. Kitao, M. Onodera, H. Abo, S. Miyayama, *et al.*, "IgG4-Related Lung and Pleural Disease: A Clinicopathologic Study of 21 Cases," *The American Journal of Surgical Pathology*, Vol. 33, No. 12, 2009, pp. 1886-1893. [doi:10.1097/PAS.0b013e3181bd535b](https://doi.org/10.1097/PAS.0b013e3181bd535b)
- [5] S. Kasashima, Y. Zen, A. Kawashima, K. Konishi, H. Sasaki, M. Endo, Y. Matsumoto, K. Kawakami, F. Kasashima, M. Moriya, K. Kimura, H. Ohtake and Y. Nakanuma, "Inflammatory Abdominal Aortic Aneurysm: Close Relationship to IgG4-Related Periaortitis," *The American Journal of Surgical Pathology*, Vol. 32, No. 2, 2008, pp. 197-204. [doi:10.1097/PAS.0b013e3181342f0d](https://doi.org/10.1097/PAS.0b013e3181342f0d)
- [6] S. Kasashima and Y. Zen, "IgG4-Related Inflammatory Abdominal Aortic Aneurysm," *Current Opinion in Rheumatology*, Vol. 23, No. 1, 2011, pp. 18-23. [doi:10.1097/BOR.0b013e3181342f0d](https://doi.org/10.1097/BOR.0b013e3181342f0d)
- [7] S. Kasashima, Y. Zen, A. Kawashima, K. Konishi, H. Sasaki, M. Endo, *et al.*, "Inflammatory Abdominal Aortic Aneurysm: Close Relationship to IgG4-Related Periaortitis," *The American Journal of Surgical Pathology*, Vol. 32, No. 2, 2008, pp. 197-204. [doi:10.1097/PAS.0b013e3181342f0d](https://doi.org/10.1097/PAS.0b013e3181342f0d)
- [8] M. Trinidad-Hernandez and A. A. Duncan, "Contained Ruptured Paravisceral Aortic Aneurysm Related to Immunoglobulin G4 Aortitis," *Annals of Vascular Surgery*, Vol. 26, No. 1, 2012, pp. 1-4.