

# Aspergilloma in a Pulmonary Hydatid\*

Nikhil Tiwari<sup>#</sup>, Ramesh Kaushik, Gaurav Kumar, Gautam Ganguly, Shabaz Hasnain

Department of Cardiothoracic Surgery, Military Hospital (CTC), Pune, India

Email: <sup>#</sup>[nikhil1972@rediffmail.com](mailto:nikhil1972@rediffmail.com)

Received May 6, 2013; revised June 13, 2013; accepted June 22, 2013

Copyright © 2013 Nikhil Tiwari *et al.* This is an open access article distributed under the Creative Commons Attribution License, which permits unrestricted use, distribution, and reproduction in any medium, provided the original work is properly cited.

## ABSTRACT

Aspergilloma infection in the lung can occur in preexisting cavities and is usually seen after tuberculosis, pulmonary infarction and bronchestasis. Occasionally aspergilloma has been reported within a hydatid cyst. We describe a patient with aspergilloma formed within cyst hydatid. The primary symptom in this patient was recurrent hemoptysis. In this 42-year-old male, the diagnosis was established by HRCT chest. Treatment consisted of postero-lateral thoracotomy with a bilobectomy of lower and middle lobe. Aspergilloma is an unusual complication of hydatid cyst and results from the deterioration of local defence against opportunistic infections.

**Keywords:** Tuberculous Cavity; Lung Hydatid Cyst; Aspergilloma

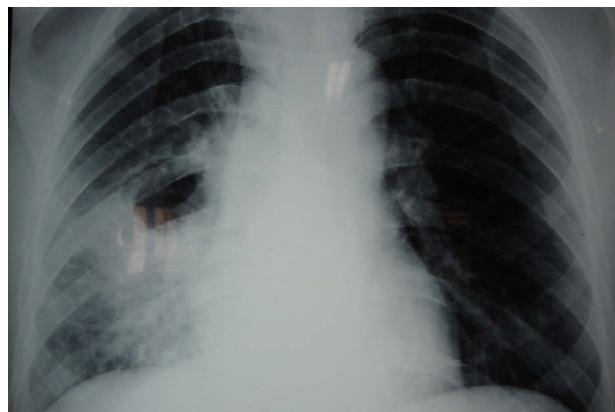
## 1. Introduction

Pulmonary aspergilloma generally complicates an existing cavity that was due to tuberculosis; however, it can develop in any kind of pulmonary cavity. Regnard *et al.* reported growth of aspergilloma in a post-tuberculosis cavity in 69% in their series [1] and rarely in hydatid cyst cavities [2]. A review of literature shows isolated case reports with aspergilloma invading residual cavities left after cystectomy in lung hydatid [3,4]. Julio C. Vasquez *et al.* in their article recommend anatomic lung resection for such cases. A positive diagnosis relies on direct identification of *Aspergillus* species or serodiagnosis. A serodiagnosis is almost always positive in chronic infections and is detected by immunoelectrophoresis or a single precipitation with catalase activity. The rarity of aspergilloma within hydatid cyst probably occurs due to the different elective site for the two diseases. The development of aspergilloma on cyst residual cavities can occur in the early post-operative period and alternatively after many years. The coexistence of hydatid cyst and aspergillosis is extremely rare [5,6] and such an association has been reported in both immunocompromised and immunocompetent patients.

## 2. Case Report

44 yrs old male presented to us with a history of recurrent bouts of cough with haemoptysis. He gave a history

of a diffuse right sided chest pain. He was a nonsmoker, had undergone a six month course of ATT two years back for pulmonary Koch. His clinical examination was not contributory. A chest roentgenogram (**Figure 1**) revealed a cavity in the right mid zone (RMZ) with prominent vascular markings. A high resolution CT (**Figure 2**) revealed a soft tissue mass in superior segment of the right lower lobe with a thin crescentic lucency which changes with patient's position suggestive of aspergilloma with adjacent lung consolidation. Bilateral pleural thickening was also noted. A fiberoptic bronchoscopy revealed a normal tracheobronchial tree. Fungal stains & culture, Gram stains, pyogenic culture, AFB & MTB cultre & a Polymerase chest reaction (PCR) of bron-



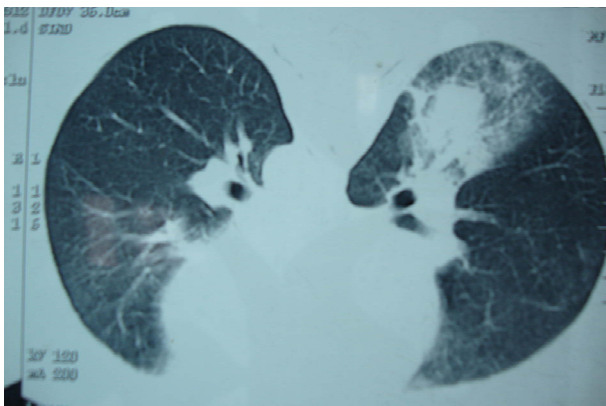
**Figure 1. CXR: Cavity within the RMZ & RLZ consolidation.**

\*Conflict of interest: Authors have no conflict of interest.

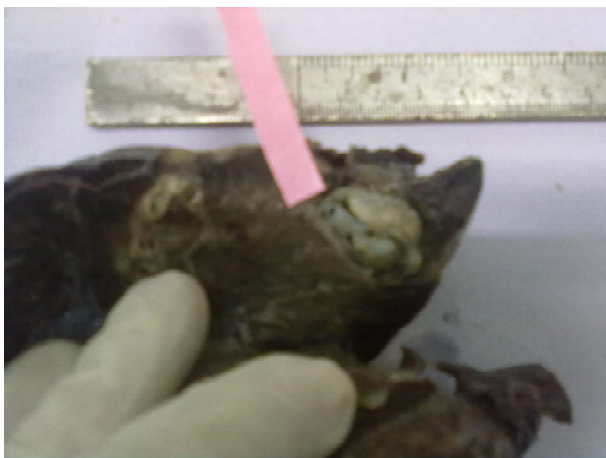
<sup>#</sup>Corresponding author.

chosopic alveolar lavage from the superior segment of RLL were negative for AFB and fungus. His spirometry was normal. He was planned for (Rt) lower lobectomy or a bilobectomy. While awaiting surgery he had a major bout of haemoptysis necessitating bronchial artery embolization and was taken up for surgery 48 hrs later. A left posterolateral thoracotomy was done through the 5<sup>th</sup> ICS. Intraoperatively extensive adhesions were noted between the chest wall and the lungs. The fissures between upper & lower lobes were fused & RML was collapsed. A 5 × 5 × 5 cm lesion was noted in RLL abutting the upper lobe and densely adherent to it hence a bilobectomy (RLL & RML) was done.

Grossly the cut surface showed an apical 3.5 × 3 × 2 cm cyst with a fibrous wall containing a delicate white membrane (**Figure 3**). Microscopy revealed a fibrous pericyst containing a dominated chitinous membranous material. Septate narrow angle branching filaments and fungal spores were seen on the outer wall as well as surrounding lung showed focal edema, congestion, mixed inflammatory infiltrate, necrosis & dilated bronchioles. No invasion of fungal hyphae into lung parenchyma was



**Figure 2.** CT scan: Soft tissue mass sup segment RLL.



**Figure 3.** A fibrous pericyst containing a dominated chitinous membranous.

noted.

Final HPE report was—Hydatid cyst (Rt) lung lower lobe with *Aspergillus* colonization. Post operatively he continued to have a prolonged drainage (150 ml) in the intercostal drains lasting for three weeks which then suddenly subsided. Patient was administered Tab Albendazole 400 mg BD as pulse therapy. He has had an uneventful recovery with good expansion of the remaining lung.

### 3. Discussion

Aspergilloma is a common form of pulmonary fungal infection and has a tendency to occur in tubercular cavities, on rare occasions it may occur in hydatid cavities [5-7]. The most common sites of aspergilloma and hydatid cyst are respectively the upper lobe and the lower lobe of the lung. Such association has been reported in both immunocompromised and immunocompetent patients [8]. The single most important pointer for aspergilloma is its mobility in different positions. The differential diagnosis of *Aspergillus* colonies entrapped in a hydatid cyst is tuberculosis, malignancy, an intact hydatid cyst, or a necrotizing pulmonary abscess [8].

Surgery is the mainstay of treatment of this opportunistic pulmonary mycosis. Recommended surgical treatment for aspergilloma in patients with adequate pulmonary function is lung resection [9]. Anatomic lung resection is advised in pulmonary aspergilloma as there is uncertainty in how much lung parenchyma should be removed to safely resect the lesion. Hemoptysis is a known presentation in pulmonary hydatid cyst and also pulmonary aspergillosis, which was the presenting symptom in our patient [10]. Hepatic cysts are noted in 20% of such cases however our case did not have any hepatic cysts [11]. In conclusion we present a rare case and suggest that an association between aspergilloma with hydatid must be kept in mind when dealing with pulmonary aspergillosis.

### 4. Literature Review

There are very few isolated case reports describing coexistence of aspergilloma in a hydatid cavity. Sameh M'saad *et al.* [12] describe two such cases who initially presented with recurrent hemoptysis. They were treated with a postero-lateral thoracotomy with wedge resection of aspergilloma in the left upper lobe because of massive hemoptysis. In both cases, patients progressed favourably without antifungal therapy. They describe aspergilloma as an unusual complication of hydatid cyst resulting from the deterioration of local defence against opportunistic infections. Prognosis appears to be better than aspergilloma within tuberculous cavities. Buzdar, M.S. *et al.* describe invasive aspergillosis in a ruptured hydatid cyst

[2] in a patient earlier treated for pulmonary Koch's and who had fever and recurrent hemoptysis and was managed successfully with a wedge resection.

## REFERENCES

- [1] J. F. Regnard, P. Icard, M. Nicolosi, L. Spaggiari, P. Magdeleinat, B. Jauffret and P. Levasseur, "Aspergilloma: A Series of 89 Surgical Cases," *The Annals of Thoracic Surgery*, Vol. 69, No. 3, 2000, pp. 898-903. [doi:10.1016/S0003-4975\(99\)01334-X](https://doi.org/10.1016/S0003-4975(99)01334-X)
- [2] B. M. S. Nabi, K. K. Chima, N. Tarif, I. Sultan and S. T.-I. Gilani, "Invasive Aspergillosis of Pulmonary Hydatid Cyst," *Annals of Saudi Medicine*, Vol. 29, No. 1, 2009, pp. 53-54. [doi:10.4103/0256-4947.51824](https://doi.org/10.4103/0256-4947.51824)
- [3] N. G. Ulasan, K. Dural, E. Yildirim, K. Ozisik and U. Sakinci, "An Intracavitary Aspergilloma after Echinococcal Cystectomy," *The Journal of Cardiovascular Surgery*, Vol. 44, No. 2, 2003, pp. 289-290.
- [4] B. Aydemir, C. Aydemir, T. Okay, M. Celik and K. Dogusoy, "An Aspergilloma in an Echinococcal Cyst Cavity," *The Journal of Thoracic and Cardiovascular Surgery*, Vol. 54, 2006, pp. 353-355. [doi:10.1055/s-2006-924092](https://doi.org/10.1055/s-2006-924092)
- [5] B. Addis, "Pulmonary Mycotic Disease," In: P. S. Hasleton, Ed., *Spencer's Pathology of the Lung*, 5th Edition, McGraw-Hill, New York, 1996. pp. 257-265.
- [6] N. E. Kocer, Y. Kibar, M. E. Guildur, H. Deniz and K. Bakir, "A Retrospective Study on the Coexistence of Hydatid Cyst and Aspergillosis," *International Journal of Infectious Diseases*, Vol. 12, No. 3, 2008, pp. 248-251. [doi:10.1016/j.ijid.2007.08.005](https://doi.org/10.1016/j.ijid.2007.08.005)
- [7] J. C. Vasquez, E. Montesinos, L. Rojas, J. Peralta, J. Delarosa and J. J. Leon, "Surgical Management of Aspergillus Colonization Associated with Lung Hydatid Disease," *Annals of Thoracic and Cardiovascular Surgery*, Vol. 14, No. 2, 2008, pp. 116-118.
- [8] B. V. John, M. Jacob, O. C. Abraham, S. Thomas, R. Thankachan and V. Shukla, "Aspergilloma in Hydatid Cavity," *Tropical Doctor*, Vol. 37, 2007, pp. 112-114. [doi:10.1258/004947507780609347](https://doi.org/10.1258/004947507780609347)
- [9] U. Kini, "Invasive Mycosis of Pulmonary Hydatid Cyst in a Non Immunocompromised Host," *Journal of Tropical Medicine & Hygiene*, Vol. 98, No. 6, 1995, pp. 404-406.
- [10] A. O. Soubani and P. H. Chandrasekar, "The Clinical Spectrum of Pulmonary Aspergillosis," *Chest*, Vol. 121, No. 6, 2002, pp. 1988-1999. [doi:10.1378/chest.121.6.1988](https://doi.org/10.1378/chest.121.6.1988)
- [11] G. Bhatia, "Echinococcus," *Seminars in Respiratory Infections*, Vol. 12, 1997, pp. 171-186.
- [12] S. M'saad, L. Ayedi, M. Abdennader, N. Bahloul, A. Hentati, C. Dabbech, I. Frikha, T. Boudawara and A. Ayoub, "Aspergilloma in a Hydatid Cavity," *Respiratory Medicine CME*, Vol. 3, No. 1, 2010, pp. 29-32. [doi:10.1016/j.rmedc.2009.02.002](https://doi.org/10.1016/j.rmedc.2009.02.002)