

# A Curious Case of Recurrent Umbilical Swelling: Case Report and Literature Review

Shahd Nour\*, Najam Husain, Naseem Waraich

Department of General Surgery, Queen's Hospital Burton NHS Foundation Trust, Burton-on-Trent, UK

Email: \*shahd.nour@nhs.net

**How to cite this paper:** Nour, S., Husain, N. and Waraich, N. (2018) A Curious Case of Recurrent Umbilical Swelling: Case Report and Literature Review. *Surgical Science*, 9, 480-486.

<https://doi.org/10.4236/ss.2018.912055>

**Received:** July 6, 2018

**Accepted:** December 15, 2018

**Published:** December 19, 2018

Copyright © 2018 by authors and Scientific Research Publishing Inc.

This work is licensed under the Creative Commons Attribution International License (CC BY 4.0).

<http://creativecommons.org/licenses/by/4.0/>



Open Access

## Abstract

**Background:** Umbilical endometriosis, a rare benign condition, is clinically difficult to differentiate from other diseases that result in the formation of an umbilical nodule. It is caused by the presence of ectopic endometrial tissue in the umbilicus, which overtly presents as a painful, discoloured swelling in the umbilicus. However, in our case the presentation wasn't as obvious. The endometrial tissue was embedded within an umbilical hernia. **Case Summary:** Our patient was a 37-year-old female with a past medical/surgical history of a subtotal colectomy for ulcerative colitis in 2001 followed by an ileo-rectal anastomosis. 17 years later, she was referred to the surgical outpatient clinic from GP practice with a painful umbilical/incisional hernia surrounding the previous scar and just above the umbilicus, this pain, particularly worsening during her menstrual cycle. Multiple blood tests and ultrasound scans of her abdomen failed to diagnose a cause for her agony which mandated an elective excision of the swelling. This successfully resolved her symptoms. **Conclusion:** Umbilical endometriosis is a potential diagnosis in females with a painful umbilical swelling, imaging has no diagnostic role and excision is the definitive treatment.

## Keywords

Umbilical Endometrioma, Endometriosis, Case Report, Total Umbilical Resection

## 1. Introduction

Endometriosis is defined as the presence of endometrial glands and stroma outside the uterus affecting 3% to 10% of women in the reproductive age. However, endometriosis of the umbilical region is infrequent and when present in an umbilical hernia, it is exceptionally precocious.

This has been noted to occur only in 0.5% - 1% of all patients with endometrial ectopia—the first description of which is credited to Villar in 1886, hence the term “Villar’s nodule”.

We present a case of recurrent umbilical swelling, simple enough to be easily dismissed but complex enough to contain endometrial tissue and confuse with a sister Joseph’s nodule. Especially that the clinical presentation was not as typical as expected.

## 2. Case Presentation

A 37-year-old Caucasian woman was referred from GP practice with a painful incisional hernia surrounding a previous scar; the pain particularly worsening during her menstrual cycle and associated with enlarging in size of the hernia. Known to have IBD, she had previously had a subtotal colectomy for ulcerative colitis in 2001 followed by an ileo-rectal anastomosis which she was managing well.

Shortly after, she unfortunately developed an umbilical hernia at the caudal end of her midline scar associated with cyclical swelling and severe peri-umbilical pain. After being thoroughly investigated at her GP practice in terms of, blood tests and ultrasound scans—all of which revealed no abnormalities, she was referred to the surgical team for further evaluation as she was not tolerating the pain. During her consultation at our outpatient clinic she described a peri-umbilical sinus which has spontaneously healed a few years ago.

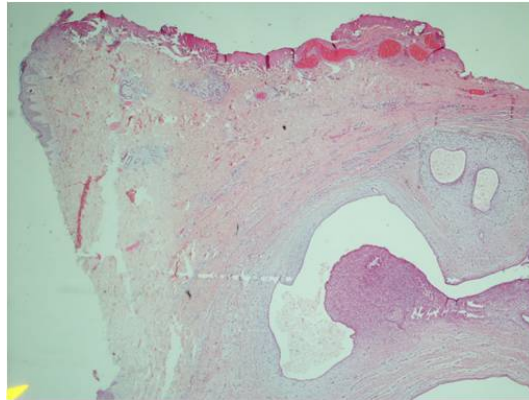
She was otherwise fit and well, not on any medications and declared no known drug allergies.

On examination she was clinically well, abdominal palpation not only revealed a tiny supra-umbilical hernia but also a healed periumbilical stitch granuloma measuring approximately 1 cm in diameter.

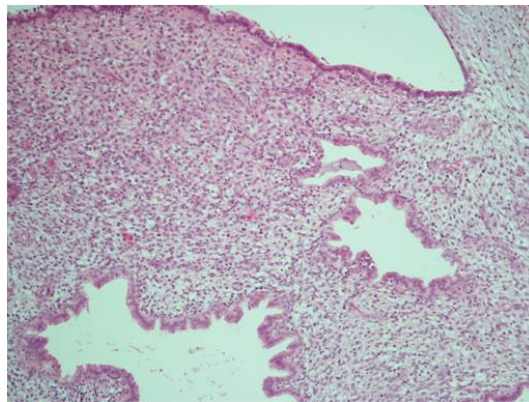
A repeat set of blood tests were sent off to the lab, all parameters were reported to be well within normal range (including inflammatory markers). Thereafter, an ultrasound scan was organized which revealed a hypodense nodule correlating with the stitch.

After obtaining informed consent she underwent an elective incisional hernia repair with the excision of the umbilical stitch granuloma.

A midline incision was made through the existing scar—a tiny caudal defect was identified measuring 0.5 cm, the hernia sac was reduced and defect closed. A hard umbilical lesion was also located, mobilized and excised en-bloc with skin. The operation itself was uneventful. The wound was then closed in layers and the biopsy sent for histological reporting. On slicing of the lesion, the pathologist found it to be of a cystic consistency and identified benign endometrial glands, stroma, hemosiderin deposits and fibrosis were present (**Figure 1** and **Figure 2**)—all in keeping with endometriosis. Luckily no atypical features were recognized.



**Figure 1.** Histological images of the excised umbilical lesion  $\times 2$  low power magnification showing epidermis on the left upper part, dermis with endometrial glands and stroma towards the right.



**Figure 2.** Histological images of the excised umbilical lesion  $\times 10$  magnification showing benign endometrial glands and stroma.

### 3. Final Diagnosis

Umbilical endometriosis secondary to an umbilical hernia.

No further treatment was required after excision and repair of the lesion.

### 4. Outcome and Follow-Up

The patient was seen in clinic 6 weeks later and reported feeling much better after the operation. She remained asymptomatic, there was no evidence of clinical recurrence and thereafter, was discharged from surgical care.

### 5. Discussion

Endometriosis is a benign inflammatory disease characterized by the presence of estrogen dependent extra-uterine endometrial glands effecting 10% at the reproductive age of the women. It presents with a conglomerate of symptoms like turbulence of hormonal imbalances, chronic pain and infertility.

The most common locations of the extra-gonadal endometriosis are the lower

parts of the gastrointestinal tract and the peritoneal surfaces [1] with more than 80% of the endometriosis cases primarily involve the ovaries followed the appendix, intestine, cervix, omentum, and skin [2].

The majority of cutaneous endometriosis occur secondary to abdominopelvic surgery. Spontaneously, cutaneous endometriosis commonly happens in the umbilicus, followed by the inguinal region and rarely the lateral abdominal wall could be involved [3].

Umbilical endometriosis is further classified as primary if it occurs spontaneously or secondary if it results from iatrogenically-seeded endometrial implants following various surgical procedures, with the latter being more common [4] [5].

The pathogenesis of primary umbilical endometriosis remains unclear. Possible theories for this disorder could be the migration of endometrial cells to the umbilicus through the abdominal cavity, the lymphatic system, or through the embryonic remnants in the umbilical fold such as the urachus and the umbilical vessels, genetic predisposition, and immunological defects [6].

On the other hand, development of secondary umbilical endometriosis usually follows laparoscopic surgical procedures involving the umbilicus [7]. This occurs through the dissemination of endometrial implants to the umbilical region and other areas which may occur in a surgical setting where direct exposure of endometrial tissue occurs to tissue tracts and blood vessels exposed by mechanical disruption. The fibrin-rich surfaces of incisions provide viable sites for deposition of angiogenic endometrial implants [8].

In this case, the patient's surgical history of a midline scar was consistent with secondary umbilical endometriosis.

Extra-pelvic endometriosis is difficult to diagnose due to the extreme variability in presentation. Umbilical endometriosis usually manifests as a nodule of variable size. A characteristic sign for this lesion is the simultaneous sanguinolent discharges with menstruation. Clinical symptoms typically include pain, bleeding, and swelling concurrently with menstruation, however others are asymptomatic [9] [10]. The presence of a previous history of endometriosis is common (26% of cases) [11], frequently associated with complaints of dysmenorrhoea, dyspareunia, or defecation pain [2].

Non-invasive tests for endometriosis such as CT, MRI, ultrasonography, and serum carbohydrate antigen 125 levels are all commonly used, but the results of these screening procedures are inconclusive [3].

In umbilical endometriosis specifically, both CT scan and MRI generally demonstrate a solid well-circumscribed mass, define the size and locations of the lesions and exclude the possibility of intraabdominal extension [8] [12] [13] [14]. But, more often than not, definitive diagnosis is only confirmed by visual inspection via laparotomy or laparoscopy [3] or histopathology following surgical exploration and excision of the underlying lesion.

As a result, multiple studies have reported a delay in the diagnosis of endometriosis [15].

Luckily, several symptoms can be predictive of endometriosis such as severe dysmenorrhoea in infertile women, abdominopelvic pain, dysmenorrhoea, heavy menstrual bleeding, infertility, dyspareunia, postcoital bleeding and/or previous diagnosis of ovarian cyst, irritable bowel syndrome, or pelvic inflammatory disease [16] and these symptoms and signs can help us to consider the diagnosis of endometriosis when an umbilical nodule is present.

Once diagnosed, endometriosis is quite challenging to manage given both its unknown cause and tendency to progress and recur despite treatment.

The best approach in these situations is the total removal of the umbilicus with an adequate rim of normal tissue around [17] as the medical treatment of umbilical endometriosis, based on hormonal therapy (norethisterone, progesterone, danazole, gonadotropin-releasing hormone analogue) often fails to control the disease [18] [19].

The histological features required for the diagnosis of endometriosis are the concomitant presence of two of the three following characteristics: endometrial-like glands, endometrial stroma, or hemosiderin pigment [20].

Other causes of umbilical nodules range from benign ones such as, cutaneous endometriosis/endsalpingosis, haemangioma/vascular malformation, umbilical hernia, sebaceous cyst, lipoma, granuloma (which was an initial first suspect in our case), abscess and keloids, to malignant pathologies like sister joseph nodes, sarcoma, lymphoma and melanomas.

Umbilical endometriosis in particular is of interest to the general surgeon as it may be mistaken for a suture granuloma (as above), melanoma, cyst, abscess or a metastatic deposit from a systemic malignancy [21].

## 6. Conclusions

Surgical site associated umbilical endometriosis is a relatively rare form of endometriosis, which leads to delayed presentation to the surgeons after all investigations fail to diagnose a disease.

The suspicion of the diagnosis of umbilical endometriosis is based on the clinical presentation, but the definitive diagnosis should always be confirmed by histological examination following biopsy or resection.

## Authors' Contributions

Nour, S. conceived the study, data collection and analysis, provided the images and drafted first manuscript; Husain, N. data analysis, drafted final manuscript; Waraich, N. review of draft and final manuscript.

## Supportive Foundations/Source of Funding

Not applicable for the purpose of this study.

## Informed Consent Statement

Written informed consent was obtained from the patient for publication of this

case report and accompanying images. A copy of the written consent is available for review by the Editor-in-Chief of this journal.

## Conflicts of Interest

The authors declare that they have no conflicts of interest.

## References

- [1] Panicker, R., Pillai, N. and Nagarsekar, U. (2010) Villar's Nodule: A Rare Presentation of External Endometriosis. *MJAFI*, **66**, 70-713.
- [2] Kyamidis, K., Lora, V. and Kanitakis, J. (2011) Spontaneous Cutaneous Umbilical Endometriosis: Report of a New Case with Immunohistochemical Study and Literature Review. *Dermatology Online Journal*, **17**, 5.
- [3] Andrade, M.T., de Freitas, C.V.M., Câmara, S.F.C. and Vieira, J.J.N. (2016) Umbilical Nodule with Cyclical Bleeding: A Case Report and Literature Review of Atypical Endometriosis. *Case Reports in Obstetrics and Gynecology*, **2016**, Article ID 7401409. <https://doi.org/10.1155/2016/7401409>
- [4] Victory, R., Diamond, M.P. and Johns, D.A. (2007) Villar's Nodule: A Case Report and Systematic Literature Review of Endometriosis Externa of the Umbilicus. *Journal of Minimally Invasive Gynecology*, **14**, 23-32. <https://doi.org/10.1016/j.jmig.2006.07.014>
- [5] Calagna, G., Perino, A., Chianetta, D., Vinti, D., Triolo, M.M., Rimi, C., et al. (2015) Primary Umbilical Endometrioma: Analyzing the Pathogenesis of Endometriosis from an Unusual Localization. *Taiwanese Journal of Obstetrics and Gynecology*, **54**, 306-312. <https://doi.org/10.1016/j.tjog.2014.03.011>
- [6] Groothuis, P.G., Koks, C.A., de Goeij, A.F., Dunselman, G.A., Arends, J.W. and Evers, J.L. (1998) Adhesion of Human Endometrium to the Epithelial Lining and Extracellular Matrix of Amnion *in Vitro*: An Electron Microscopic Study. *Human Reproduction*, **13**, 2275-2281. <https://doi.org/10.1093/humrep/13.8.2275>
- [7] Goldberg, J.M. and Bedaiwy, M.A. (2007) Recurrent Umbilical Endometriosis after Laparoscopic Treatment of Minimal Pelvic Endometriosis: A Case Report. *The Journal of Reproductive Medicine*, **52**, 551-552.
- [8] Yu, C.Y., Perez-Reyes, M., Brown, J.J. and Borrello, J.A. (1994) MR Appearance of Umbilical Endometriosis. *Journal of Computer Assisted Tomography*, **18**, 269-271. <https://doi.org/10.1097/00004728-199403000-00019>
- [9] Fernandes, H., Marla, N.J., Pailoor, K. and Kini, R. (2011) Primary Umbilical Endometriosis: Diagnosis by Fine Needle Aspiration. *Journal of Cytology*, **28**, 214-216. <https://doi.org/10.4103/0970-9371.86355>
- [10] Dessy, L.A., Buccheri, E.M., Chiummariello, S., Gagliardi, D.N. and Onesti, M.G. (2008) Umbilical Endometriosis, Our Experience. *In Vivo*, **22**, 811-815.
- [11] Arkoulis, N. and Chew, B.K. (2015) An Unusual Case of Asymptomatic Spontaneous Umbilical Endometriosis Treated with Skin-Sparing Excision. *Journal of Surgical Case Reports*, **3**, 1-3.
- [12] Yuen, J.S.P., Chow, P.K.H. and Koong, H.N. (2001) Unusual Sites (Thorax and Umbilical Hernia Sac) of Endometriosis. *Journal of the Royal College of Surgeons of Edinburgh*, **46**, 313-315.
- [13] Omori, M., Ogawa, T., Nara, M., Hashi, A. and Hirata, S. (2014) Umbilical Endometriosis with Giant Degenerated Uterine Leiomyomas: A Case Report. *Gyneco-*

*logic Oncology Case Reports*, **9**, 18-20. <https://doi.org/10.1016/j.gynor.2014.04.004>

- [14] Yu, C.-Y., Perez-Reyes, M., Brown, J.J. and Borrello, J.A. (1994) Mr Appearance of Umbilical Endometriosis. *Journal of Computer Assisted Tomography*, **18**, 269-271. <https://doi.org/10.1097/00004728-199403000-00019>
- [15] Dunselman, G.A.J., Vermeulen, N., Becker, C., et al. (2014) ESHRE Guideline: Management of Women with Endometriosis. *Human Reproduction*, **29**, 400-412. <https://doi.org/10.1093/humrep/det457>
- [16] Ballard, K.D., Seaman, H.E., De Vries, C.S. and Wright, J.T. (2008) Can Symptomatology Help in the Diagnosis of Endometriosis? Findings from a National Case-Control Study—Part 1. *BJOG: An International Journal of Obstetrics and Gynaecology*, **115**, 1382-1391. <https://doi.org/10.1111/j.1471-0528.2008.01878.x>
- [17] Fancellu, A., Pinna, A., Manca, A., Capobianco, G. and Porcu, A. (2013) Primary Umbilical Endometriosis. Case Report and Discussion on Management Options. *International Journal of Surgery Case Report*, **4**, 1145-1148. <https://doi.org/10.1016/j.ijscr.2013.11.001>
- [18] Pramanik, S.R., Mondal, S., Paul, S. and Joycerani, D. (2014) Primary Umbilical Endometriosis: A Rarity. *Journal of Human Reproductive Science*, **7**, 269-271. <https://doi.org/10.4103/0974-1208.147495>
- [19] Fedele, L., Frontino, G., Bianchi, S., Borruto, F. and Ciappina, N. (2010) Umbilical Endometriosis: A Radical Excision with Laparoscopic Assistance. *International Journal of Surgery*, **8**, 109-111. <https://doi.org/10.1016/j.ijisu.2009.11.006>
- [20] Papavramidis, T.S., Sapolidis, K., Michalopoulos, N., et al. (2009) Spontaneous Abdominal Wall Endometriosis: A Case Report. *Acta Chirurgica Belgica*, **109**, 778-781. <https://doi.org/10.1080/00015458.2009.11680536>
- [21] Stojanovic, M., Radojkovic, M., Jeremic, L., et al. (2014) Umbilical Endometriosis Associated with Large Umbilical Hernia. Case Report. *Chirurgia*, **109**, 267-270.