

Combined Hemostasis and Adhesion Prevention with the Novel Agent 4DryField® PH—Initial Observations

Matthias Korell

Department of Gynecology, Johanna-Etienne-Hospital, Neuss, Germany
Email: m.korell@ak-neuss.de

Received 23 September 2014; revised 20 October 2014; accepted 20 November 2014

Academic Editor: Vahit Ozmen, Istanbul University, Turkey

Copyright © 2014 by author and Scientific Research Publishing Inc.
This work is licensed under the Creative Commons Attribution International License (CC BY).
<http://creativecommons.org/licenses/by/4.0/>



Open Access

Abstract

Large size peritoneal trauma from extended surgery for high-grade expansive uterus pathology or endometriosis might result in severe diffuse bleeding and peritoneal adhesion formation with objectionable sequelae. This paper introduces 4DryField® PH polysaccharide powder certified for two indications: 1) given as powder 4DryField® PH provides hemostasis; 2) transformed into gel, 4DryField® PH forms an adhesion prevention barrier. Twenty-one women with expanded uterus pathology and/or deep infiltrating endometriosis had surgery including repair of intestine lesions (n = 8), ureterolysis/repair of bladder, including retrograde ureteric stents (n = 5). Subjective impression of hemostatic effect, drain loss and infection parameters were recorded. Six women had scheduled second look laparoscopy. 4DryField® PH applied as powder showed an immediate significant hemostatic effect in all instances, especially in profound diffuse bleeding. Mean drain loss was 497 ± 339 mL, moderate considering the extent of disease. Dripped with saline solution, 4DryField® PH immediately formed a viscous gel acting as a barrier for adhesion prevention. Second look laparoscopy revealed only one patient with significant adhesions. No adverse events were observed; discharge was at Day 6.2 ± 1.4 . In this cohort with extended gynecological laparoscopic surgery 4DryField® PH was very effective for hemostasis. The results of second look laparoscopies showed mainly no or minor adhesions. This can be considered very favorable regarding the extent of disease in these patients. Considering the twofold effect in hemostasis and adhesion prevention, 4DryField® PH is a very helpful tool especially in extensive and complicated surgeries. Prospective randomized studies are necessary to prove these promising results in larger series.

Keywords

Hemostasis, Adhesion Prevention, Polysaccharide, Gynecological Surgery

1. Introduction

Although procedures like hysterectomy or resection of endometriosis are generally considered safe, they are associated with several possible complications of which Infection and hemorrhage are reported to be the most frequent early ones [1]-[4].

In further course, adhesion formation must be regarded as the most common complication occurring after 60% - 90% of procedures [5]-[7]. Adhesions are responsible for a long list of sequelae ranging from the most frequent one, *i.e.* persistent pelvic pain, to the most frightening one, *i.e.* small bowel obstruction [5]-[8].

If surgery of endometriosis is necessary for treatment of infertility there is the dilemma that the surgical intervention might induce adnexal adhesions, which are an even more frequent cause for secondary female infertility than endometriosis.

4DryField® PH is a novel agent certified for both hemostasis and adhesion prevention. It is purely plant-based 4DryField® PH and consists of polysaccharide particles which have a high capability to absorb water. This provides a twofold effect:

1) Taking up water from wound blood leads to concentration of coagulation factors and blood cells, which accelerates the clotting enhancing hemostasis [10].

2) 4DryField® PH particles and fluid form a gel which is highly effective as a barrier against adhesion formation. The noticeable anti-adhesive properties of 4DryField® PH have been demonstrated in animal experiments [11].

This paper shows the use of 4DryField® PH for both hemostasis and adhesion prevention. In a first approach 4DryField® PH was only used in severe clinical cases: 1) complicated hysterectomies with extended areas of diffuse bleeding and 2) deep infiltrating endometriosis with large peritoneal defects. The hemostatic effect of 4DryField® PH is evaluated and its efficiency in adhesion prevention controlled on basis of second look laparoscopy.

2. Patients and Methods

The present study includes 21 patients who underwent extensive surgery, either complicated hysterectomy and/or resection of deep infiltrating endometriosis leaving large areas of peritoneal defects. The patients consented to publication of her intraoperative photographs obtained during laparoscopy not allowing referring to patient's identity.

From September 2012 to October 2013, 4DryField® PH (Co. PlantTec Medical GmbH, Bad Bevensen, Germany) was applied in a total of 21 patients (23 - 44 years of age, mean age 34, 5 years).

Ten patients (36 - 65 years of age, mean age 48, 2 years) had surgery due to uterus pathology all associated with diffuse bleeding and leaving large peritoneal defects. Indication for surgery was large size Uterus myomatousus in 5, Adenomyosis uteri in 3, and malignant disease in 2 patients (1 endometrial carcinoma, 1 cervical carcinoma stage III). Surgery of the latter was systematic pelvic and para-aortic lymph-adenectomy combined with insertion of retrograde stents of both ureters.

In 4 of patients with uterus myomatousus the adnexa were resected and the uterus removed by morcellation. In consequence of severe adhesions repair of small and large intestine became necessary in one patient.

All patients were treated laparoscopically.

In all cases 4DryField® PH was applied for diffuse oozing mainly from blood and lymph capillaries from the vaginal stump or the area of lymph node resection.

The hemostatic effect of 4DryField® PH became evident by clot formation in all cases shortly after application of the powder. The use of further adjuncts was not necessary. Remaining white powder was dripped with saline solution to transform powder particles into a glassy gel to generate the adhesion prevention capability of 4DryField® PH as gel. Finally in all cases, Robinson drains were inserted.

The hemostatic efficiency of 4DryField® was judged by subjective assessment of the surgeon (MK). Patient records were evaluated for quantitative parameters of peripheral blood (hemoglobin, leucocytes, C-reactive protein), temperature, drain loss, stay of drains, and in-hospital stay of patients.

The patient with endometrial cancer had stage pT2, pN0, pL0, R0, G2. The intra-operative lavage revealed positive cytology. Postoperative chemotherapy regimen was planned with Carboplatin/Taxol. However, the patient refused this treatment. Characteristics of women with uterine pathology are summarized in [Table 1](#).

Ten patients (23 - 44 years of age, mean age 34, 5 years) had deep infiltrating endometriosis mostly combined

Table 1. Characteristics of patients with surgery for uterus pathology.

Age [yr]	Location of adhesions	Diagnosis	Surgery of uterus	Surgery of adnexa	Lymphnodes	Other	Bleeding
65*	right ileo-cecal after appendectomy	endometrium carcinoma pT2 pN0 pL0 V o R0 G2 positive peritoneal lavage cytology	total hysterectomy	bilateral adnexectomy	bilateral pelvic lymphadenectomy		diffuse bleeding
46	all lower abdominal and pelvic organs	cervical carcinoma III	radical hysterectomy	bilateral adnexectomy	bilateral pelvic and para-aortic lymphadenectomy	double-j-cath of both ureters	severest diffuse bleeding
34	all lower abdominal and pelvic organs	adenomyosis uteri squameous metaplasia of endocervix	radical hysterectomy	bilateral adnexectomy			severest diffuse bleeding
41	all lower abdominal and pelvic organs	uterus myomatosus adenomyosis uteri left endometrial cyst	total hysterectomy	left adenectomy		repair of small and large intestine, rectum	diffuse bleeding
50		uterus myomatosus	total hysterectomy				diffuse bleeding
39		severely enlarged uterus myomatosus	total hysterectomy (morcellator)				diffuse bleeding
50		severely enlarged uterus myomatosus	total hysterectomy (morcellator)				diffuse bleeding
45		adenomyosis uteri coagulation disorder	total hysterectomy				bleeding
51		severely enlarged uterus myomatosus	total hysterectomy (morcellator)				severe diffuse bleeding
57		severely enlarged uterus myomatosus	total hysterectomy (morcellator)				severe diffuse bleeding

*Patient with second look laparoscopy.

with abdominal adhesions, 1 patient (41 years of age) had severe adhesions following multiple previous surgeries. Leading symptom in all patients was significant pain in the lower abdomen. The patient with multiple previous surgeries suffered from pain and bowel obstruction.

Table 2 summarizes the intraoperative characteristics of endometriosis patients as well as surgical intervention on neighboring organs involved. 6 of 10 patients necessitated excision of large bowel and/or rectum endometriosis, 1 repair of small intestine. Three patients had involvement of ureter, in 2 the bladder had to be partially resected and/or repaired. As a sum, only patients with extensive disease were considered for treatment with 4DryField® PH. All patients were treated solely with laparoscopic surgery.

3. Second Look Laparoscopy

In 6 of the 21 patients a second laparoscopic surgery was performed. In 5 women with desire for pregnancy (23.5 - 36 years), a planned second look laparoscopy was performed to release the ovariopexy 8 weeks (7 to 9 weeks) post-operatively, which allowed judgment of abdominal adhesion formation. The patient with positive intra-operative lavage upon first surgery and refusal of chemotherapy developed free fluid in the abdomen and had second look surgery for tumor staging.

4. Results

In all patients intra-operatively the hemostatic effect after administration of 4DryField® PH was judged as

Table 2. Characteristics of endometrioses patients and surgical interventions on neighboring organs involved in the disease.

Age [yr]	Uterus	Adnexa	Vagina	Rectum	Ureter	Bladder	Other
42	myoma	left adnexectomy					
45		left ovarian cystectomy					resection of large right-side hydatide
33					left ureterolysis		
33	hysterectomy		suture after resection	suture after resection		suture after resection	suprapubic drain of urine
36			suture after resection	suture after resection		suture after resection	suprapubic drain of urine
24*		bilat. ovariopexy		revision of recto-sigmoidal junction	extensive left ureterolysis		
29*		bilat. ovarian cystectomy		suture of rectum and sigma after resection			appendectomy, suprapubic drain
28*	adenomyosis uteri		extensive lesion in pouch of Douglas affecting vagina and rectum				
36*				suture after resection	left ureterolysis		double-j-cath left ureter
28*			suture after resection				
41**							repair of small intestine

*Patients with second look laparoscopy; **Patient with sole adhesion disease.

to be evident. In cases with massive bleeding, the application of 4DryField® PH resulted in rapid sufficient hemostasis. There was no necessity for other hemostatic agents, or for conversion from laparoscopic to open surgery.

Postoperative transfusions were not necessary. Hemoglobin levels did not fall below 10 g/L. In three women the C-reactive protein level exceeded 10 mg/dL (normal value < 0.5 mg/dL), which was accompanied by mild leukocytosis in all three (10.5/nL, 13.1/nL, 16.1/nL) and elevated temperature (39.1°C) in one patient.

Overall postoperative loss from Robinson drains was 497 ± 339 mL (55 to 1365 mL). Drains were removed at day 4.3 ± 1.3 (3 to 8 days). Discharge from hospital was at day 6.2 ± 1.4 (4 to 9) days. Patients were free of pain without necessity of elevated medication for pain relief. There were no local infections. All wounds had healed per primam.

Six women underwent second look laparoscopy. Considering the extent of the initial disease upon first surgery the incidence of abdominal adhesion formation was 2 of 5 women being completely free of adhesions, 2 having few non-vascularized adhesions apart from the area of 4DryField® PH application. One patient had significant adhesions which, however, again were somewhat apart from the area application of 4DryField® PH powder. In this patient, the fossa ovarica treated with 4DryField® PH appeared to be free of adhesions.

The patient with endometrial cancer having had refused postoperative chemotherapy presented with free liquid in computed tomography at 1-year follow-up. Second look laparoscopy for tumor staging revealed the pelvic situs, *i.e.* area of hysterectomy and both iliac lymphadenectomies without local recurrence. However, ubiquitous there were white spots predominately at the diaphragm and anterior abdominal wall disclosing to be peritoneal metastases of adenocarcinoma. There was no adhesion formation neither in the pouch of Douglas nor in the areas of extensive lymph node resection.

Figure 1 demonstrates the technique of application of 4DryField® PH on a slightly bleeding peritoneal defect. After complete hemostasis has been achieved powder is transformed into gel by gentle dripping with saline solution. **Figure 2** shows the result after 8 weeks with the areas of former peritoneal defects being free of adhesion pathology.

5. Discussion

Post-operative hemorrhage, besides infection, is still the second most early complication following gynecologi-

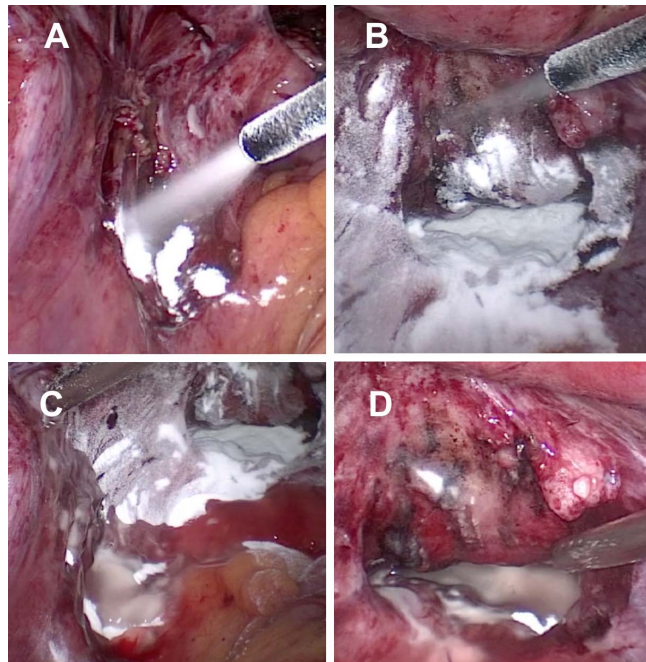


Figure 1. Application of 4DryField® PH powder to the area of left ovarian fossa (A); and pouch of Douglas (B); 4DryField® PH powder in left ovarian fossa (C); and pouch of Douglas (D) is transformed into gel.

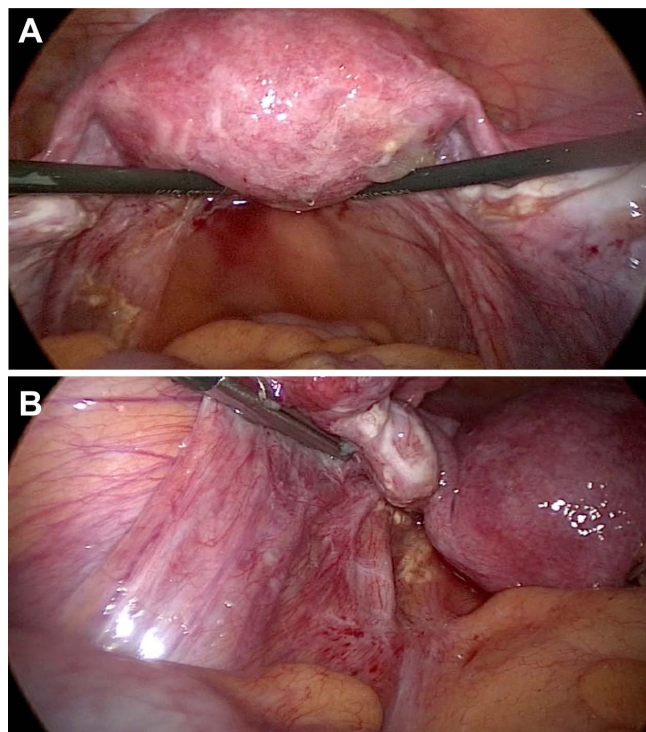


Figure 2. Laparoscopic photographs of the pouch of Douglas (A) and fossa ovarica (B) during second-look laparoscopy 8 weeks after 4DryField® PH application. (A) Pouch of Douglas is completely healed and free of adhesions; (B) Fossa ovarica is completely healed and free of adhesions.

cal surgery [3] [4]. This also accounts for the laparoscopic approach [4] [12]. Hematoma, prolonged lymphatic oozing, combined with prolonged necessity of drainage contributes to the incidence of infections, especially in obese patients. The hemostatic effect of 4DryField[®] PH could be observed during surgery by means of visible clot formation and ceasing of bleeding. This was especially impressive in one patient with resection of multifocal endometriosis. Overall, considering that in this study 4DryField[®] PH was only applied in patients with extensive surgical procedures, the rate of post-operative drain loss indicates that there is a substantial styptic effect on blood and also on lymph capillaries. Furthermore, there was no necessity for use of another hemostat or to switch from laparoscopic to open access. Remarkably, elevated C-reactive protein levels were not always accompanied by leukocytosis or fever, and might be due to degradation activities as it is in polysaccharide absorption.

The rate of adhesion formation after extensive surgery in pathologies comparable to our patients can be projected to be up to 90% [6] [7] and their consequences respectively possible complications are substantial [13]. With the individual risk of patients—*i.e.* pain, infertility, obstruction of intestinal passage to ileus—being always in the foreground, recently the economic aspects have been discussed by Ray *et al.* [14] for the US, and Tingstedt *et al.* for Sweden [15]. Introduction of laparoscopy did somewhat diminish the incidence of adhesion formation but not substantially eliminate the problems and costs [13]. Gynecologic surgery plays an important role in readmission rate [16]. Gynecologists and increasingly individual patients and patient organizations put more and more attention on abdominal adhesions and their consequences.

In women who are in child bearing age and who have the wish for children gynecological surgery faces the dilemma that the surgical trauma might induce adhesions—the most frequent cause for secondary female infertility [17]. Thus, the second look laparoscopies in the present study deserve special consideration. Present data are promising but however, need to be confirmed by multicenter studies.

The capability of 4DryField[®] PH to be functional as hemostat and adhesion prevention agent is very attractive since two major complications of gynecological surgery are focused on. The excellent outcome with only few adhesions upon second look laparoscopy stresses the dual potential of 4DryField[®] PH. Considering the efficiency in adhesion prevention 4DryField[®] PH could be helpful also for other abdominal or urological surgeries surgery involving the peritoneum and bearing the risk of adhesion formation.

6. Conclusion

4DryField[®] PH with its twofold effect in hemostasis and adhesion prevention is a promising contribution to the operative treatment of endometriosis, adhesions, and extensive uterus disease. The preliminary results in patients with extensive pathologies support its use in operative gynecology, and furthermore, also for other surgeries with peritoneal trauma. Prospective randomized studies are necessary to prove these promising results in larger series.

References

- [1] Chelmow, D., Aronson, M.P., Wosu, U., DeCherney, A.H., Goodwin, T.M. and Laufer, N. (2007) Intraoperative and Postoperative Complications of Gynecologic Surgery. Current Diagnosis & Treatment: Obstetrics & Gynecology. 10th Edition, McGraw-Hill Medical, New York.
- [2] Makinen, J. (2001) Morbidity of 10 110 Hysterectomies by Type of Approach. *Human Reproduction*, **16**, 1473-1478. <http://dx.doi.org/10.1093/humrep/16.7.1473>
- [3] Makinen, J., Brummer, T., Jalkanen, J., *et al.* (2013) Ten Years of Progress-Improved Hysterectomy Outcomes in Finland 1996-2006: A Longitudinal Observation Study. *BMJ Open*, **3**, Article ID: e003169. <http://dx.doi.org/10.1136/bmjopen-2013-003169>
- [4] Stang, A., Merrill, R.M. and Kuss, O. (2011) Nationwide Rates of Conversion from Laparoscopic or Vaginal Hysterectomy to Open Abdominal Hysterectomy in Germany. *European Journal of Epidemiology*, **26**, 125-133. <http://dx.doi.org/10.1007/s10654-010-9543-4>
- [5] Hirschelmann, A., Tchartchian, G., Wallwiener, M., Hackethal, A. and de Wilde, R.L. (2012) A Review of the Problematic Adhesion Prophylaxis in Gynaecological Surgery. *Archives of Gynecology and Obstetrics*, **285**, 1089-1097. <http://dx.doi.org/10.1007/s00404-011-2097-1>
- [6] de Wilde, R.L., Bakkum, E.A., Brölmann, H., *et al.* (2014) Consensus Recommendations on Adhesions (Version 2014) for the ESGE Adhesions Research Working Group (European Society for Gynecological Endoscopy): An Expert Opinion. *Archives of Gynecology and Obstetrics*, **290**, 581-582. <http://dx.doi.org/10.1007/s00404-014-3312-7>

- [7] Menzies, D. and Ellis, H. (1990) Intestinal Obstruction from Adhesions—How Big Is the Problem? *Annals of the Royal College of Surgeons of England*, **72**, 60-63.
- [8] Di Zerega, G.S. (2000) Peritoneum, Peritoneal Healing, and Adhesion Formation. In: Di Zerega, G.S., Ed., *Peritoneal Surgery*, Springer New York, New York, 3-37. http://dx.doi.org/10.1007/978-1-4612-1194-5_1
- [9] Di Zerega, G.S., Roth, R. and Johns, D.B. (2003) Quantitation of Peritoneal Adhesions and Correlation with Clinical Outcomes. *Infertility and Reproductive Medicine Clinics of North America*, **14**, 431-456.
- [10] Hanke, A.A., Flöricke, F., Sieg, L., Johanning, K. and Rahe-Meyer, N. (2011) Effects of a New Microporous Polysaccharide Powder on Viscoelastic Characteristics of Clot Formation. American Society of Anesthesiologists Annual Meeting 2011. *Anesthesiology*.
- [11] Poehnert, D., Abbas, M., Kreipe, H., Klempnauer, J. and Winny, M. (2014) Marked Reduction of Peritoneal Adhesion Formation in Rat Model of Cecal Abrasion by a Novel Anti-Adhesive Agent, 4DryField® PH: 131st Congress of the German Society for Surgery. *Langenbeck's Archives of Surgery*, **399**, 371-413.
- [12] Donnez, J., Squifflet, J. and Donnez, O. (2009) Have the Safety Concerns about Laparoscopic Hysterectomy Been Fully Addressed? *BJOG: An International Journal of Obstetrics & Gynaecology*, **116**, 1272-1273. <http://dx.doi.org/10.1111/j.1471-0528.2009.02253.x>
- [13] Kavic, S.M. and Kavic, S.M. (2002) Adhesions and Adhesiolysis: The Role of Laparoscopy. *JSLs Journal of the Society of Laparoendoscopic Surgeons/Society of Laparoendoscopic Surgeons*, **6**, 99-109.
- [14] Ray, N. (1998) Abdominal Adhesiolysis: Inpatient Care and Expenditures in the United States in 1994. *Journal of the American College of Surgeons*, **186**, 1-9. [http://dx.doi.org/10.1016/S1072-7515\(97\)00127-0](http://dx.doi.org/10.1016/S1072-7515(97)00127-0)
- [15] Tingstedt, B., Isaksson, J. and Andersson, R. (2007) Long-Term Follow-Up and Cost Analysis Following Surgery for Small Bowel Obstruction Caused by Intra-Abdominal Adhesions. *British Journal of Surgery*, **94**, 743-748. <http://dx.doi.org/10.1002/bjs.5634>
- [16] Lower, A.M., Hawthorn, R.J.S., Clark, D., et al. (2004) Adhesion-Related Readmissions Following Gynaecological Laparoscopy or Laparotomy in Scotland: An Epidemiological Study of 24,046 Patients. *Human Reproduction (Oxford, England)*, **19**, 1877-1885. <http://dx.doi.org/10.1093/humrep/deh321>
- [17] ten Broek, R.P.G., Issa, Y., van Santbrink, E.J.P., et al. (2013) Burden of Adhesions in Abdominal and Pelvic Surgery: Systematic Review and Met-Analysis. *BMJ*, **347**, f5588. <http://dx.doi.org/10.1136/bmj.f5588>