

Major physical but also psychological effects after pain relief from surgical scraping in patients with Achilles tendinopathy—A 1-year follow-up study

Anna Ruergård, Håkan Alfredson*

Department of Surgical and Perioperative Science Sports Medicine, University of Umeå, Umeå, Sweden;

*Corresponding Author: hakan.alfredsson@idrott.umea.se

Received 19 November 2013; revised 26 December 2013; accepted 17 January 2014

Copyright © 2014 Anna Ruergård, Håkan Alfredson. This is an open access article distributed under the Creative Commons Attribution License, which permits unrestricted use, distribution, and reproduction in any medium, provided the original work is properly cited. In accordance of the Creative Commons Attribution License all Copyrights © 2014 are reserved for SCIRP and the owner of the intellectual property Anna Ruergård, Håkan Alfredson. All Copyright © 2014 are guarded by law and by SCIRP as a guardian.

ABSTRACT

Treatment with Ultrasound (US) and Color Doppler (CD)-guided surgical scraping has shown good short-term clinical results in patients with chronic painful midportion Achilles tendinopathy. The objective was to prospectively follow the patients 1-year after surgery. Material: Sixty-four tendons in 47 patients (28 men and 19 women, mean age 52 (+/-12 years) on different activity levels) were in local anaesthesia operated with US+CD-guided surgical scraping. In 43/64 tendons, there was also removal of the plantaris tendon. Methods: Questionnaires evaluating activity level, VAS for pain during activity, satisfaction with treatment result, and the SF-36 score (quality of life), were used before and 1-year after surgery. Results: At follow-up, the mean VAS for pain during activity had decreased from 62 (+/-20) before surgery to 15 (+/-15) after surgery ($p < 0.001$). All patients were satisfied with the result and had returned to full tendon loading activity. There were no complications. Both the physical and psychological parameters in the SF-36 score had improved significantly. Conclusions: For patients with chronic painful midportion Achilles tendinopathy, US+CD-guided surgical scraping, often combined with plantaris tendon removal, seems to be an efficient treatment method to recover physically and psychologically.

KEYWORDS

Achilles; Tendinopathy; Midportion; Surgical Scraping

1. INTRODUCTION

The Achilles tendon is the strongest and thickest tendon in the human body [1], but not/seldom exposed to injury. Achilles tendinopathy is a disorder that has been shown to be relatively common among runners [2-8]. There is often a chronicity, and the pain is mostly located in the mid-portion of the Achilles tendon (55% - 60%) [8, 9]. The aetiology is unknown, but has been suggested to be associated with overuse [4,6,7]. Running surface and increased running distance have been proposed as causative factors [4,7]. However, non-active individuals also suffer from midportion tendinopathy [10,11,12], and high blood lipids have been shown to be relatively common among these patients [12]. Men and women have been found to be equally affected by Midportion Achilles tendinopathy [13].

Neovascularisation/regions with high blood flow have been found in patients with painful Achilles tendinopathy, but not in normal tendons, therefore these regions have been discussed to play a role in pain [14,15]. Also, biopsies from the regions with Ultrasound (US) and Color Doppler (CD) verified neovascularisation/high blood flow have shown nerves in close relation to blood vessels outside, but not inside, the tendons [16].

Treatment has been known to be difficult, but new methods like painful eccentric calf muscle training [17-20] and US + CD-guided sclerosing polidocanol injection treatment [21-23] targeting the regions with neovessels/high blood flow outside the tendon, has been shown to be successful in a high proportion of the patients. Recently, US + CD-guided surgical scraping, targeting the regions with neovessels/high blood flow outside the tendon, was demonstrated to give very good clinical results, with a quick return to high loading Achilles tendon activities [24].

Originating from the popliteal surface of the femur, the thin rudimentary plantaris muscle is found [25], and its normally thin tendon has been shown to not seldom be dramatically thickened and located in close relation to the medial side of the Achilles midportion in patients with Achilles tendinopathy [26,27]. Therefore, the plantaris tendon is thought to be involved in midportion tendinopathy [24,26,28,29], possibly causing mechanical interference. Promising clinical results has been seen after surgical treatment combining the US+CD-guided scraping with removal of the plantaris tendon [24,26].

The aim with this 1-year prospective study was to evaluate tendon pain during activity, patients satisfaction with the treatment result, and quality of life one year after treatment with US and CD-guided surgery in patients with mid-portion Achilles tendinopathy.

2. MATERIALS AND METHODS

2.1. Participants

Ethics approval was obtained from the regional ethical board for medical research at the Umeå University, Sweden. Informed consent was obtained from all patients included in this study.

Sixty-four tendons in 47 consecutive Swedish patients (28 men and 19 women, mean age 52 +/- 12 years) were included. The patients activity levels differed from non-actives (n = 6), recreational athletes (n = 36), elite recreational athletes (n = 4) to elite level athlete (n = 1). Inclusion criteria were: patients with a long (>3 months) duration of Achilles tendon pain, eccentric training without effect or inability to perform eccentric training because of back, hip, knee or ankle problems.

Duration of symptoms varied from three to 36 months with an average of 11 months.

2.2. Clinical Examination

Clinical examination demonstrated a nodular thickening in the Achilles midportion, with tenderness located at the ventral and sometimes also medial side of the thickening.

All patients were examined with high resolution grey scale-ultrasound (US) and Color Doppler (CD) (Acuson Segovia, Siemens), using a linear multifrequency (8 - 13 MHz) probe. CD was used to diagnose regions with high blood flow, and to locate where the blood flow entered the tendon. Both Achilles tendons were examined. In all painful tendons US + CD examination showed a thickened Achilles midportion, with irregular tendon structure and locally high blood flow outside and inside the regions with structural tendon changes.

2.3. Surgery

Ultrasound and Doppler-guided surgical scraping +

extirpation of the plantaris tendon.

After washing, a 5 - 10 ml of a local anaesthetic (Xylocain + Adrenaline, 5 mg/ml) was injected on the medial and ventral side of the Achilles midportion. The skin was then draped with a sterile paper-cover, exposing only the midportion of the Achilles tendon.

A longitudinal skin incision (1 - 2 cm) was placed on the medial side of the Achilles midportion, and the tendon was carefully identified. If a plantaris tendon was found invaginated into the medial Achilles, or located close by the medial or ventro-medial side, it was followed and released distally and proximally, cut in both ends, and extirpated. There was often a richly vascularized fat tissue inter-positioned between the Achilles and the plantaris tendon. After removing the plantaris tendon, the traditional scraping procedure was performed [24]. In the regions with ultrasound and Doppler verified changes and high blood flow the tendon was completely released from the ventral soft tissue, by sharp dissection with a knife, staying close to the ventral tendon. This was followed by hemostasis, using diathermia. The skin was closed by single non-resorbable sutures.

2.4. Postoperative Rehabilitation

Day 1 (Surgery day): Rest, elevated foot.

Day 2: ROM (Range of movement), light stretching, and short walks.

Day 3 - 7: Gradually increased walking activity.

Day 8 - 14: Light bicycling.

After 2 weeks: Sutures out, gradually increased load up to free activity.

2.5. Outcome Measures

A visual analogue scale (VAS) was used to evaluate the amount of tendon pain during the patients individual tendon loading activity (walking, recreational sport or high level sport etc.). This is a 100 mm self-reporting scale where no pain is recorded as 0 and worst pain 100.

The 100 mm scale was also used to evaluate patients satisfaction with the treatment result. Not satisfied at all was recorded as 0 and full satisfaction was recorded as 100.

For evaluation of the patients quality of life, the Swedish version of the SF-36 (The Short Form 36 Health Survey) was used. This questionnaire is divided into eight sections with altogether 36 questions. The eight sections consists of PF = Physical Functioning, RP = Role-Physical, BP = Bodily Pain, GH = General Health, VT = Vitality, SF = Social Functioning, RE = Role-Emotional and MH = Mental Health, showing different aspects in the patients quality of life. The results are then calculated and range from a scale of 0 - 100, where 100 is representing the peak of life quality, in each section.

VAS for pain during activity and the SF-36 questionnaire were used before surgical treatment and at the 1-year follow-up.

2.6. Statistical Methods

SPSS (Statistical Package of Social Science) that has been shown to be useful and reliable was used to analyze the data (SPSS Inc., Chicago, Illinois, USA). All calculations were measured on group level. Paired students T-test was selected to identify differences before and one year after surgery. Level of significance was set to $p < 0.05$.

3. RESULTS

There were no complications related to the surgical treatment.

3.1. Tendon Pain during Achilles Tendon-Loading Activity

At the 1 year follow-up, there was a significant ($p < 0.001$) decrease in the mean VAS for tendon pain during activity, from 62 (± 20) before surgery to 15 (± 15) after surgery (Figure 1).

3.2. Satisfaction with Treatment Result

All patients were back in their habitual Achilles tendon loading activities. The mean satisfaction with the result of the treatment was 88% (ranging from 33% to 100%)

3.3. Quality of Life One Year after Surgery

The results from the SF-36 questionnaire showed that especially the physical health was significantly improved one year after surgery. Parameters: Physical functioning-PF: from 71 (± 20) before to 85 (± 20) after ($p < 0.001$), Role Physical-RP: from 46 (± 42) before to 81

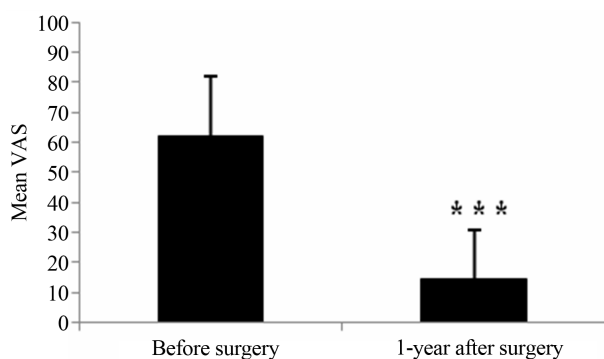


Figure 1. Pain during Achilles tendon-loading activity. Visual Analogue Scale (VAS) for tendon pain during tendon loading activity, before and 1-year after surgery. *** = $p < 0.001$.

(± 33) after ($p < 0.001$), Bodily Pain-BP: from 48 (± 14) before to 71 (± 23) after ($p < 0.001$), General health- GH from 78 (± 17) before to 74 (± 21) after ($p > 0.05$), Vitality-VT: from 61 (± 19) before to 64 (± 22) after ($p > 0.05$), Social Functioning-SF: from 85 (± 19) before to 89 (± 20) after ($p > 0.05$), Role Emotion-RE: from 73 (± 40) before to 91 (± 26) after ($p < 0.05$), and Mental health-MH: from 81 (± 15) before to 82 (± 16) after ($p > 0.05$) (Figure 2).

4. DISCUSSION

This 1-year follow-up study of patients with midportion Achilles tendinopathy, operated with the US + CD-guided mini surgical scraping procedure [24,26], showed very good clinical results with a major reduction of the pain levels in satisfied patients back in full Achilles tendon loading activities. Interestingly, the treatment had positive effects not only physically, but also psychologically. To the best of our knowledge, this is the first study investigating quality of life pre- and postoperatively in patients with this diagnosis. We use the Swedish version of the SF-36 (The Short Form 36 Health Survey) questionnaire that shows different aspects of the individuals' quality of life, and has been proved to be a reliable method [30]. The sections with most significant improvement after surgery in our study were related to physical function, showing that the patients were able to enjoy physical activities without limitations and experienced less pain in their daily life. The psychological parameter Role Emotion-RE also improved significantly after surgery, showing that emotional problems interfered less with daily activities or work after, compared to before treatment. It is interesting to notice that patients suffering from chronic painful midportion Achilles tendinopathy suffer not only physically, but also psychologically. This has, to the best of our knowledge, never been demon-

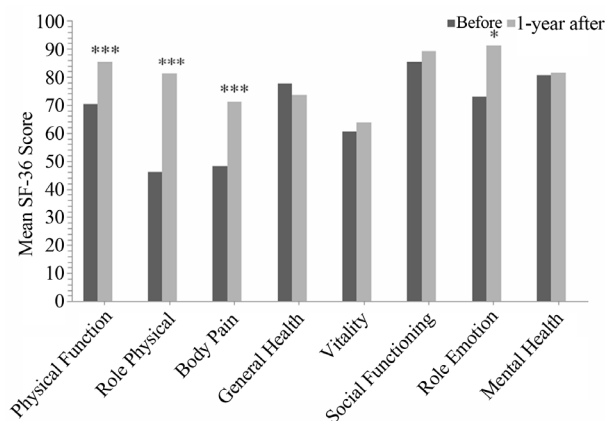


Figure 2. SF- 36 Score. Before surgery and 1-year after surgery. * = $p < 0.05$, ** = $p < 0.01$, *** = $p < 0.001$.

strated before, and indicates that it might be important to try to cure these patients as soon as possible before the emotional problems interferes to much with daily life activities.

The mini surgical scraping procedure has in a previous study been shown to be a successful treatment method [24], but the results in this study, with all patients being satisfied are unexpectedly good. However, looking at the scores, it is important to notice that there is a wide range (from 33% satisfied to 100% satisfied) in how satisfied the patients are with the treatment result.

There are many advantages with this US+CD-guided mini surgical procedure performed outside the tendon. The operation is performed under local anesthesia, minimizing risks related to general or spinal anaesthesia. The patients start walking the first day after the operation, and only very few patients, having very heavy Achilles tendon loading occupations, need to be on sick-leave for a couple of weeks. Most patients are back in full Achilles tendon loading sports within 4 - 6 weeks after the operation. There are very few complications related to this treatment method, but awareness of proper wound care is essential.

To be able to reliably find the target for the surgical scraping, US- and CD-guidance is needed. Combining these two techniques makes it possible to minimize the skin incision, and the tissue trauma during the scraping procedure. This is, however, also complicating, because US and CD equipment, and education how to use it and interpret the findings, are needed. This might, initially, limit the use of this treatment method, but in the longer perspective we hope and believe, that US- and CD-guided procedures will be more used. Altogether, the benefits achieved motivate further, and most likely increased, use of this treatment method.

In 2/3 (43/64) of the patients in the current study there was also involvement of a nearby located plantaris tendon. From a cadaver study, it is known that the plantaris tendon was most often located about 1 cm away from the medial side of the Achilles, but in about 10% of the specimens, the plantaris was located very close to and sometimes even inserting into the Achilles [25]. In a previous study on patients with midportion Achilles tendinopathy, undergoing the scraping procedure, it was demonstrated that in a high proportion of the patients the plantaris tendon was found to be thickened, located close to, and possibly interfering, with the medial side of the Achilles tendon [26]. The findings in that study led to a routinely removal of the plantaris in cases where it was found to be located close to the medial Achilles. Histological examination of the excised thickened plantaris tendons showed similar tendinosis changes as been demonstrated for the Achilles tendinopathy tendons [26].

Comparing the surgical scraping method, with by us the previously often used sclerosing polidocanol injection treatment, the major advantage with surgery is that only one treatment is needed, compared to multiple injection treatments (2 - 3 injections with 8 weeks in between). Consequently, the surgical scraping method saves time, and economically it is also cheaper than 3 injection treatments.

A weakness with this study is that it is only a 1-year follow-up. The results could maybe fade over time, but on the other hand previous research on this surgical method shows that the failures tend to show up within the first six months [24,26]. Another weakness is the use of only a questionnaire follow-up. It would have been ideal to also perform a clinical and ultrasound follow-up, but it is unfortunately not possible due to logistical reasons. For further studies, we believe that long term follow-ups, including ultrasound and Doppler examination are of importance. There are indications that the tendon thickness and structure improve over time in patients being pain-free after this type of surgical treatment, and this remodeling would be interesting to study closer.

The results from the VAS and SF-36 scores show that there are major individual variations, but based on our experiences from having done multiple scientific studies on similar patient materials, we strongly believe that the scores are representative for patients with chronic painful midportion Achilles tendinopathy.

In conclusion, this study shows that US + CD-guided surgical scraping, often combined with plantaris tendon removal, has beneficial effects both physically and psychologically for patients with chronic painful midportion Achilles tendinopathy. This study showed a very high 1-year success rate with this treatment method.

ACKNOWLEDGEMENTS

We would like to thank Dr Peter Larsson for valuable help with the statistical analyses.

REFERENCES

- [1] Doral, M.N., Alam, M., Bozkurt, M., Turhan, E., Atay, O.A., Dönmez, G. and Maffulli, N. (2010) Functional anatomy of the Achilles tendon. *KSSSTA*, **18**, 638-643.
- [2] Cosca, D.D. and Navazio, F. (2007) Common problems in endurance athletes. *American Academy of Family Physicians*, **76**, 237-244.
- [3] Galloway, M.T., Joki, P. and Dayton, O.W. (1992) Achilles tendon overuse injuries. *Clinical Sports Medicine*, **11**, 771-782.
- [4] Knobloch, K., Yoon, U. and Vogt, P.M. (2008) Acute and overuse injuries correlated to hours of training in master running athletes. *Foot and Ankle*, **29**, 671-676. <http://dx.doi.org/10.3113/FAI.2008.0671>

- [5] Kvist, M. (1994) Achilles tendon injuries in athletes. *Sports Medicine*, **18**, 173-201. <http://dx.doi.org/10.2165/00007256-199418030-00004>
- [6] Paavola, M. and Järvinen, T.A. (2005) Paratendinopathy. *Foot and Ankle Clinics*, **10**, 279-292. <http://dx.doi.org/10.1016/j.fcl.2005.01.008>
- [7] Schepsis, A.A., Jones, H. and Haas A.L. (2002) Achilles tendon disorders in athletes. *American Journal of Sports Medicine*, **30**, 287-305.
- [8] Öhberg, L., Lorentzon, R. and Alfredson, H. (2004) Eccentric training in patients with chronic Achilles tendinosis: Normalised tendon structure and decreased thickness at follow up. *BJSM*, **38**, 8-11. <http://dx.doi.org/10.1136/bjism.2001.000284>
- [9] Jarvinen, T.A.H., Kannus, P., Paavola, M., Jarvinen, T.L.N., Jozsa, L. and Jarvinen, M. (2001) Achilles tendon injuries. *Current Opinion in Rheumatology*, **13**, 150-155. <http://dx.doi.org/10.1097/00002281-200103000-00009>
- [10] Rolf, C. and Movin, T. (1997) Etiology, histopathology, and outcome of surgery in achillodynia. *Foot & Ankle International*, **18**, 565-569. <http://dx.doi.org/10.1177/107110079701800906>
- [11] Åström, M. (1998) Partial rupture in chronic Achilles tendinopathy: A retrospective analysis of 342 cases. *Acta Orthopaedica Scandinavica*, **69**, 404-407. <http://dx.doi.org/10.3109/17453679808999056>
- [12] Gaida, J.E., Alfredson, L., Kiss, Z.S., Wilson, A.M., Alfredson, H. and Cook, J.L. (2009) Dyslipidemia in Achilles tendinopathy is characteristic of insuline resistance. *Medicine & Science in Sports & Exercise*, **41**, 1194-1197. <http://dx.doi.org/10.1249/MSS.0b013e31819794c3>
- [13] De Jonge, S., Van den Berg, C., De Vos, R.J., Van der Heide, H.J., Weir, A., Verhaar, J.A., Bierma-Zeinstra, S.M. and Tol, J.L. (2011) Incidence of midportion Achilles tendinopathy in the general population. *BJSM*, **45**, 1026-1028. <http://dx.doi.org/10.1136/bjsports-2011-090342>
- [14] Alfredson, H., Öhberg, L. and Forsgren, S. (2003) Is vasculo-neural ingrowth the cause of pain in chronic Achilles tendinosis? An investigation using ultrasonography and colour Doppler, immunohistochemistry, and diagnostic injections. *KSSSTA*, **11**, 334-338.
- [15] Öhberg, L., Lorentzon, R. and Alfredson, H. (2001) Neovascularisation in Achilles tendons with painful tendinosis but not in normal tendons: An ultrasonographic investigation. *KSSSTA*, **9**, 233-238.
- [16] Andersson, G., Danielson, P., Alfredson, H. and Forsgren, S. (2007) Nerve-related characteristics of ventral paratendinous tissue in chronic Achilles tendinosis. *KSSSTA*, **15**, 1272-1279.
- [17] Alfredson, H., Pietilä, T. and Lorentzon, R. (1998) Heavy-load eccentric calf muscle training for the treatment of chronic Achilles tendinosis. *American Journal of Sports Medicine*, **26**, 360-366.
- [18] Fahström, M., Jonsson, P., Lorenzon, R. and Alfredson, H. (2003) Chronic Achilles tendon pain treated with eccentric calf-muscle training. *KSSSTA*, **11**, 327-333.
- [19] Murtaugh, B. and Ihm, J. (2013) Eccentric training for the treatment of tendinopathies. *Current Sports Medicine Reports*, **12**, 175-182. <http://dx.doi.org/10.1249/JSR.0b013e3182933761>
- [20] Roos, E.M., Engström, M., Lagerquist, A. and Söderberg, B. (2004) Clinical improvement after 6 weeks of eccentric exercise in patients with mid-portion Achilles tendinopathy—A randomized trial with 1-year follow up. *Scandinavian Journal of Medicine & Science in Sports*, **14**, 286-295. <http://dx.doi.org/10.1111/j.1600-0838.2004.378.x>
- [21] Alfredson, H., Öhberg, L., Zeisig, E. and Lorentzon, R. (2007) Treatment of midportion Achilles tendinosis: Similar clinical results with US and CD-guided surgery outside the tendon and sclerosing polidocanol injections. *KSSSTA*, **15**, 1504-1509.
- [22] Lind, B., Öhberg, L. and Alfredson, H. (2006) Sclerosing polidocanol injections in mid-portion Achilles tendinosis: Remaining good clinical results and decreased tendon thickness at 2-year follow-up. *KSSSTA*, **14**, 1327-1232.
- [23] Öhberg, L. and Alfredson, H. (2002) Ultrasound guided sclerosis of neovessels in painful chronic Achilles tendinosis: Pilot study of a new treatment. *BJSM*, **36**, 173-177. <http://dx.doi.org/10.1136/bjism.36.3.173>
- [24] Alfredson, H. (2011) Ultrasound and Doppler-guided mini-surgery to treat midportion Achilles tendinosis: Results of a large material and a randomised study comparing two scraping techniques. *BJSM*, **45**, 407-410. <http://dx.doi.org/10.1136/bjism.2010.081216>
- [25] van Stekenburg, M.N., Kerkhoffs, G.M., Kleipool, R.P. and Niek van Dijk, C. (2011) The plantaris tendon and a potential role in mid-portion Achilles tendinopathy: An observational anatomical study. *Journal of Anatomy*, **218**, 336-341. <http://dx.doi.org/10.1111/j.1469-7580.2011.01335.x>
- [26] Alfredson, H. (2011) Midportion Achilles tendinosis and the plantaris tendon. *BJSM*, **45**, 1023-1025. <http://dx.doi.org/10.1136/bjsports-2011-090217>
- [27] Spang, C., Alfredson, H., Ferguson, M., Roos, B., Bagge, J. and Forsgren, S. (2013) The plantaris tendon in association with mid-portion Achilles tendinosis—Tendinosis-like morphological features and presence of a non-neuronal cholinergic system. *Histology and Histopathology*, **28**, 623-632.
- [28] Lintz, F., Higgs, A., Milett, M., Barton, T., Raghuvanshi, M., Adams, M.A. and Winson, I.G. (2011) The role of Plantaris Longus in Achilles tendinopathy: A biomechanical study. *Foot and Ankle Surgery*, **17**, 252-255. <http://dx.doi.org/10.1016/j.fas.2010.08.004>
- [29] van Stekenburg, M.N., Kerkhoffs, G.M. and van Dijk, C.N. (2011) Good outcome after stripping the plantaris tendon in patients with chronic mid-portion Achilles tendinopathy. *KSSSTA*, **19**, 1362-1366.
- [30] Sullivan, M., Karlsson, J. and Ware, J.E. (1995) The Swedish SF-36 health survey. 1. Evaluation of data quality, scaling assumptions, reliability and construct-validity across general populations in Sweden. *Social Science & Medicine*, **41**, 1349-1358. [http://dx.doi.org/10.1016/0277-9536\(95\)00125-Q](http://dx.doi.org/10.1016/0277-9536(95)00125-Q)