

A Novel Technique for Removal of Urogenital Magnetic Foreign Bodies

Kenneth R. Hassler^{1*}, Kaveh Homayoon²

¹Department of Surgery, Maricopa Integrated Health System, Phoenix, USA

²Department of Surgery—Urology Division, Maricopa Integrated Health System, Phoenix, USA

Email: *Kenneth.Hassler2@mihs.org

How to cite this paper: Hassler, K.R. and Homayoon, K. (2018) A Novel Technique for Removal of Urogenital Magnetic Foreign Bodies. *Open Journal of Urology*, 8, 223-227.

<https://doi.org/10.4236/oju.2018.88025>

Received: July 3, 2018

Accepted: August 7, 2018

Published: August 10, 2018

Copyright © 2018 by authors and Scientific Research Publishing Inc.

This work is licensed under the Creative Commons Attribution International License (CC BY 4.0).

<http://creativecommons.org/licenses/by/4.0/>



Open Access

Abstract

Background: There were 800 individual case reports of urogenital foreign bodies in the English literature from 1755 to 1999. The use of urogenital foreign bodies for sexual pleasure is a common occurrence in today's population. The aim of this discussion is the management of scrotal injury caused by magnetic urogenital foreign bodies. **Case Presentation:** 56-year-old male with scrotal tissue entrapped between two opposed magnet rings. Self-reported attempts at removal were unsuccessful and caused for presentation to the emergency department. Additional attempts at removal by medical staff unsuccessful in emergency department and therefore the patient proceeded to the operating room. Intraoperatively the use of two cardiac magnets allowed for removal without a need for invasive surgical procedure. **Conclusion:** Cardiac magnets are preferred means of removal for entrapped skin between magnetic foreign bodies that could be utilized at the bedside.

Keywords

Urogenital, Foreign Body, Magnet, Magnetic, Scrotal, Scrotum, Urogenital Magnetic Foreign Body, Scrotal Magnets, Magnetic Foreign Body, Urogenital Magnet Removal, Scrotal Magnet Removal

1. Introduction

The use of foreign bodies, for erotic/sexual pleasure in the adult population, is not uncommon. The foreign objects used for sexual pleasure come invariable shapes and sizes, and are utilized in different ways. In one study, there were 800 individual case reports of urogenital foreign bodies in the English literature from 1755 to 1999 [1]. Use of magnets for sexual enhancement presents unique situa-

tion urogenital injuries as pressure necrosis of underlying skin may create a need for urgent intervention. Magnetic foreign bodies have been well described in the literature, specifically in the pediatric literature with ingestion and subsequent complications [2] [3] [4] [5]. There are very few similar reports regarding magnetic urogenital foreign bodies. This case report highlights a novel technique for removal of magnetic urogenital foreign bodies without the need for invasive surgical procedures as previously described in other case reports [6] [7] [8].

2. Case Report

56-year-old male presented to emergency department with persistent scrotal pain. Reportedly the patient was utilizing magnets to resolve abdominal pain. He had placed the magnets on either side of his scrotum at the base of penis and kept them in place with the scrotal tissue at the base of penis pinched by the opposing magnet rings. He kept the rings in place for an unknown time. He attempted to remove the rings manually or by using pliers to remedy his scrotal pain at home but was unsuccessful. He did not have any hematuria, dysuria, or obstructive voiding issues. His physical exam was unremarkable except for two small circular magnets adhered to bilateral aspect of his proximal scrotum, bilateral testicles palpable with no obvious abnormality (**Figure 1**). Ultrasound imaging of the scrotum showed no acute ischemic process. Attempts at removal, manual removal with physician's hands, pliers, and addition of lubrication, at the bedside in the emergency department were not fruitful. Therefore, the patient was taken to the operating room.

3. Operative Course

In the operating room after induction of anesthesia, Magnets were unable to be

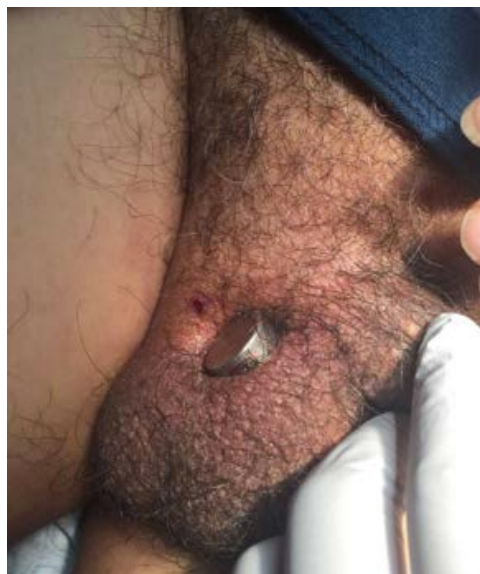


Figure 1. Magnetic foreign bodies on both sides of the scrotum at the base of the penis.

removed by simple manual sliding, pulling, or prying them apart. Two cardiac magnets, commonly used to demagnetized pacemakers or defibrillators, were then attached to magnets bilaterally on the scrotum (**Figure 2**). Once the cardiac magnets were attached, the magnet complex was then slid in opposite directions with ease and the magnets were removed from the patient's scrotum. There was underlying soft tissue pressure necrosis, however not full thickness (**Figure 3**). He was subsequently discharged home with bacitracin to bilateral wounds.

4. Follow Up

Patient returned 2 weeks later, had no new complaints and no pain or swelling of the scrotum. Scrotum had small dime-sized circular inflamed scar with darkened crust in middle with pale pink raised border and with no surrounding edema or erythema (**Figure 4**).

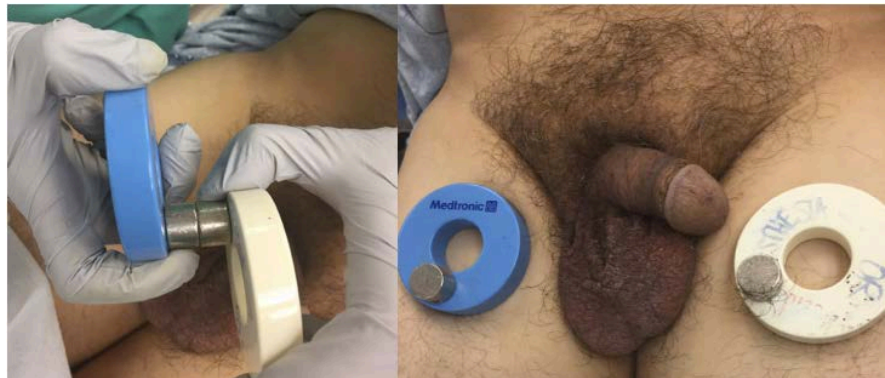

Figure 2. Magnet complex with cardiac magnets after removal.

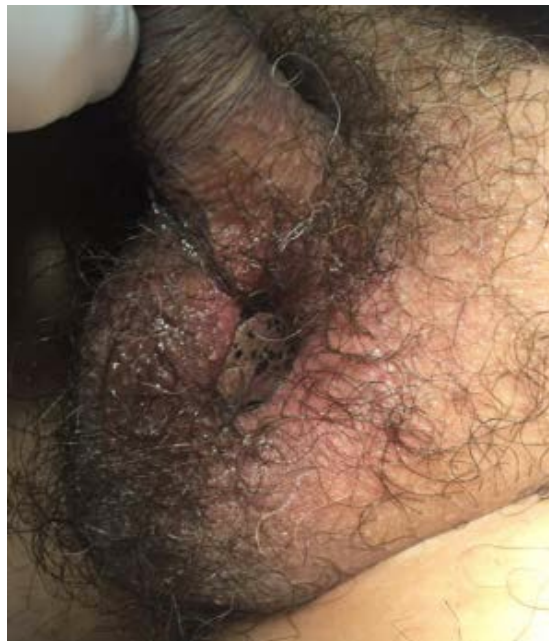

Figure 3. Partial thickness pressure necrosis after removal of magnetic foreign body.

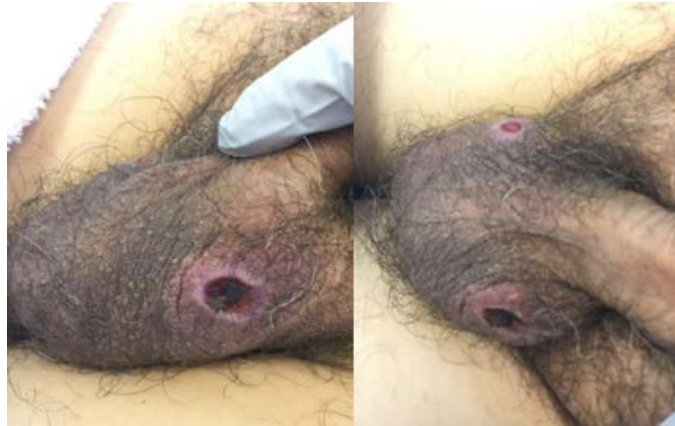

Figure 4. Follow up images with healing bilateral scrotal tissue.

5. Discussion

Urogenital foreign bodies are well reported in the literature and commonly encountered in urologic practice. Removal of these objects can usually be managed by minimally invasive or endoscopic approach with minimal long-term damage to the genitals. Occasionally removal requires ingenious methods devised by staff based on the anatomic location and nature of the object used. Magnetic urogenital foreign bodies however are a less common entity with only a few reported cases in the literature [6] [7]. There is an increased availability of magnetic sex objects on the internet and in stores with an increasing trend and demand for their use. In view of this increasing demand, genital injuries are expected to be seen more often in the future.

As the use of magnetic sex objects becomes more prevalent in the adult population, the clinician should be aware of the possible complications and varying means of management. Removal of magnets can be easily achieved by separating the two magnets by sliding them apart, however when the patient's tissue is entrapped between the magnets, this becomes a difficult task [8]. In other reported cases, the scrotal magnets were removed by surgical excision of the entrapped skin bridge [6], and by simple separation under anesthesia [7].

We present this case as a novel technique for the management of removal of magnetic urogenital foreign bodies. The magnetic force created between the two magnets made their separation near impossible and created a need for alternative removal. The use of two cardiac magnets on each individual magnet relieved the magnetic attraction across the scrotal soft tissue bridge allowing for removal. In this case, the technique was utilized under general anesthesia in the operating room. We feel that this technique is simple and may be easily achieved at the bedside. This could potentially be performed by emergency medical personal on arrival, which would shorten the time to treatment and potentially avoid or mitigate the process of pressure necrosis of the entrapped tissue. We continue to encourage complete work up, including appropriate imaging studies, based on the individuals presenting signs and symptoms. Also, specialist consultations

should be placed as seen appropriate.

6. Conclusion

Urogenital foreign bodies can be a challenge for the clinician. Our novel technique for removal of magnetic urogenital foreign bodies allows for bedside management.

Conflicts of Interest

The authors declare no conflicts of interest regarding the publication of this paper.

References

- [1] Van Ophroven, A. and de Kernion, J.B. (2000) Clinical Management of Foreign Bodies of the Genitourinary Tract. *Journal of Urology*, **164**, 274-287. [https://doi.org/10.1016/S0022-5347\(05\)67342-9](https://doi.org/10.1016/S0022-5347(05)67342-9)
- [2] Blevrakis, E., Raissaki, M., Xenaki, S., Astyrakaki, E., Kholcheva, N. and Chrysos, E. (2018) Multiple Magnet Ingestion Causing Intestinal Obstruction and Enter-Enteric Fistula: Which Imaging Modality Besides Radiographs? A Case Report. *Annals of Medicine and Surgery*, **31**, 29-33. <https://doi.org/10.1016/j.amsu.2018.04.033>
- [3] Dutta, S. and Barzin, A. (2008) Multiple Magnet Ingestion as Source of Severe Gastrointestinal Complications Requiring Surgical Intervention. *Archives of Pediatrics & Adolescent Medicine*, **162**, 123-125. <https://doi.org/10.1001/archpediatrics.2007.35>
- [4] Chung, J.H., Kim, J.S. and Song, Y.T. (2003) Small Bowel Complication Caused by Magnetic Foreign Body Ingestion of Children: Two Case Reports. *Journal of Pediatric Surgery*, **38**, 1548-1550. [https://doi.org/10.1016/S0022-3468\(03\)00514-1](https://doi.org/10.1016/S0022-3468(03)00514-1)
- [5] Anselmi, E., San Roman, C.G., Barrios Fontoba, J.E., *et al.* (2007) Intestinal Perforation Caused by Magnetic Toys. *Journal of Pediatric Surgery*, **42**, e13-e16. <https://doi.org/10.1016/j.jpedsurg.2006.12.066>
- [6] Proano, J.M. and Palmer, J.S. (2005) Erosion of Magnets into the Scrotum in the Pediatric Patient. *Urology*, **66**, 1109.
- [7] Salmasi, M.Y. and Dagash, H. (2015) Mini-Magnets Causing Scrotal Emergency in a 12-Year-Old Boy. *Archives of Disease in Childhood*, **100**, 494. <https://doi.org/10.1136/archdischild-2014-307546>
- [8] McCormick, S., Brennan, P., Yassa, J., *et al.* (2002) Children and Mini-Magnets: An Almost Fatal Attraction. *Emergency Medicine Journal*, **19**, 71-73. <https://doi.org/10.1136/emj.19.1.71>