

Round-Traction-Assisted Pyeloplasty (Ro.T.A.P.): A Minimal Approach Using Alexis® Autostatic Retractor

Vincenzo Domenichelli^{1,2}, Maria Domenica Sabatino¹, Simona Straziuso¹,
Francesco Italiano¹, Silvana Federici¹

¹Pediatric Surgical Unit, “Infermi” Hospital, AUSL Romagna, Rimini, Italy

²In charge of Pediatric Urology Unit, “Infermi” Hospital, AUSL Romagna, Rimini, Italy

Email: zodott@me.com

Received 17 September 2015; accepted 27 October 2015; published 30 October 2015

Copyright © 2015 by authors and Scientific Research Publishing Inc.

This work is licensed under the Creative Commons Attribution International License (CC BY).

<http://creativecommons.org/licenses/by/4.0/>



Open Access

Abstract

Anderson-Hynes dismembered ureteropyeloplasty has been the gold standard surgical treatment for ureteropelvic junction obstruction (UPJO) caused either by crossing renal vessel or by a stenotic junction in children. Nowadays it is still discussed which could be the best surgical approach. All the techniques actually used have the goal to improve functional outcome and to reach better results in terms of reducing traumatic damage, postoperative pain and therefore reduction of hospitalization. We are presenting our experience in the treatment of UPJO by open dismembered pyeloplasty with a minimal invasive approach using the Alexis® (Applied Medical, Rancho Santa Margherita, CA) autostatic wound retractor.

Keywords

Pyeloplasty, Anderson-Hynes, Alexis, Minimally Invasive Surgery, UJPO

1. Introduction

Anderson-Hynes pyeloplasty has been the gold standard in the treatment of pyeloureteral obstruction caused either by stenotic junction or extrinsic obstruction due to crossing renal vessels. Through the years many approaches have been developed to reach the kidney and to have the better operating field possible. Subcostal flank incision with or without muscle sparing or posterior lombotomy are the most used approaches to perform this kind of surgery. In the last decade laparoscopic and retroperitoneoscopic pyeloplasty has reached popularity because of the minimal invasiveness and the surgical benefits over the open techniques [1] [2] even if in

the pediatric population these benefits have yet to be completely proven. Lately a minimally invasive open pyeloplasty without the use of autostatic retractors has also been described [3]. We are describing our approach to the kidney using the Alexis® autostatic retractor to perform the pyeloplasty.

2. Materials and Methods

We made a retrospective review of the experience in our Unit from January 2009 until August 2015.

All the patients were sent to our attention by pediatricians or pediatric nephrologists of our region.

The most important reasons were urinary tract infections (UTI), pre or postnatal ultrasonographic diagnosis of calico-pyelic dilation, flank pain—especially in older children—or casual finding of hydronephrosis during ultrasound scans performed for other problems.

All the patients were evaluated preoperatively with ultrasound renal scan and nucleotide renal scan (mercaptoacetyltriglycine—MAG3 TC99M) with furosemide washout to assess the degree of obstruction.

In some cases we performed a functional renal magnetic resonance (URO-MRI) instead of the MAG3.

The patients were placed under general anesthesia in a modified flank position, with a slight degree of flexion. A Foley catheter was placed in the bladder. As shown in **Figure 1** after the minimal flank incision on the prolongation of the 11th or 12th rib a muscle sparing divarication was performed.

The Gerota's fascia was then opened and at this point the Alexis® autostatic retractor was positioned in place squeezing the inferior ring and inserting it inside the fascia. Once introduced it returns to its original round shape.

This retractor has several features including:

- protecting the skin margin from trauma and contamination,
- retracting the incision through a distributed 360° round traction on the margins, widening the surgical field,
- squeezing the tissutal layers reducing the field depth.

It consists of a round wound retractor, originally designed for abdominal surgery, made of a cylindrical membrane sheath that has two rings (upper and lower) attached to each open end (**Figure 2**).

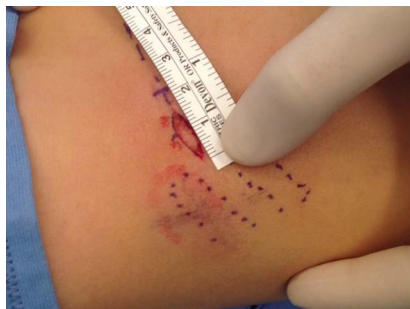

Figure 1. A minimal surgical incision (in this case about 14 mm) on the prolongation of the 11th/12^{ve} rib.



Figure 2. Alexis® autostatic wound retractor (XS size).

Once introduced inside the Gerota's fascia the superior ring is rolled up on itself—like a shirt sleeve (**Figure 3**)—and a circumferential atraumatic traction is performed widening the operating field and protecting the borders of the surgical wound from contamination or electric and traumatic damages [4] [5] (**Figure 4**, **Figure 5**). We usually apply the XS size for all the procedures.

Traditional Anderson-Hynes dismembered ureteropyeloplasty is then performed using 6/0 vicryl interrupted suture under 2.5 extended field magnification and an Urosoft[®] stent or a double J stent is positioned inside the pelvis and the ureter through the sutured anastomosis. In the first 27 cases we also used a Penrose drain that was not positioned in the following ones.

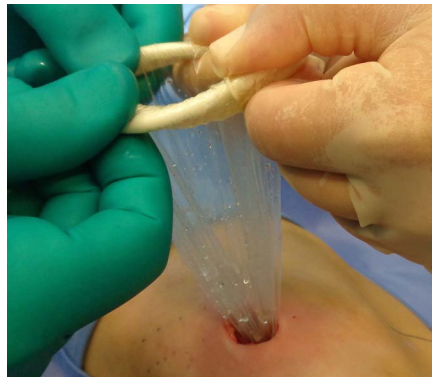

Figure 3. The autostatic retractor in place, being rolled up.

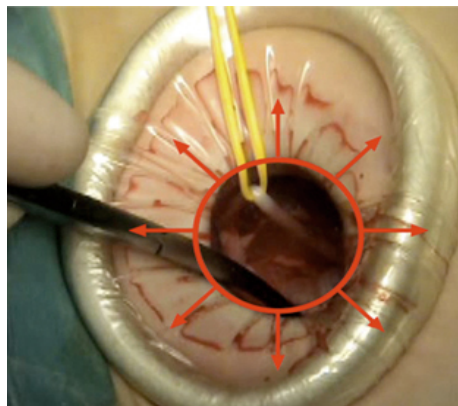


Figure 4. The evenly distribution of the retraction. The arrows show the circumferential distributed force of the traction.

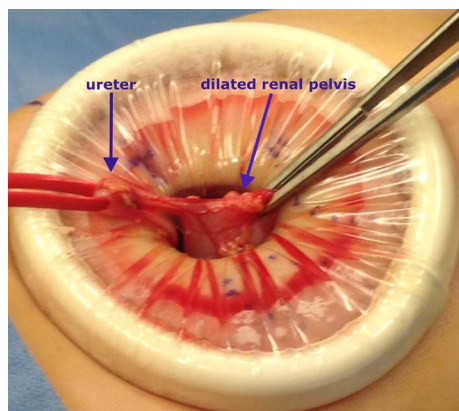


Figure 5. The surgical field with the dilated renal pelvis.

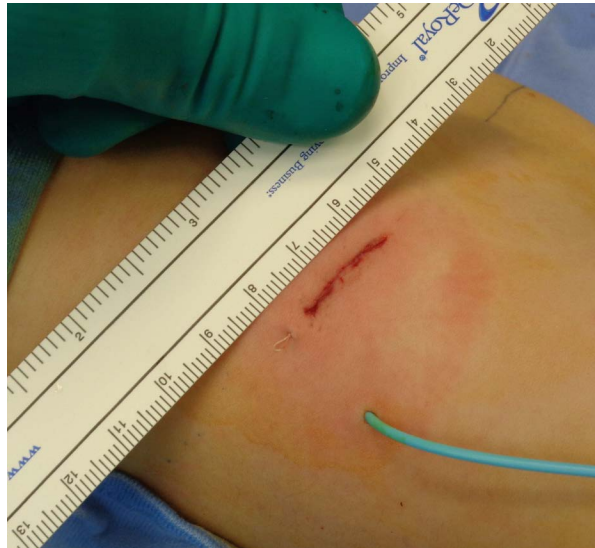

Figure 6. Surgical incision with the blu-stent in place.

The stent (“blue stent” Angiomed Urosoft[®], Bard, UK) [6] is positioned transanastomotically with the straight limb brought through a lower calix of the kidney and then outside throughout the skin, away from the wound (**Figure 6**), while the other limb is placed directly into the bladder or, in some cases, the pig-tail is cut and positioned in the ureter. The intermediate pig-tail is kept into the renal pelvis.

The stent is managed postoperatively with the double diapers system or in older children using a uro-bag.

A Foley catheter is left in the bladder for a few hours after surgery.

Antimicrobial prophylaxis is started the day of surgery and continued on half dose until the removal of the stent.

All patients were managed using fast-track surgery:

- minimally invasive surgery
- optimal postoperative pain control (NRS and/or FLACC pain scale)
- early enteral nutrition (drinking starts around two hours after surgery and eating after three hours) and therefore
- faster recovery with earlier discharge [7] [8]

The blue stent is removed 7 to 10 days after operation on an outpatient basis while the double J is removed approximately four weeks from surgery in the operating room.

In our study we evaluated the length of surgical incision, the operative time and the surgical success (conserved or improved renal function and improvement of pelvic dilation).

3. Results

From January 2009 until August 2015 53 children (39 males and 14 females) were treated for documented UPJO in our Unit. The age at operation ranged from 4 months to 12.3 years (mean age 3.4 years).

35 patients had a left hydronephrosis while 18 had a right one. One was bilateral and one patient had associated an anorectal malformation.

No complication related to pyeloplasty were seen postoperatively but one patient had a urinary tract infection (UTI) and in one case the stent was removed a week later because of the accidental suturing of the stent itself with a subcutaneous stitch.

Operative time ranged from 70 to 140 minutes (mean 108.8 minutes). Length of incision varied from 14 mm to 27 mm (mean length 18.2 mm). In all cases we observed an improvement of both the renal function and the pelvic dilation at follow up (improvement of the grade of hydronephrosis and same or better renal function compared to preoperative ones): ultrasound performed at three months from operation and MAG3 nucleotide renal scan at 12 to 18 months.

All patients were discharged within 48 hours following operation. Cosmetic results were in all cases excellent (**Figure 7**, **Figure 8**).

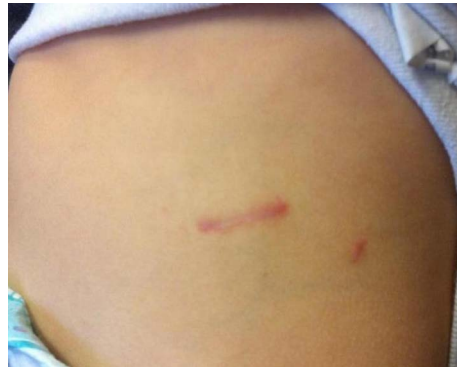

Figure 7. Follow-up at 1 month.

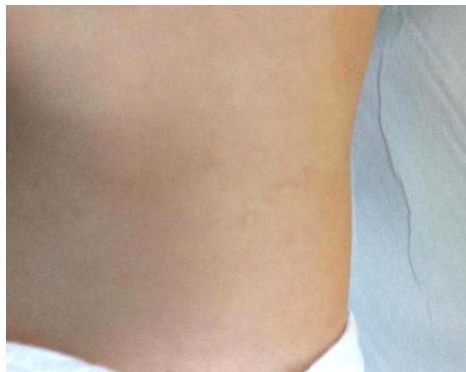

Figure 8. Surgical incision after 1 year.

4. Discussion

In the era of minimally invasive surgery there is still a debate regarding the best surgical approach.

Subcostal flank incision with or without muscle sparing or posterior lombotomy have been the most used approaches to perform this kind of surgery.

The Laparoscopic (LPSc), Retroperitoneoscopic Pyeloplasty (RPSc) and One-Trocar Assisted Pyeloplasty (OTAP) have emerged with good results.

These minimally invasive approaches—compared to open access ones—have many advantages such as reduced postoperative pain and discomfort, low morbidity, minimal incision, less blood loss, short hospitalization and rapid recovery [9].

Wu Y *et al.* in a recent meta-analysis, showed that there are no differences between the laparoscopic and retroperitoneoscopic technique in terms of success and complication rate, although the transperitoneal approach provides a shorter operative time and lower conversion rate [10]. It is also starting to show up the use of robotic-assisted procedures [11]-[13] which at the moment is burdened by very high costs, long learning curve and longer time of execution.

However, there is still some controversy concerning the use of these techniques.

The retroperitoneal approach allows a direct access to the kidney avoiding the colon mobilization needed in transperitoneal approach. On the other hand it also has several disadvantages: limited working space and limited area for port placement, advanced laparoscopic skills for meticulous pelvi-ureteric anastomosis. Operative time is still long, even after the learning curve.

In small children with massive pelvi-calyceal dilation, the retroperitoneoscopic approach can be difficult with the risk of pelvic perforation when introducing the trocars and finally in small patients retroperitoneal space is limited making retroperitoneal suturing particularly challenging [14]-[16].

One trocar assisted pyeloplasty (OTAP) has further advantages: the UPJO is approached and is exteriorized from the retroperitoneal space using only one port. The pelvis and the UPJ are mobilized at the skin level allowing to perform the pyeloureteroplasty under direct vision in an open fashion with minimal scars and minimal

learning curve [17].

At the same time it maintains the advantages of minimally invasive approach: less morbidity, short postoperative recovery, less pain and better cosmetic outcome.

Nevertheless—in our opinion—it also presents some meaningful disadvantages. This technique is of difficult application in case of crossing vessels and intrarotation of the kidney. The mobilization of UPJ at the skin level may cause twisting of the pelvis [9] [17] [18].

Another limitation is mainly related to the thickness of the abdominal wall: it is not suitable for adolescents or obese patients because it is difficult to externalize the pelvis and it requires an enlargement of the surgical incision or a challenging stretching not feasible with traditional retractors.

In our approach the use of such a device as the Alexis® retractor allows to perform an open pyeloplasty with a very small incision (14 - 27 mm).

This retractor protects the skin margin from trauma and contamination, retracts the incision through a distributed 360° round traction on the margins, widening the surgical field and squeezes the tissutal layers reducing the field depth.

The minimally skin incision with muscle sparing reduces the post-operative pain permitting a short hospital stay and an excellent result (Figure 8).

The use of the Alexis® retractor allows to perform a pyeloplasty with all the advantages of minimally invasive surgery using open traditional technique.

Compared to other kind of retractors, like the baby-Balfour with three blades that we used before, the main advantages of the Alexis are the following:

- smaller incision: due to the flexibility of Alexis it can be placed in very small incisions
- evenly distributed traction (Figure 4): having three blades the baby-Balfour gives a triangular shaped field with worse visibility and with the traction exerted mostly on the 3 vertex giving a worse postoperative pain
- better surgical field: as we already said an evenly distributed traction with the addition of the gentle squeezing of the tissutal layers gives a better and wider exposure of the surgical field (Figure 4, Figure 5)
- protection of surgical margins
- possibility of moving the surgical field applying a gentle traction on the superior ring

5. Conclusion

In conclusion we believe that the round traction assisted pyeloplasty could be a good alternative to retroperitoneoscopic or laparoscopic procedures combining the advantages of open pyeloplasty with the advantages of minimally invasive surgery, avoiding at the same time the disadvantages of other techniques: longer learning curve and higher difficulty in managing anatomical anomalies (intra or extrarotation of the kidney; crossing renal vessels; etc.) [3] [9] [11] [12].

References

- [1] Lopez, M., Guyea, E. and Varleta, F. (2009) Laparoscopic Pyeloplasty for Repair of Pelvi-Ureteric Junction Obstruction in Children. *Journal of Pediatric Urology*, **5**, 25-29. <http://dx.doi.org/10.1016/j.jpuro.2008.08.009>
- [2] Canon, S.J., Jayanthi, V.R. and Lowe, G.J. (2007) Which Is Better—Retroperitoneoscopic or Laparoscopic Dismembered Pyeloplasty in Children? *The Journal of Urology*, **178**, 1791-1795. <http://dx.doi.org/10.1016/j.juro.2007.03.200>
- [3] Chacko, J.K., Koyle, M.A., Mingin, G.C. and Furness III, P.D. (2006) The Minimally Invasive Open Pyeloplasty. *Journal of Pediatric Urology*, **2**, 368-372. <http://dx.doi.org/10.1016/j.jpuro.2006.05.001>
- [4] Horiuchi, T., Tanishima, H., Tamagawa, K., Matsuura, I., Nakai, H., Shouno, Y., Tsubakihara, H., Inoue, M. and Tabuse, K. (2007) Randomized Controlled Investigation of the Anti-Infective Properties of the Alexis Retractor/ Protector of Incision Sites. *Journal of Trauma-Injury Infection & Critical Care*, **62**, 212-215. <http://dx.doi.org/10.1097/01.ta.0000196704.78785.ae>
- [5] Tsunetzuka, Y., Oda, M. and Moriyama, M. (2006) Wound Retraction System for Lung Resection by Video-Assisted Mini-Thoracotomy. *Eur J Cardiothorac Surg*, **29**, 110-111. <http://dx.doi.org/10.1016/j.ejcts.2005.10.027>
- [6] Zaidi, Z. and Mouriquand, P.D.E. (1997) The Use of Multipurpose Stent in Children. *British Journal of Urology*, **80**, 802-805. <http://dx.doi.org/10.1046/j.1464-410X.1997.00448.x>
- [7] Wilmore, D.W. and Khelet, H. (2001) Recent Advances: Management of Patients in Fast Track Surgery. *BMJ*, **322**, 473-476. <http://dx.doi.org/10.1136/bmj.322.7284.473>

- [8] Reismann, M., von Kampen, M., Laupichler, B., Suempelmann, R., Schmidt, A.I. and Ure, B.M. (2007) Fast-Track Surgery in Infants and Children. *Journal of Pediatric Surgery*, **42**, 234-238. <http://dx.doi.org/10.1016/j.jpedsurg.2006.09.022>
- [9] Caione, P., Lais, A. and Gerocarni Nappo, S. (2010) One-Port Retroperitoneoscopic Assisted Pyeloplasty versus Open Dismembered Pyeloplasty in Young Children: Preliminary Experience. *The Journal of Urology*, **184**, 2109-2115. <http://dx.doi.org/10.1016/j.juro.2010.06.126>
- [10] Wu, Y., Dong, Q., Han, P., Liu, L., Wang, L. and Wei, Q. (2012) Meta-Analysis of Transperitoneal versus Retroperitoneal Approaches of Laparoscopic Pyeloplasty for Ureteropelvic Junction Obstruction. *Journal of Laparoendoscopic & Advanced Surgical Techniques*, **22**, 658-662. <http://dx.doi.org/10.1089/lap.2011.0508>
- [11] Uberoi, J., Disick, G.I.S. and Munver, R. (2009) Minimally Invasive Surgical Management of Pelvic-Ureteric Junction Obstruction: Update on the Current Status of Robotic-Assisted Pyeloplasty. *BJU International*, **104**, 1722-1729. <http://dx.doi.org/10.1111/j.1464-410X.2009.08682.x>
- [12] Simforoosh, N., Javaherforooshzadeh, A., Aminsharifi, A., Soltani, M.H., Radfar, M.H. and Kilani, H. (2010) Laparoscopic Management of Ureteropelvic Junction Obstruction in Pediatric Patients: A New Approach to Crossing Vessels, Crossing Vein Division, and Upward Transposition of the Crossing Artery. *Journal of Pediatric Urology*, **2**, 161-165. <http://dx.doi.org/10.1016/j.jpuro.2009.07.010>
- [13] Kajbafzadeh, A.-M., Tourchi, A., Ghazi Nezami, B., Khakpour, M., Mousavian, A.-A. and Shafaat Talab, S. (2011) Miniature Pyeloplasty as a Minimally Invasive Surgery with Less than 1 Day Admission in Infants. *Journal of Pediatric Urology*, **7**, 283-288. <http://dx.doi.org/10.1016/j.jpuro.2011.02.030>
- [14] Valla, J.S., Breaud, J., Griffin, S.J., *et al.* (2009) Retroperitoneoscopic vs Open Dismembered Pyeloplasty for Ureteropelvic Junction Obstruction in Children. *Journal of Pediatric Urology*, **5**, 368-373. <http://dx.doi.org/10.1016/j.jpuro.2009.02.202>
- [15] Zhou, H., Li, H., Zhang, X., *et al.* (2009) Retroperitoneoscopic Anderson-Hynes Dismembered Pyeloplasty in Infants and Children: A 60-Case Report. *Pediatric Surgery International*, **25**, 519-523. <http://dx.doi.org/10.1007/s00383-009-2369-z>
- [16] Blanc, T., Muller, C., Abdoul, H., *et al.* (2013) Retroperitoneal Laparoscopic Pyeloplasty in Children: Long-Term Outcome and Critical Analysis of 10-Year Experience in a Teaching Center. *European Urology*, **63**, 565-572. <http://dx.doi.org/10.1016/j.eururo.2012.07.051>
- [17] Lima, M., Ruggeri, G., Messina, P., Tursini, S., Destro, F. and Mogiatti, M. (2015) One-Trocar-Assisted Pyeloplasty in Children: An 8-Year Single Institution Experience. *European Journal of Pediatric Surgery*, **25**, 262-268.
- [18] Scuderi, M.G., Arena, S. and Di Benedetto, V. (2011) One-Trocar-Assisted Pyeloplasty. *Journal of Laparoendoscopic & Advanced Surgical Techniques*, **21**, 651-654. <http://dx.doi.org/10.1089/lap.2010.0115>