

# Wireless Capsule Cystoscopy: How Near? How Far?

**Hakan Öztürk**

Department of Urology, School of Medicine, Sifa University, Izmir, Turkey  
Email: [drhakanozturk@yahoo.com.tr](mailto:drhakanozturk@yahoo.com.tr)

Received 1 April 2014; revised 22 April 2014; accepted 28 April 2014

Copyright © 2014 by author and Scientific Research Publishing Inc.  
This work is licensed under the Creative Commons Attribution International License (CC BY).  
<http://creativecommons.org/licenses/by/4.0/>



Open Access

---

## Abstract

It is a fact that performing endoscopy using conventional methods requires substantial time and development of alternative diagnostic modalities. Replacement of rigid endoscopes with flexible and digital devices in time, faster performance of the procedures and reduced time for them to turn back to work brought about the expectancy. It was possible that easier and more reliable methods could exist. Idea of capsule endoscopy was born following examination of the gastrointestinal tract with an endoscope with shape of a capsule. Although idea of capsule endoscopy was suggested long years ago, it fell behind the advances in conventional step of the endoscopy, especially developmental speed of the flexible devices. Furthermore, three-dimensional (3D) organ views can be processed digitally by means of sophisticated software in the fields of computerized tomography and magnetic resonance imaging. Thus, virtual cystoscopy of high resolution and specificity is possible by means of both methods. Wireless capsule endoscopy is still in the experimental stage. "Steerable independent intracorporeal endoscope" with feature of consecutive instillation in addition to its diagnostic utility is not a dream.

## Keywords

Cystoscopy, Wireless Capsule Cystoscopy, Virtual Cystoscopy, Air Cystoscopy, Hematuria, Bladder Cancer

---

## 1. History of the Cystoscopy

Like desire to examine the organs in the human body, idea of the endoscopy dates back to Hippocrates. The first endoscope was explored by Philipp Bozzini in 1806 [1]. Cystoscopy was developed by Maximilian Nitze in 1876 followed by discovery of resectoscope in 1926, mounting camera system on the endoscope in 1956, and discovery of fiberoptic endoscope in 1963. Beliefs of the urologists in the endoscopy have been encouraged for other fields of science as well. The search and advances in endoscopy have continued without slowing down

while also enabling virtual cystoscopy at the present. The flexible technology advanced rapidly to eliminate disadvantages of the flexible fiber optic devices such as being heavy and semi-mobile by means of digital sensor-fitted cystoscopes. The digital cystoscopes have become very important devices because of being lighter, thinner, and possibility of mounting integral light source on them and wireless data transfer. This technology is progressing on its own track [2].

## 2. Virtual Cystoscopy CT and MRI

Virtual cystoscopy is technically based on processing the images gained by creating a density of intensity gradient between the wall and lumen of the bladder through computer software and converting them to 3D images. Conventional cystoscopy is gold-standard method for diagnosing early recurrence after transurethral resection in bladder cancer. Although being rare, complications of the procedure include infection, perforation, and urethral occlusion [3]. However, it is possible to perform virtual endoscopy in the case of some patients not willing to undergo conventional cystoscopy, possible complications, occurrence of hematuria during the procedure, bladder diverticula, insufficient imaging of the anterior wall, and contraindications of the conventional cystoscopy.

CT virtual cystoscopy doesn't have as adequate sensitivity as the conventional cystoscopy. Virtual cystoscopy is a method suitable for evaluating the lesions larger than 5 mm. obtaining 360° images from difficult-to-reach areas of the bladder is a very suitable method in the patients in whom conventional cystoscopy can't be performed or is contraindicated. The method possesses about 90% to 95% sensitivity and specificity [4]. Furthermore, making diagnosis of ureter and pelvis renalis tumor using nephroscopy with sensitivity of 81% and specificity of 100% has shown that endoluminal navigation by means of virtual urological endoscopy is reliable and non-invasive. However, inability to detect the changes in tissue and color of the mucosa, to diagnose the flat lesions and carcinoma in situ, impossibility of taking washing sitology and to perform biopsy are limiting factors [5]. In contrast to CT virtual cystoscopy, MRI virtual cystoscopy doesn't require radiation exposure or using iodinated contrast medium. It is a non-invasive imaging technique. T2-weighted images have the same sensitivity and specificity with CT virtual cystoscopy. Movement of the patient and low volume of urine are the factors limiting quality of the image. Disadvantages of the method include long time to perform it and low spatial resolution [6].

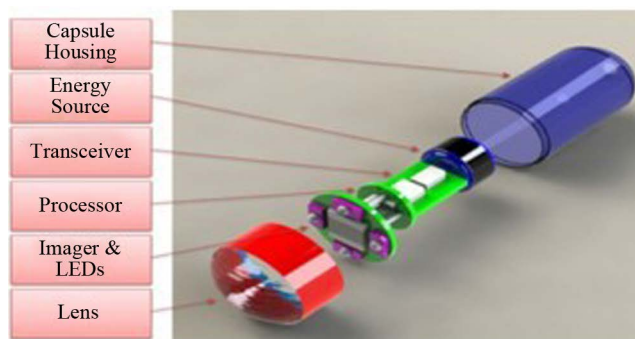
## 3. Air Cystoscopy

Technically, cystoscopy is performed by using fluid first after the cystoscope is conventionally inserted in the bladder. The bladder is emptied and then about 200 ml of air is given and the bladder is visualized. The most important advantage of the method is possibility of obtaining clearer images in the presence of active hematuria. Air embolism is a theoretical complication and hasn't been reported so far. No unique complications have been reported in the studies. It has been found that the method has higher specificity than conventional fluid-system cystoscopy in the presence of active hematuria [7].

## 4. Wireless Capsule Cystoscopy

The standard gastrointestinal capsule consists of metal-oxide silicon imager of 26 × 11 mm with LED light source at its optical tip, transmitter, and 2 silver-oxide batteries. Basically, it yields two images per second. It stores 50.000 images at ×8 magnification during passage of 8 hours. It is covered by a non-adhesive covering. Visualizing the intestine in its natural position, absence of endoscopic trauma and air insufflation are the main advantages of the method. Its disadvantages include its impossibility to be performed in the patients with dysphagia, false-negative results and impossibility to take biopsies. Its rare complications include capsule retention (1% - 5%), intestinal obstruction (0.5%), and aspiration. It is contraindicated in the case of intestinal obstruction, pregnancy, and AICD cardiac pacemakers [8]. Capsule endoscopy may be viewed as complementary to the conventional endoscopes.

Wireless capsule cystoscopy hasn't found widespread utility as in gastrointestinal field. In the relevant literature, two experimental studies were published. The first study was carried out on a swine model in 2009. Images were taken from the lumen of bladder by directing the capsule with an external magnet after the capsule had been inserted in the bladder [9]. The second study was sheep model of bio-film covered capsule endoscopy (length: 25 mm, diameter: 7 mm) carried out in 2013 (Figure 1).



**Figure 1.** Wireless capsule cystoscopes.

It was reported that no change occurred in micturition behavior, no growth occurred in the urine culture, and no encrustation occurred although fine endoscopic images were taken from the capsule retain in the sheep bladder for 5 months. The study presented the method as a new nano-technology product creating a biofilm layer on external surface of foreign bodies in the urinary tract. Efforts to transfer high-quality images are still going on [10]. Technological advance is required for directing the capsule in the lumen and terminating the completed procedure. The future target is independent “intracorporeal endoscope”.

## 5. Conclusion

It is hard to predict the future of endoscopy. But currently, we can see that the technologies once thought to be unimaginable are progressing rapidly. An independent orientable endoscope, *i.e.* “intracorporeal endoscope” is not a dream. Even the microendoscopes to examine lumen of the ductus deferens seem to be possible in near future. An application of the physics of endoscopy is optic coherence tomography (OCT). This method is based on processing high-resolution sectional tomographic image of micro-structure in the biological systems after the infra-red ray reflects from the tissues just like the physical B-mod of ultrasound. Tissue specific characteristic spectrum can be detected by making qualitative and quantitative measurements from the pseudo-color map of the light emitting from every type of tissue using tissue spectroscopy called Raman’s spectroscopy in the field of molecular biology. Thus, it will be possible to say whether the tissue is normal or pathological. These rapidly spreading technological advances will continue until the endoscopy is no longer required. Thus, capsule cystoscopy is not a dream. It is considered that by the means of developed technology, the wireless capsule cystoscopy will be used for intraluminal immune-chemotherapy after it passes rapidly the diagnostic stage.

## Conflicts of Interest

There are not any conflicts of interest as the letter has been written by only one author. The author had no financial support.

## References

- [1] Verger-Kuhnke, A.B., Reuter, M.A. and Beccaria, M.L. (2007) Biography of Phillip Bozzini (1773-1809) an Idealist of the Endoscopy. *Actas Urológicas Españolas*, **31**, 437-444. [http://dx.doi.org/10.1016/S0210-4806\(07\)73666-5](http://dx.doi.org/10.1016/S0210-4806(07)73666-5)
- [2] Natalin, R.A. and Landman, J. (2009) Where Next for the Endoscope? *Nature Reviews Urology*, **6**, 622-628. <http://dx.doi.org/10.1038/nrurol.2009.199>
- [3] Babjuk, M., Oosterlinck, W., Sylvester, R., Kaasinen, E., Böhle, A. and Palou-Redorta, J. (2008) EAU Guidelines on Non-Muscle-Invasive Urothelial Carcinoma of the Bladder. *European Urology*, **54**, 303-314. <http://dx.doi.org/10.1016/j.eururo.2008.04.051>
- [4] Lopes, R.I., Nogueira, L., Albertotti, C.J., Takahashi, D.Y. and Lopes, R.N. (2008) Comparison of Virtual Cystoscopy and Transabdominal Ultrasonography with Conventional Cystoscopy for Bladder Tumor Detection. *Journal of Endourology*, **22**, 1725-1729. <http://dx.doi.org/10.1089/end.2007.0363>
- [5] Panebianco, V., Sciarra, A., DiMartino, M., Bernardo, S., Vergari, V., Gentilucci, A., Catalano, C. and Passariello, R. (2010) Bladder Carcinoma: MDCT Cystography and Virtual Cystoscopy. *Abdom Imaging*, **35**, 257-264. <http://dx.doi.org/10.1007/s00261-009-9530-y>

- [6] Beer, A., Saar, B., Zantl, N., Link, T.M., Roggel, R., Hwang, S.L., Schwaibold, H. and Rummeny, E.J. (2004) MR Cystography for Bladder Tumor Detection. *European Radiology*, **14**, 2311-2319. <http://dx.doi.org/10.1007/s00330-004-2451-9>
- [7] Ciudin, A., Diaconu, M.G., Gosalbez, D., Peri, L., Garcia-Cruz, E., Franco, A. and Alcaraz, A. (2013) Air Cystoscopy Is Superior to Water Cystoscopy for the Diagnosis of Active Hematuria. *The Journal of Urology*, **190**, 2097-2101. <http://dx.doi.org/10.1016/j.juro.2013.06.040>
- [8] Koulaouzidis, A., Rondonotti, E. and Karargyris, A. (2013) Small-Bowel Capsule Endoscopy: A Ten-Point Contemporary Review. *World Journal of Gastroenterology*, **19**, 3726-3746. <http://dx.doi.org/10.3748/wjg.v19.i24.3726>
- [9] Gettman, M.T. and Swain, P. (2009) Initial Experimental Evaluation of Wireless Capsule Endoscopes in the Bladder: Implications for Capsule Cystoscopy. *European Urology*, **55**, 1207-1212. <http://dx.doi.org/10.1016/j.eururo.2009.01.047>
- [10] Neheman, A., Schulman, C. and Yossepowitch, O. (2013) Novel Anti-Biofilm Mechanism for Wireless Capsule Endoscopy in the Urinary Tract: Preliminary Study in a Sheep Model. *BJU International*, **111**, 1156-1160. <http://dx.doi.org/10.1111/bju.12040>