

Sinus Lift versus Short Implants: Results of a Prospective Radiologic Study and Critical Review of Minimally Invasive Transcrestal Sinus Lift Procedures

Izabela Schlichting¹, Dagmar Lacina¹, Bianca Fischak-Treitl²

¹Practice for Dentistry and Oral Implantology, Vienna, Austria

²Office for General Dentistry and Implantology, Mattersburg, Austria

Email: ordination.tsl@gmail.com, ordination@dr-fischak-treitl.at

How to cite this paper: Schlichting, I., Lacina, D. and Fischak-Treitl, B. (2017) Sinus Lift versus Short Implants: Results of a Prospective Radiologic Study and Critical Review of Minimally Invasive Transcrestal Sinus Lift Procedures. *Open Journal of Stomatology*, 7, 1-24.

<http://dx.doi.org/10.4236/ojst.2017.71001>

Received: November 27, 2016

Accepted: December 26, 2016

Published: December 29, 2016

Copyright © 2017 by authors and Scientific Research Publishing Inc. This work is licensed under the Creative Commons Attribution International License (CC BY 4.0).

<http://creativecommons.org/licenses/by/4.0/>



Open Access

Abstract

Introduction: The current discussion about the use of short implants to avoid bone-augmentation (“sinus lift”) in the lateral maxilla remains a controversial topic and is increasingly at odds with the reality of evolutionary biology. Aim of the study was to determine the percentage of cases from a large routine patient-sample in which short implants might be suitable to avoid sinus lift procedures. **Materials and Methods:** From January 2012 to June 2015, all patients in three general dental practices in Austria with at least one subantral edentulous area were subjected to routine panoramic X-ray screening. The subantral alveolar ridge heights and the mesial extension of the maxillary sinus towards the canine fossa were measured. Statistics were performed by Excel data analysis (mean value, standard deviation). **Results:** 2837 patients were screened with 2837 panoramic radiographs presenting 3528 edentulous subantral regions and the subantral bone heights of 5674 maxillary sinuses were surveyed. 57.43% revealed subantral alveolar ridge heights of 4 mm or less; 24.43% of all measure-points indicated a maximum alveolar ridge height of 6 mm. In 39.32% of cases, the pneumatization of the maxillary sinuses with a subantral residual ridge height of 6 mm or less extended as far as the anatomical position of the second premolars, in 20.51% as far as the position of the first premolar and in 10.84% as far as the canine fossa. **Discussion:** The sinus lift procedure will continue to be one of the basic standard surgical procedures carried out by practice-based dental surgeons who perform implant surgery since in at least two thirds of the cases short implants with lengths of less than 6 mm cannot be applied. Preference should be given to sinus lift-procedures, which can be learned safely with a minimum of time-effort, least risk of failure and lowest possible level of patient morbidity. Transcrestal hy-

drodynamic ultrasonic sinus lift-procedures with piezotomes seem to fulfill these basic demands.

Keywords

Oral Surgery, Implantology, Sinus Lift, Piezotome Surgery, Ultrasonic Surgery, Short Implants

1. Introduction

As result of an increased desire for permanent dental restorations among an aging population, dental implantology is becoming increasingly important for practice-based dentists outside urban growth areas. Whereas it was easy to keep abreast of available dental implant systems at the turn of the century, more and more manufacturers are now competing on the market of practice-based dental surgeons and prospective implantologists, in order to fulfill the wish of the increasing number of patients for single-tooth, edentulous space and full-mouth restorations with implants instead of removable partial or full overdentures.

In fact, to a significant extent, tooth loss brought about by advancing age mainly affects the maxillary molar and premolar region [1] and the practice-based dentist as a prospective or established implantologist must deal with the serious problem of inadequate maxillary subantral bone-height for the insertion of implants.

However, one of the oldest [2] and since 1977 exhaustively researched maxillary bone augmentation techniques—the sinus lift-surgery—still remains a black box for many implantologists and indeed, many implantologists shy away from learning the technique and look for a “simple” alternative in order to avoid having to perform sinus augmentation surgery.

Implant manufacturers are only too willing to fulfill this desire by offering ever shorter implants (4 mm) in spite of the inflexibly limited and evolutionary biologically determined load that can be introduced into alveolar bone [3] [4]. However, it is an established fact that the trabecular bone structure [5] prefers longer implants, especially in the maxillary alveolar bone.

Incomprehensibly (and most probably to the disadvantage of practice-based dentists and their patients) the natural peri-implant crestal bone loss resulting from remodelling, the increasing and therapeutically unresolved problem of periimplantitis and the associated rapid resorption of crestal bone—particularly in the case of short implants of 4 - 5 mm in length—are being completely ignored. Therefore the rates of implant loss [6] [7] might increase dramatically to the annoyance of patients in the upcoming decades.

Whereas until recently, short implants with lengths of 7 - 10 mm were referred to as “short implants” [8] [9] and their suitability for placement in the maxilla was hotly debated, implant lengths of 6 mm are already being “re-searched” (and depending on the sponsorship of the “research”) discussed with

euphoria [10] or very critically [11], without giving practice-based dentists and implantologists even a minimum of information about prosthetic concepts for which they are suitable and unbiased long term success-rates over ten years or more.

The secured and long-established knowledge of the biomechanical limits of (alveolar) bone towards introduced forces [12]—which in general medical specialties such as orthopaedic surgery, traumatology and craniomaxillofacial surgery are the prerequisite of knowledge for responsible surgical practice—is simply being ignored or even deliberately denied in dentistry and oral surgery and sacrificed to the desire for “simple” implant solutions.

Even if in 10 - 15 years' time and after serious and unbiased long-term studies 4 mm-implants prove to have an acceptable long-term prognosis in the maxillary premolar and molar region; it remains debatable whether, in the light of an individual anatomical patients situation, short implants could abandon sinus augmentation surgery entirely or at least reduce case-numbers in need of sinus lifting.

The aim of the present prospective radiologic study was to investigate the subantral crest-heights of potential implant insertion-sites and mesial extension of the maxillary sinuses from a large and representative multicentre routine patient-sample based on panoramic X-rays. Furthermore, the percentage of patients in this collective—suitable to receive short implants of 6 mm length or less—was to be determined and new surgical techniques for minimal invasive sinus-lift-procedures discussed.

2. Materials and Methods

From January 2012 to June 2015, in three general dental practices providing also oral implantology-services, all routinely taken panoramic X-rays of all patients presenting at least one subantral edentulous area were investigated. Since all investigated X-rays were performed as routine-necessity in the course of a regular treatment, no approval from an ethical committee was necessary according to EMEA-guidelines for this prospective radiographic study. The residual alveolar ridge height at potential subantral implant insertion sites was measured and the mesial sinus extension into the premolar or canine region was determined.

In order to ensure precise results all panoramic X-ray-units (Instrumentarium Dental OP200VT, KaVo Pan eXam Plus 3D, ACTEON XMind Trium) were calibrated regularly every day and panoramic X-rays were assessed by a practice-oriented classification scheme, which served as an aid to decision-making and planning for practice-based dentists and implantologists (Figure 1).

The values obtained for the subantral alveolar ridge height of each individual potential implant insertion site at the anatomical tooth position were assigned to five different groups:

Group I: Subantral alveolar ridge height up to 2 mm.

Group II: Subantral alveolar ridge height of 2 - 4 mm.

Group III: Subantral alveolar ridge height of 4 - 6 mm.

Group IV: Subantral alveolar ridge height of 6 - 8 mm.

Group V: Subantral alveolar ridge height > 8 mm.

Regardless of present dentition or toothlessness in the maxillary region investigated, the mesial extensions of all maxillary sinuses into the premolar and canine region in all collected panoramic X-rays were determined with an upper limit of 6 mm subantral crest height and classified into three groups (resulting sample size: 5674) (**Figure 2**):

Group I: Extension as far as the 2nd premolar.

Group II: Extension as far as the 1st premolar.

Group III: Extension as far as the canine region.

The decision to take 6 mm subantral crest-height as the upper-limit-value for the determination of clinically relevant mesial extensions of the sinuses was based on the availability of short implants marketed for this indication.

Statistic evaluation was performed by Excel data analysis (mean value, standard deviation, percentage distribution).

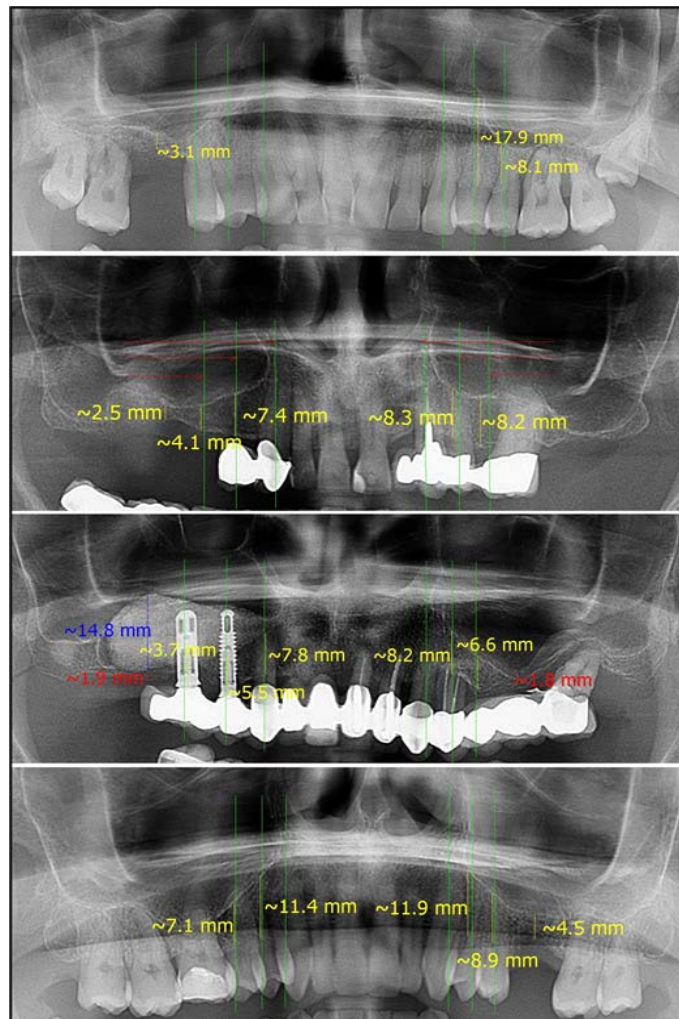


Figure 1. Measurement scheme of the subantral alveolar ridge heights from canine- to first molar-regions (values above 2 mm in yellow, values below 2 mm in red) and mesial extension of the maxillary sinuses (vertical green lines).

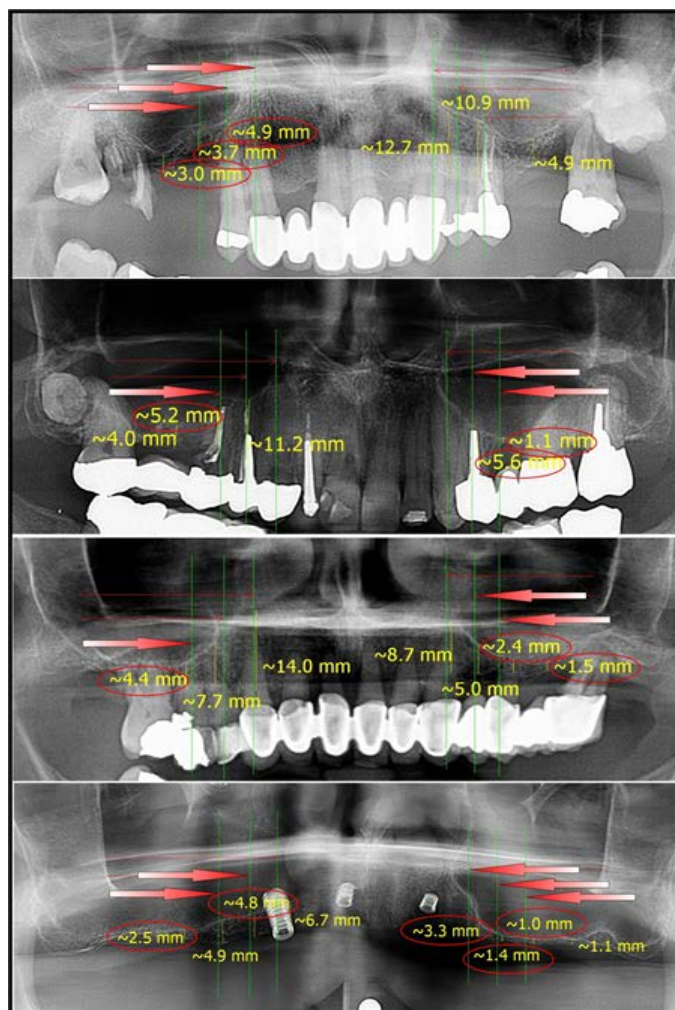


Figure 2. Determination of the mesial extension of the maxillary sinuses according to the measurement protocol. Red arrows indicate the mesial extension when less than 6 mm.

3. Results

2.837 patients (1.685 female/1.152 male) were screened, aged between 24yrs and 82 years. In 2.837 consecutive panoramic X-rays from 2.837 patients, the subantral alveolar ridge heights at 3.528 edentulous anatomical sites were measured and the distribution of the anatomical position (canine, 1st premolar, 2nd premolar, 1st molar, 2nd molar) analyzed (**Table 1**).

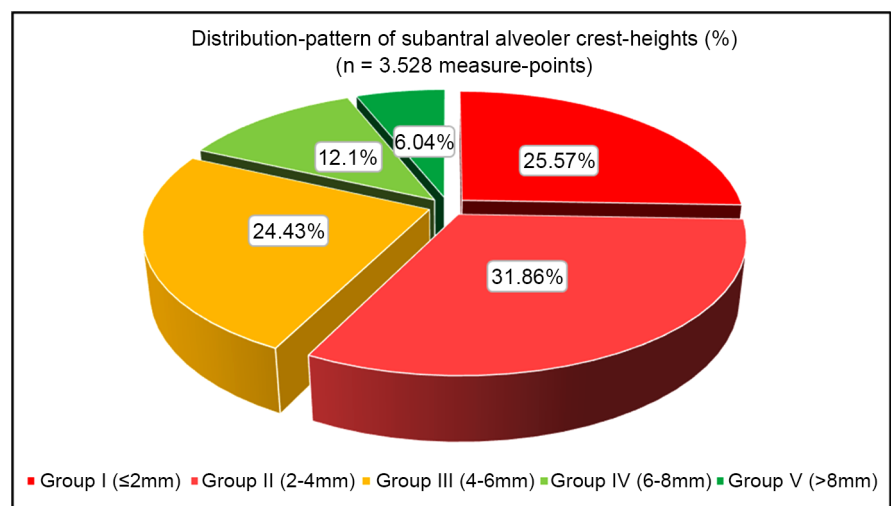
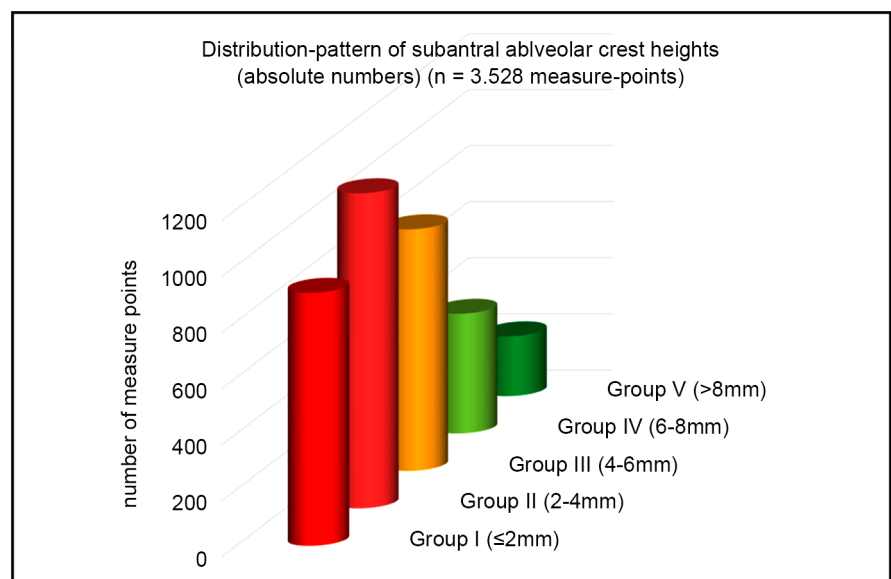
57.43 per cent of all subantral alveolar ridge heights measured showed a ridge height of 4 mm or less. 24.43% of measuring points indicated a maximum alveolar ridge height of 6 mm (**Figure 3** and **Figure 4**).

In 50.71% of all cases, the measure-point distribution indicated mainly missing first molars, followed by missing second premolars in 27.1% of cases (**Figure 5**).

The mesial pneumatization in 5.674 of the maxillary sinuses measured with a subantral residual ridge height of 6 mm or less extended in 39.32% of the cases as far as the anatomical position of the second premolars, in 20.51% the position of the first premolars and in 10.84% the canine fossa (**Figure 6**).

Table 1. Statistic analysis of subantral crest heights (mean value, standard deviation) and measure-point distribution in percent.

Alveolar ridge heights	Measure points	%	Mean (mm)	Std. dev. (mm)	Measure-point distribution	%
n =	3528				n =	3528
Group I (≤ 2 mm)	902	25.57	1.6	0.2	2 nd maxillary molar	264 7.48
Group II (2 - 4 mm)	1124	31.86	3.1	0.3	1 st maxillary molar	1789 50.71
Group III (4 - 6 mm)	862	24.43	4.8	0.5	2 nd maxillary premolar	956 27.10
Group IV (6 - 8 mm)	427	12.10	7.3	0.4	1 st maxillary premolar	383 10.86
Group V (> 8 mm)	213	6.04	10.7	1.2	Canine	136 3.85

**Figure 3.** Results and distribution of edentulous measure-points of the subantral alveolar ridge heights in percentages.**Figure 4.** Results and distribution of the edentulous measure-points of the subantral alveolar ridge heights as absolute numbers.

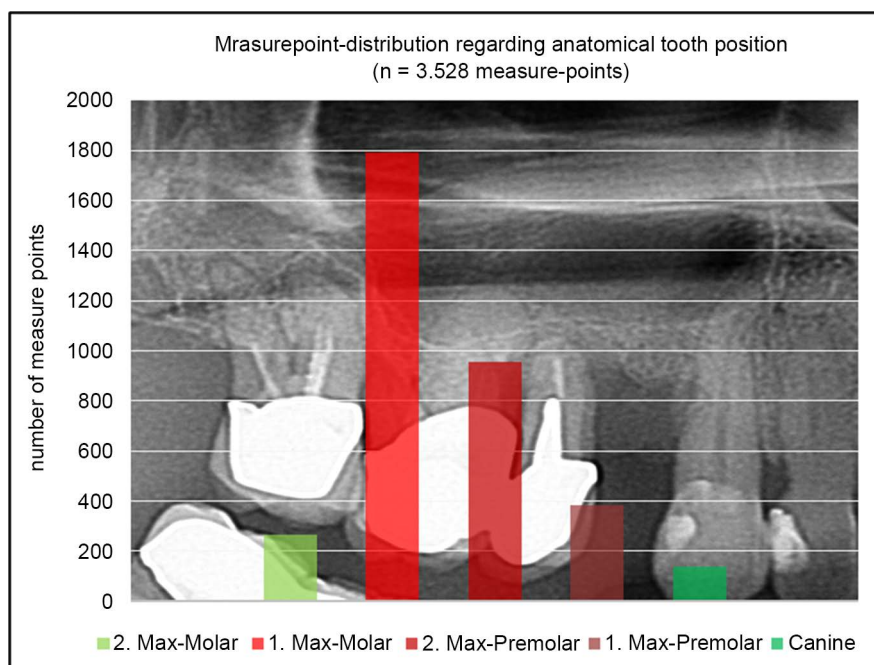


Figure 5. Distribution pattern of the measured subantral tooth positions as absolute values: missing first molars are significant.

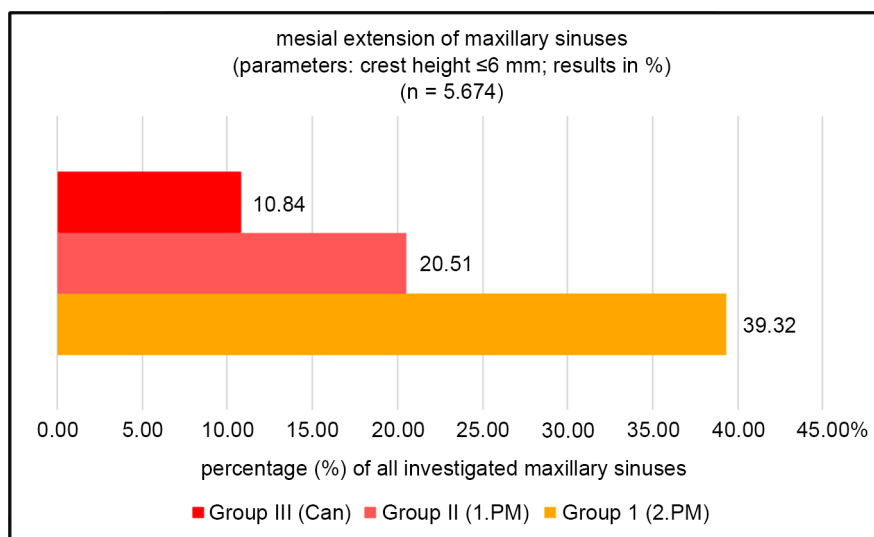


Figure 6. Percentage of distribution of the mesial extension of the maxillary sinuses when the value is less than the 6 mm for the subantral alveolar ridge height.

No significant difference was found between female and male patients and age ($p < 0.05$).

4. Discussion

The present study is probably the most comprehensive representative clinical study of subantral alveolar ridge heights and mesial extensions of human sinuses in an equally distributed and mainly Caucasian patient population and agrees with similar studies published, yet with smaller samples [13]. The results inevit-

ably have a major impact on decision-making when it comes to implant-insertion in the maxillary premolar and molar region.

Even if the use of short 4 mm implants does prove to be a reliable alternative to sinus-lift-surgery within the next 10 - 15 years, 4 mm short implants cannot be used at all in more than 57% of all patient cases.

6 mm short implants, which continue to be the subject of much controversy [10] [11] and are without any long-term studies over 10 - 15 years, cannot be used at all in over 81% of all cases.

It is therefore still mandatory for the implant-dentist to learn and to perform surgical techniques for sinus lifting to serve the vast majority of his/her patients (~80%) with complete implant-treatment in the lateral maxillary region.

Sinus augmentation is a quite simple surgical procedure, which nevertheless requires a high degree of manual dexterity in order to avoid the only possible complication, which is a puncture or rupture of the sinus membrane. Recent scientific literature reports rates of sinus membrane perforations at sinus lift surgeries using a lateral window approach with consecutive loss of graft material and successive sinusitis between 25% and over 50% of all cases [14] [15] [16].

In order to significantly reduce postsurgical morbidity associated with sinus augmentation by a lateral bone-window approach (massive postoperative swelling, bruising, pain, loss of productivity), the transcrestal approach would be a suitable alternative. Even if the sinus membrane is perforated during a transcrestal approach and surgery has to be aborted, the patient at least does not have to suffer postoperative swelling or pain in addition to the frustration of a failed operation. With a transcrestal approach, there is less postsurgical morbidity than at a simple tooth extraction [13].

4.1. Biologic and Physiologic Basis of Sinus Lift Surgery

The key-factor for success of sinus lift surgeries is the atraumatic detachment of the periosteum of the maxillary sinus membrane from the bony antrum-floor—comparable to the preparation of a mucoperiosteal flap or subperiosteal tunnel [12]—in order to provide a reliable osseointegration of and bone regeneration around the grafting material, which can only take place with a fully intact periosteum [17].

However, even if the sinus-membrane seems intact in the surgeons eye and does not show any sign of perforation after detachment and elevation is completed, many sinus lift procedures, both with lateral window and with crestal approach, only result in a dissection of the sinus membrane on histologic level [18]. As a consequence (the periosteum continues to adhere to the maxillary sinus floor and only the respiratory maxillary sinus epithelium is elevated), the graft material (autologous bone or biomaterial) is now inserted into a scaffold of the dissected connective tissue where it cannot ossify, since there is no periosteal cover around the graft material providing preosteoblasts, osteoblasts, BMPs and other humoral bone-growth-factors [12] [17]. Even if the X-ray seems to show a stable sinus-augmentation without any dislocation of the grafting material into

the sinus-cavity, no bone-regeneration will take place regardless which type of bone-graft is used (autologous, bovine xenograft, synthetic biomaterial). Consequently, the sinus lift procedure will be a clinical failure since no regenerated bone but only loose and fibrous encapsulated granules will be found at the time of implant insertion (**Figure 7**).

In order to avoid any perforation and intrasurgical dissection of the sinus membrane, which would be impossible to detect intrasurgically, the sinus lift procedure (both lateral and transcrestal) has to be separated in two phases regarding the risk of sinus-membrane-perforations.

4.1.1. Preparation of the Access to the Periosteum of the Sinus Membrane (Basic Lateral or Transcrestal Osteotomy)

For osteotomies of the lateral osseous sinus wall and/or of the subantral alveolar bone, ultrasonic surgical instruments (piezotome units) and preparation techniques proved to result in significant less perforations of the sinus-membrane compared to rotary instruments, even in less expert hands [19] [20]. The successful performance of this first step in sinus lift-surgery demands patience and sensitivity and is the first key-factor to avoid perforations.

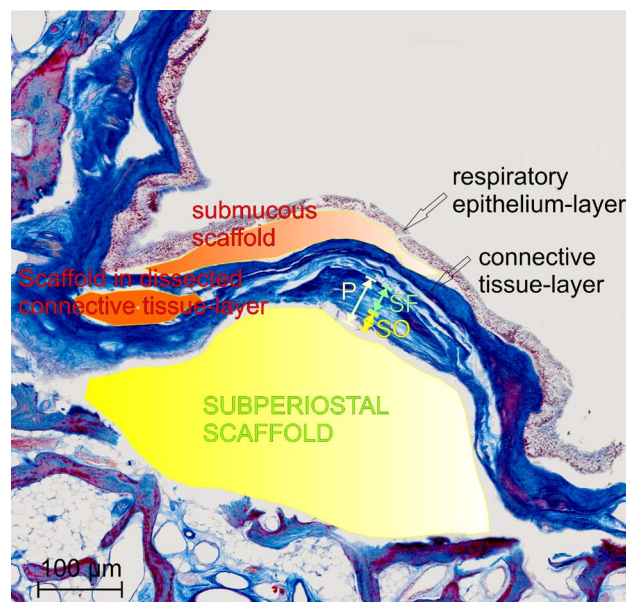


Figure 7. Histologic cross-section of a maxillary sinus antrum after the sinus membrane has been detached (Azan-stained specimen at 20 x magnification). As a physiologic unit, the sinus membrane consists of the respiratory epithelium, a layer of connective tissue, and the basal periosteum. The periosteum (P) itself is subdivided into the fibrous layer (“stratum fibrosum”, SF) and the osteogenic layer (“stratum osteogenicum”, the sole origin of pre-osteoblast cells, SO). Only if the graft material is inserted subperiosteal, graft materials (autologous, xenogenic or synthetic bone material) can properly osseointegrate and newly formed bone be mineralized osteoblasts migrating from the osteogenic layer of the periosteum. If a dissection of the sinus membrane occurs at transcrestal trepanation or membrane-detachment, the graft material is inserted into the connective-tissue-layer or submucosal. Therefore, the X-ray image will show a successful sinus lift, but there will be no osseointegration of the grafting-material and new bone-growth, but only a fibrous encapsulation of the graft-material.

4.1.2. Precise Detachment of the Periosteal Layer of the Sinus Membrane

Compared with the mucoperiosteum of the oral cavity the mucoperiosteum of the maxillary sinus membrane is much more delicate and more easily damaged if shear-forces and tensile forces are exerted during preparation [21]. This does not apply to pressure forces. However, every mechanical detachment-instrument (blunt or sharp-edged sinus membrane elevators, Summers osteotomes) exerts tremendous shear forces on the sinus membrane in the detachment-process resulting in a high risk of partial or total rupture of the sinus-membrane, especially in the hands of an inexperienced practitioner [15] [16].

Contrary, when using hydraulic and/or hydrodynamic pressure-forces for the detachment-process, the risk of ruptures is significantly lower and allows a minimal invasive transcrestal approach. The Sharpey-fibre-interface between the antral bone and the periosteum of the sinus-membrane will not be touched by the surgeon via the hand-instrument but detached by hydraulic/hydrodynamic pressure without any additional shear-forces (**Figure 8**).

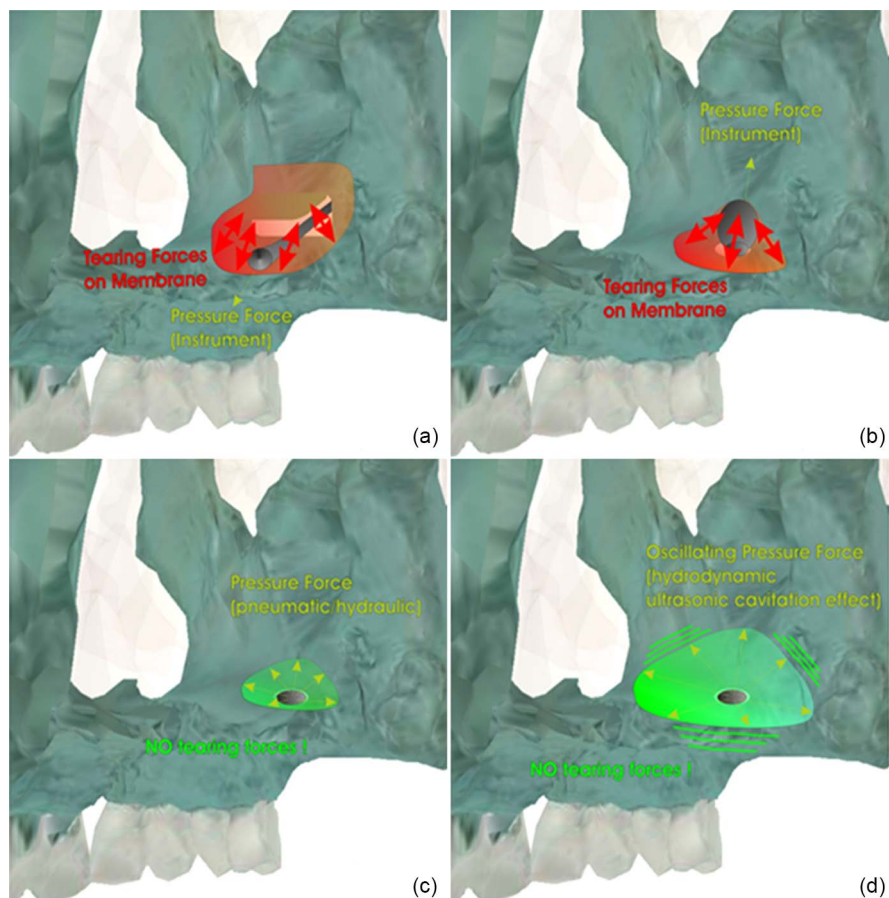


Figure 8. Schematic diagram of the tensile and shear forces acting on the sinus membrane with different surgical techniques (view from inside of the maxillary sinus): (a) Sinus lift by lateral window approach and sinus-membrane detachment by sharp or blunt hand instruments, (b) Summers-lift with transcrestal approach and sinus-membrane-detachment using osteotomes, (c) Sinus lift with transcrestal approach and hydraulic sinus-membrane-detachment, (d) Sinus lift with transcrestal approach and detachment by hydrodynamic-pressure and oscillating cavitation-effect.

Based on prior experimental studies [22] [23] the TKW Research Group 2006 defined the biomechanical parameters for a hydraulic sinus floor elevation procedure in experimental setups and further on developed the transcrestal hydrodynamic ultrasonic cavitation sinus lift (tHUCSL) [21]. This subsequently found many imitators who implemented the hydraulic or the ultrasonic transcrestal sinus lift based on the insights gained by the TKW Research Group in practice-applicable procedures, which have to be reviewed critically for their physical and biomechanical properties. Only systems which are approved for clinical use and which are documented by at least one published “proof of concept” study in an international review journal are discussed here.

4.2. Hydraulic Only Systems

4.2.1. Physiollift™ (Mectron/Italy)

The Physiollift™ is completely based on the published detailed experimental setup of the TKW Research Group [21] which they rejected to develop further into a device since clinical applicability is very limited. Ultrasonic surgical tips are used to open the sinus floor, one or two valve screws are inserted into the alveolar ridge and an undefined, not calibrated and uncontrollable hydraulic pressure is applied to the sinus membrane by means of a manual syringe in order to detach the membrane (**Figure 9**). In clinical application, the minimum subantral crest-height needs to be 4 mm or more—depending on the maxillary bone quality—to avoid the valve-screw(s) to break out of the bone by the weight of the attached tube-system, movements of the patients head or when manually too high hydraulic pressure is exerted. The minimum alveolar ridge width has to be 6 mm to allow a mechanical stable insertion of the valve-screws. If implants are inserted simultaneously, the implants need to have a minimum diameter of >3.5 mm. The hydraulic pressure cannot be controlled with accuracy or be calibrated, since the surgeons hand via a syringe applies it. Experimental studies indicate the achievable volume of subantral augmentation with this system to provide a

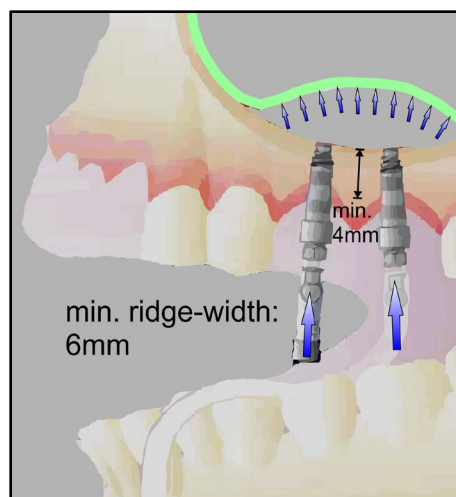


Figure 9. Schematic diagram of the hydraulic Physiollift™ procedure according to published information and depiction by the manufacturer.

maximum of 1 ccm, geometrically corresponding to an achievable augmentation-height of 4 - 5 mm [24]. The maximum possible subantral mesio-distal extension is reported to be the width of one molar [24]. To date, there is a complete lack of clinical studies on complication—and success rates, achievable augmentation volumes/heights and mesio-distal subantral extensions obtained in clinical application and learning efforts.

The advantage to prepare the transcresal approach with ultrasonic surgical instruments, which are known for their superior soft-tissue safety, is partly counteracted by the need to insert pressure-valves into the subantral bone and the use of non-controllable hydraulic lifting by means of a manual syringe, which makes this system challenging in inexperienced surgeons hands.

According to the results regarding subantral crest heights and mesio-distal sinus-extensions presented in the X-ray-study here, this system cannot be used in over 50% of cases because of the requirement of a minimum subantral crest height of 4 mm. The Physiollift™ may also be subject to a further restriction in its clinical applicability due to lateral atrophic narrow alveolar ridge-widths.

4.2.2. JEDER Lift (Jeder GmbH/Austria)

As the Physiollift™ the JEDER Lift is based on the precise experimental results of the TKW Research Group, too, but it takes a rather different approach. Instead of using ultrasonic surgical instruments, a transcresal trepanation is drilled with conventional drills in the subantral alveolar ridge, requiring a minimum depth of 2 - 3 mm and width of 4 mm. The transcresal trepanation is sealed by plugging a valve into the trepanation anchored only by friction (Physiollift™: screw-design). A 1.5 mm-diameter osteotome then is inserted into this sealing valve and used to open the maxillary sinus floor. The hydraulic pump-system then is attached to the valve inserted.

The applied hydraulic pressure of 1 bar (according to the parameters determined by the TKW Research Group [21]) is intended to detach the sinus membrane at the moment the bony antrum floor is opened, thereby minimising the risk of perforation. Since drills are used in this procedure, the risk of dissection or perforation of the sinus membrane generally cannot be avoided [18] (**Figure 7**).

The method claims the hydraulic pressure to be applied in pulses by means of an ultrasonic generator in the hydraulic pump, but the pulsation largely fails to achieve the desired effect due to the simple physical effects of the total elasticity of the silicone feed-tube-system used. To achieve the desired cavitation effect, a subantral inserted ultrasonic oscillating metal instrument would be needed (**Figure 10**).

The JEDER-lift system lacks specific product information regarding physical dimensions and a precise surgical protocol. The patent-specification indicates the subantral minimum bone height to be 4 - 6 mm and the ridge width 6 - 8 mm depending on the quality of the bone to allow the insertion of the sealing valve tightly into the alveolar ridge without risk of iatrogenic fractures of the

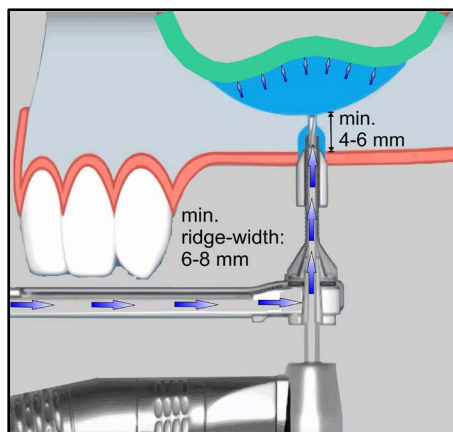


Figure 10. Schematic diagram of the hydraulic JEDER process according to published information and depiction by the manufacturer.

alveolar ridge, which would result in an abortion of the sinus-lift procedure. In case of simultaneous implant-insertion, implants need to have a minimum diameter of >4 mm. The tube system is a single-use, non-sterilisable disposable system.

No experimental studies were published for this system up to now proving the concept in controlled conditions. To date, only one clinical pilot study has been published with a very low number of patients and a perforation rate of 5% [25]. According to the pilot study, the average augmentation height obtained is 10 mm. It is not documented whether the entire maxillary sinus floor can be augmented with this system, as it would be necessary for patients with a completely edentulous maxilla.

According to the results regarding subantral crest heights and mesio-distal sinus-extensions presented in the X-ray-study here, the JEDER Lift System cannot be used in over 50% of cases (minimum subantral crest-height needed: 4 mm) or, if the bone quality is D3 or D4, in over 75% of cases, since 6 mm subantral ridge-heights are required for tight insertion of the pressure-valve in very soft maxillary bone. Furthermore, this system cannot be applied in cases of narrow single-tooth gaps due to the dimensions of the pressure-valve, counteracts the advantages of hydraulic sinus-membrane-detachment by the well-known dissection/perforation-risk of the sinus-membrane with drills and seems to challenge surgeons manually at the very first step of the surgery.

4.2.3. iRaise Sinus Lift Implant (Maxillent/Israel)

An interesting combination of the previous systems is the “iRaise” sinus lift implant. The implant presents a borehole in its side and a hollow channel perforating the apex of the implant. Therewith, the implant itself is used as a sealing valve to tight-seal the opened maxillary sinus floor. Flat burs, designed to minimise the risk of perforating the sinus-membrane when the maxillary sinus floor is opened, are used to drill a 4 mm wide trepanation and the implant, which is conical at the apex and has the smallest possible diameter of 4.2 mm, needs to be screwed in to a depth of at least 4 mm.

The borehole on the side of the implant then is coupled to a silicone tube. As with the Physiolift™-system the hydraulic pressure must be applied manually with a syringe operated “by touch”. After removal of the saline solution from underneath the hydraulically detached sinus-membrane, a fluid synthetic bone-graft is inserted subantral and the implant screwed in to its final position (**Figure 11**).

One major point of criticism concerning the use of this system in the clinical routine is the strong leverage-force exerted to the soft maxillary bone via the implant when connecting the silicone tube to the conical implant. The conical-shaped implant at this surgical step is inserted to a depth of only 4 mm and might achieve only very little primary stability. Even in the presence of (rarely encountered) bone quality D1, there is a considerable risk of the implant being levered out of the bone or of the bone fractured completely during the coupling-process of the silicone-tube. In this case, the entire surgical procedure and the placement of the implant has to be aborted. In order to achieve a sufficient primary stability of the iRaise-implant (smallest diameter available: 4.2 mm) in D3 bone, a ridge width of at least 6 - 8 mm must be available.

To date, only one clinical pilot-study with a small patient population is available for the iRaise system [26].

According to the results regarding subantral crest heights and mesio-distal sinus-extensions presented in the X-ray-study here, the iRaise sinus lift implant system cannot be used in 50% of cases in need of sinus lifting. The possible application to restore an entire edentulous maxilla or full molar and premolar quadrant with iRaise-implants is not reported and seems highly questionable.

4.3. Hydrodynamic Ultrasonic Systems

4.3.1 tHUCSL INTRALIFT (ACTEON/France)

Based on the experimental results of hydraulic sinus-lifting the TKW Research Group developed the world's first all-ultrasonic transcresal sinus lift system in 2006 and introduced it to clinical application in 2007 [27]. The TKW Research Group refused to transfer the experimental setup to a working device since the

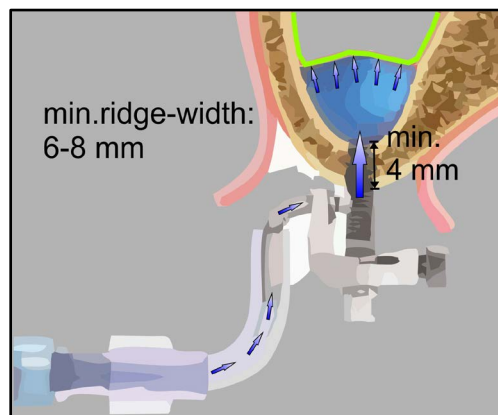


Figure 11. Schematic diagram of the hydraulic iRaise implant process according to published information and depiction by the manufacturer.

limited applicability in clinical-practice was obvious, as the Physiolift™ and the JEDER Lift demonstrate.

The INTRALIFT-system provides a precise surgical protocol: first, the transcresal access to the sinus membrane is prepared with diamond-coated ultrasonic tips (1.8 to 2.4 mm diameter) which harness the cavitation effect to remove and condense the subantral alveolar bone almost without direct mechanical contact. Unlike rotary instruments, which inhere a high risk of direct mechanical puncture or dissection/rupture of the sinus-membrane by shear- or tensile forces, a dissection or perforation of the membrane is very unlikely even if physical contact is made with the sinus membrane due to the cavitation effect building as gaseous cushion around the tip [28] (**Figure 12(a)**, **Figure 12(b)**). A flat diamond-coated ultrasonic tip (diameter 2.8 mm) is used to prepare the receptacle for the hydrodynamic cavitational sinus-membrane-detachment-tip. The hollow sinus-membrane-detachment-tip (diameter 3.0 mm) is then inserted tightly into the receptacle without physical contact to the sinus-membrane. After adjustment of the Piezotome-settings according to the precise surgical protocol provided, the calibrated hydraulic pump of the Piezotome-device provides the precise hydraulic pressure and together with the ultrasonic oscillations of the detachment-tip the necessary cavitation effect for a clean and undisrupted separation of the sinus-membranes periosteum from the bony antrum floor [28] (**Figure 12(c)**). The volume and height of the subantral scaffold is scalable by the duration of the applied hydrodynamic-cavitational detachment from small augmentations to the entire sinus-floor. The subantral osteotomy then is widened and compacted by the flat diamond-coated ultrasonic tip with 2.8 mm diameter to enable a stuck-free insertion of any preferred biomaterial (**Figure 12(d)-(g)**).

The minimum subantral bone-height-requirement is 1 mm and the minimum ridge width is 3 mm (**Figure 13**). Via the single 2.8 mm diameter transcresal access, the entire maxillary sinus floor from the 2nd molar to the canine fossa can be augmented with elevation heights of 15 mm (**Figure 12(e)-(h)**). Implants with a diameter of 3.5 mm and more can be inserted into the residual bone simultaneously or in a second surgery depending on the primary implant-stability the residual bone provides (**Figure 12(i)**, **Figure 12(j)**). Since INTRALIFT can be used already at a residual ridge height of only 1 mm, the INTRALIFT procedure can also be carried out paracrestally with a success rate of over 97%. Comparative clinical studies proved the INTRALIFT to achieve significant better results compared to traditional sinus lift methods [13].

It is essential to adhere strictly to the very simple INTRALIFT surgical protocol. Using burs instead of the provided diamond ultrasonic tips to open the maxillary sinus floor results in perforation-rates of 25% compared to 3% with ultrasonic tips and completely counteracts the safe and purely ultrasonic procedure as described in the surgical protocol [13] [36].

The tHUCSL INTRALIFT has been scientifically documented exhaustively and validated, both experimental [21] [29] and on histologic level [28], as well as

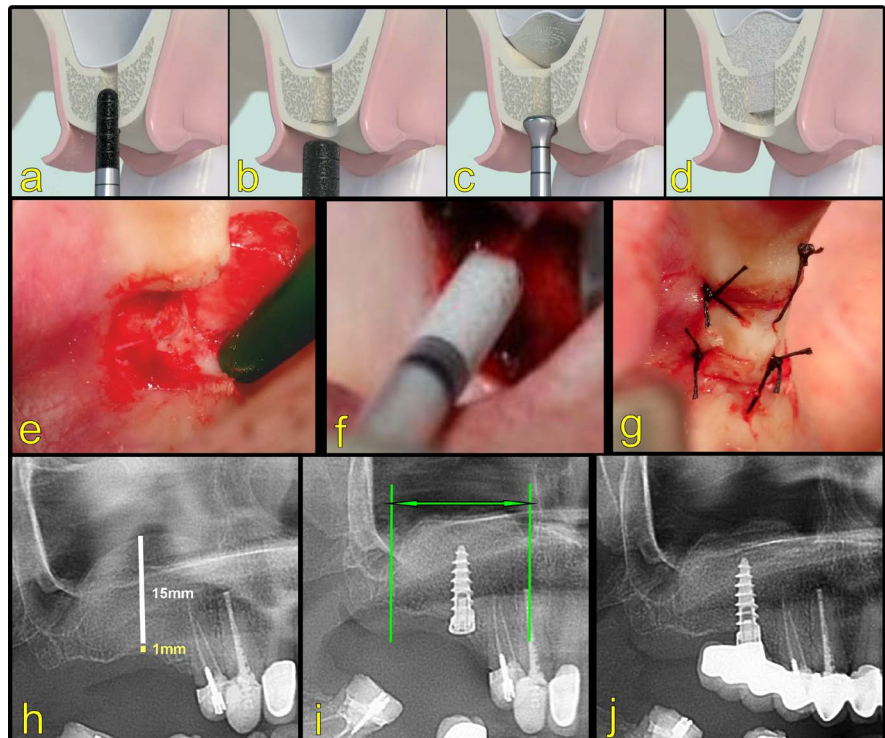


Figure 12. Schematic diagram of the hydrodynamic INTRALIFT-procedure optimised by the cavitation effect, according to published information by the manufacturer. Surgical protocol depicting the transcrestal approach with a rounded, diamond-coated ultrasonic tip (a), preparation of the receptacle (“valve-seat”) with a flat diamond-coated ultrasonic tip (b), non-dissecting hydrodynamic elevation of the sinus membrane, optimised by the ultrasonic cavitation effect (c), insertion of the graft material in any required quantity and extension (d). Clinical example of a transcrestal hydrodynamic ultrasonic cavitation sinus lift (INTRALIFT): minimal invasive crestal mucoperiosteal flap (e), insertion of the graft material (f), wound-closure (g); post-surgical radiographic control (h), X-ray control after insertion of implant 6 months post INTRALIFT (the entire maxillary sinus antrum was augmented during the first surgery to avoid additional sinus-lifts for possible insertion of subsequent implants (green markings)) (i), radiographic control after prosthetic treatment 9 months after INTRALIFT. (Image supplied by TKW Research Group).

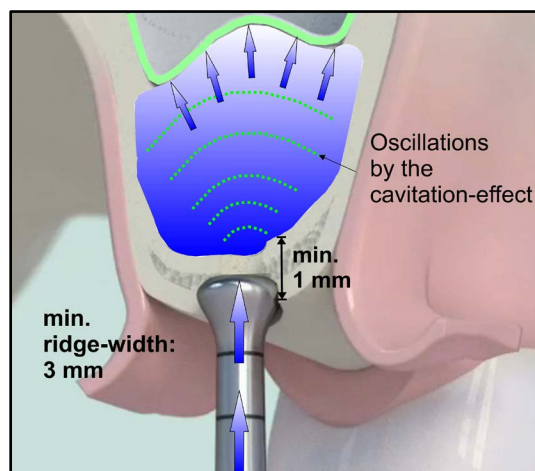


Figure 13. Schematic diagram of the INTRALIFT hydrodynamic cavitation procedure according to published information and depiction by the manufacturer.

in clinical studies [13] [17] and in prospective multicentre studies [30] [31] [32] [33] [34]. It is now regarded as the standard procedure of choice in clinical bio-material research for obtaining results that must not be affected by the surgical procedure [12] [17] [35]. The method is easy to learn with courses offered worldwide, and online training opportunities are available at any time.

According to the results regarding subantral crest heights and mesio-distal sinus-extensions presented in the X-ray-study here, the INTRALIFT procedure can be used in 100% of cases in a practitioners office.

4.3.2. HPISE Sinus Lift (Silfradent/Italy)

The HPISE Sinus Lift, which was introduced in 2010, represents a combined method of preparing the access to the sinus membrane using a screw-osteotome and detaching the sinus membrane with an ultrasonic tip similar to the INTRALIFT-tip.

The 2.8 mm diameter ultrasonic tip must be inserted into the subantral alveolar ridge to a depth of at least 4 mm in order to seal the borehole partially. According to the surgical protocol provided by the manufacturer, it is essential to provide a secondary transcresal access to serve as a pressure-release valve, since the ultrasonic surgery unit cannot control the hydraulic pressure and the sinus membrane could be ruptured by the effect of excessive hydraulic pressure. There is no scientific documentation whether an ultrasonic cavitation effect occurs at the end of the tip or if the sinus membrane can be detached without dissection. It seems physically doubtful, since the ultrasonic detachment tip must be pressed very firmly into the alveolar ridge in order to tight-seal the transcresal osteotomy, thus inhibiting the ultrasonic oscillations, which are essential to the cavitation effect (Figure 14).

The minimum subantral bone height for the HPISE-procedure is 4 mm, the minimum ridge width 5 mm, and the minimum diameter of the implants for simultaneous implant insertion is 3.5 mm. Augmentation of the entire maxillary sinus antrum is possible, but no studies are available on the achievable augmentation heights.

No experimental studies have been published on the HPISE sinus lift; only clinical studies by a single group of authors are available [37] [38].

According to the results regarding subantral crest heights and mesio-distal sinus-extensions presented in the X-ray-study here, the HPISE sinus lift procedure cannot be used in 50% of a practitioners patient-sample in need of sinus-lifting.

4.3.3. NSK Socket Lift (NSK/Japan)

The ultrasonic NSK socket lift system is a direct copy of the INTRALIFT system. The main difference to the INTRALIFT system is the requirement of a minimum subantral bone height of 5 mm as described by the manufacturer and it acts less by applying hydraulic pressure and the cavitation effect (the ultrasonic elevation tip does not seal the crestal approach like a valve), than by mechanically detaching the sinus membrane (Figure 15).

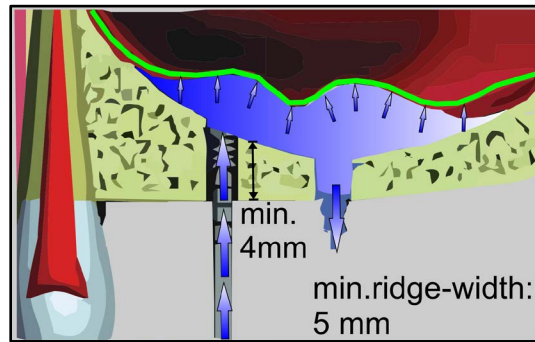


Figure 14. Schematic diagram of the HPISE hydrodynamic procedure according to published information and depiction by the manufacturer.

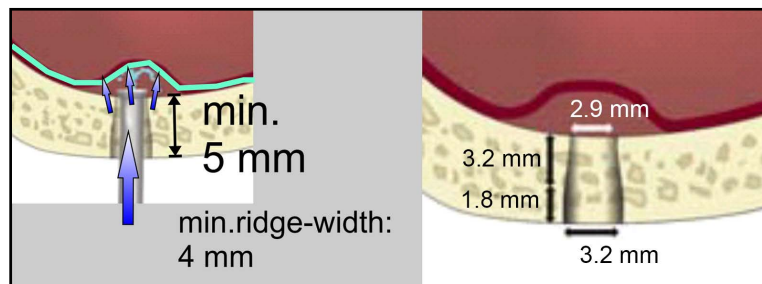


Figure 15. Schematic diagram of the NSK Socket Lift hydrodynamic process according to published information and depiction by the manufacturer.

No scientific documentation on perforation rates or case studies exist for this system, so there is no information concerning which elevation heights and widths can be achieved. Implants can be inserted simultaneously starting from diameters of 3.5 mm.

According to the results regarding subantral crest heights and mesio-distal sinus-extensions presented in the X-ray-study here, the NSK socket lift procedure cannot be used in over 50% of patients in need of sinus-lifting.

4.3.4. Sinus Piezo Lift (Mectron/Italy)

Another copy of the INTRALIFT procedure was introduced by the end of 2015. According to the recommended protocol, the surgical procedure for the ultrasonic Sinus Piezo Lift begins with a spherical diamond ultrasonic tip, followed by the expansion of the transcrestal access channel with a cylindrical diamond tip with a diameter of 3.5 mm. The maxillary sinus floor is opened with a spherical diamond tip (diameter 1.5 mm). As there is no direction-guide for the spherical tip on the lateral bone walls, the bony maxillary sinus floor cannot be opened with geometrical precision. Therefore, it seems doubtful if the piston-like sinus-membrane-detachment-tip can be seated tight-sealed properly in every surgical procedure to enable a controlled hydraulic pressure-rise under the sinus-membrane. The sinus membrane then is detached mainly by hydraulic pressure since the oscillations of the cylindrical and diamond-coated tip (and consequently the essential cavitation effect) are counteracted by the need to firmly insert the piston-like tip into the borehole, which might block proper os-

cillations. The surgical protocol does not document any proper form of hydraulic pressure regulation when detaching the sinus membrane (in order to avoid perforations caused by excess pressure). (**Figure 16**) Subsequently a biomaterial of choice is inserted subantrally and if desired, an implant with a minimum diameter of 3.8 mm can be inserted.

There is no scientific documentation for this system and no case studies or clinical studies are available concerning the achievable augmentation heights and mesio-distal extensions or perforation rates.

According to the results regarding subantral crest heights and mesio-distal sinus-extensions presented in the X-ray-study here, the sinus piezo lift procedure cannot be used in over 50% of patients in need of sinus-lifting.

Table 2 summarises the indications for all systems presented.

5. Conclusions

The results of the representative maxillary sinus measurement study suggest the sinus lift procedure to remain an essential part of the standard surgical repertoire of practice-based implantologists in order to avoid the need to transfer nearly 60% of patients in need of implants in the maxillary posterior region to another oral surgeon for sinus augmentation surgery.

Piezotome-surgery is established as the new standard of bone-cutting in general oral surgery. This applies to sinus lift procedures in particular, since it has been proven that piezotome surgery, unlike the use of rotary instruments and drills, provides an ideal safeguard against intraoperative iatrogenic perforation of the sinus membrane.

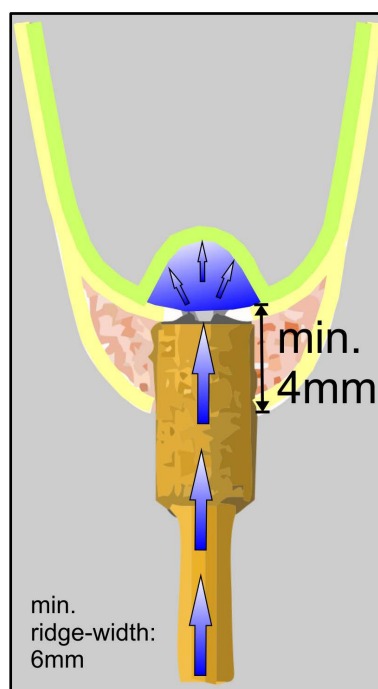


Figure 16. Schematic diagram of the Sinus Piezo Lift hydrodynamic process according to published information and depiction by the manufacturer.

Table 2. List of the features, indications and applicability of the transcrestal approach hydraulic/hydrodynamic sinus lift procedures in daily practice in correlation with the results of the alveolar ridge N-ray measurement study.

System comparison	Preparation of access		Membrane detachment		Min. subantral ridge height				Minimum width				Minimum diameter		Achievable augm. height		Mesio-distal expansion		Indication according to study	
	Burr	Ultrasonic	Hydraulic	Calibrated hydraulic	Ultrasonic	Cacitation effect	≤2 mm	≤4 mm	≤6 mm	≤8 mm	≤4 mm	≤5 mm	≤6 mm	≤10 mm	≤15 mm	Single tooth	Entire antrum	≤50%	≤100%	
Physiolift	N	Y	Y	N	N	N	N	Y	Y	Y	Y	Y	Y	N	N	Y	N	Y	N	
JEDER Lift	Y	N		Y	N	N	N	Y	Y	Y	N	Y	Y	Y	N	Y	N	Y	N	
iRaise Implant	Y	N	Y	N	N	N	N	Y	Y	Y	N	Y	Y	N	N	Y	N	Y	N	
INTRALIFT	N	Y		Y	Y	Y	Y	Y	Y	Y	Y	Y	Y	Y	Y	Y	Y		Y	
HP/ISE	Y	N	Y	N	Y	?	N	Y	Y	Y	N	Y	Y	N	N	Y	Y	Y	N	
NSK Socket Lift	N	Y		N	N	?	N	N	Y	Y	Y	Y	?	?	?	Y	?	Y	N	
Sinus Piezo Lift	N	Y		N	Y	?	N	Y	Y	Y	N	Y	?	?	?	Y	?	Y	N	

Since it is now possible to augment the entire maxillary sinus via a single transcrestal approach, transcrestal sinus lifting might be the preferred procedure avoiding postsurgical morbidity, even if surgery is not successful.

In order to ensure that the periosteum of the sinus-membrane remains intact when detached and to prevent any dissection of the sinus membrane during detachment, inexpert practice-based dentists (and also expert oral surgeons and implantologists) should give preference to ultrasonic tips rather than burs. The use of a precise, pressure-controlled hydrodynamic ultrasonic cavitation sinus-lift system seems to provide overall higher success and lower complication rates.

When choosing an ultrasonic surgical unit in general or specifically for transcrestal sinus lift surgery, a system should be selected providing an unrestricted applicability with well-founded scientific background and clinical proof of safety and reliability.

References

- [1] Müller, F., Manuel, N. and Carlsson, G.E. (2007) What Are the Prevalence and Incidence of Tooth Loss in the Adult and Elderly Population in Europe? *Clinical oral implants research*, **18**, 2-14. <https://doi.org/10.1111/j.1600-0501.2007.01459.x>
- [2] Smiler, D.G. (1997) The Sinus Lift Graft: Basic Technique and Variations. *Practical Periodontics and Aesthetic Dentistry*, **9**, 885-893.
- [3] Bozkaya, D. and Müftü, S. (2003) Mechanics of the Tapered Interference Fit in Dental Implants. *Journal of Biomechanics*, **36**, 1649-1658. [https://doi.org/10.1016/S0021-9290\(03\)00177-5](https://doi.org/10.1016/S0021-9290(03)00177-5)
- [4] Bozkaya, D., Muftu, S. and Muftu, A. (2004) Evaluation of Load Transfer Characteristics of Five Different Implants in Compact Bone at Different Load Levels by Finite Elements Analysis. *The Journal of Prosthetic Dentistry*, **92**, 523-530. <https://doi.org/10.1016/j.prosdent.2004.07.024>
- [5] Baggi, L., Cappelloni, I., Di Girolamo, M., Maceri, F. and Vairo, G. (2008) The Influence of Implant Diameter and Length on Stress Distribution of Osseointegrated Implants Related to Crestal Bone Geometry: A Three-Dimensional Finite Element Analysis. *The Journal of Prosthetic Dentistry*, **100**, 422-431. [https://doi.org/10.1016/S0022-3913\(08\)60259-0](https://doi.org/10.1016/S0022-3913(08)60259-0)
- [6] Oh, T.J., Yoon, J., Misch, C.E. and Wang, H.L. (2002) The Causes of Early Implant Bone Loss: Myth or Science. *Journal of Periodontology*, **73**, 322-333. <https://doi.org/10.1902/jop.2002.73.3.322>
- [7] Koldslund, O.C., Scheie, A.A. and Aass, A.M. (2010) Prevalence of Peri-Implantitis Related to Severity of the Disease with Different Degrees of Bone Loss. *Journal of periodontology*, **81**, 231-238. <https://doi.org/10.1902/jop.2009.090269>
- [8] Menchero-Cantalejo, E., Barona-Dorado, C., Cantero-Álvarez, M., Fernández-Cáliz, F. and Martínez-González, J.M. (2011) Meta-Analysis on the Survival of Short Implants. *Medicina Oral, Patología Oral y Cirugía Bucal*, **16**, e546-e551. <https://doi.org/10.4317/medoral.16.e546>
- [9] Kotsovilis, S., Fourmoussis, I., Karoussis, I. K. and Bamia, C. (2009) A Systematic Review and Meta-Analysis on the Effect of Implant Length on the Survival of Rough-Surface Dental Implants. *Journal of Periodontology*, **80**, 1700-1718. <https://doi.org/10.1902/jop.2009.090107>
- [10] Hagi, D., Deporter, D.A., Pilliar, R.M. and Arenovich, T. (2004) A Targeted Review of Study Outcomes with Short (≤ 7 mm) Endosseous Dental Implants Placed in

- Partially Edentulous Patients. *Journal of Periodontology*, **75**, 798-804.
<https://doi.org/10.1902/jop.2004.75.6.798>
- [11] Morand, M. and Irinakis, T. (2007) The Challenge of Implant Therapy in the Posterior Maxilla: Providing a Rationale for the Use of Short Implants. *Journal of Oral Implantology*, **33**, 257-266.
[https://doi.org/10.1563/1548-1336\(2007\)33\[257:TCOITI\]2.0.CO;2](https://doi.org/10.1563/1548-1336(2007)33[257:TCOITI]2.0.CO;2)
 - [12] Angelo, T., Marcel, W., Andreas, K. and Izabela, S. (2015) Biomechanical Stability of Dental Implants in Augmented Maxillary Sites: Results of a Randomized Clinical Study with Four Different Biomaterials and PRF and a Biological View on Guided Bone Regeneration. *BioMed Research International*, **2015**, Article ID: 850340.
<https://doi.org/10.1155/2015/850340>
 - [13] Troedhan, A., Kurrek, A., Wainwright, M., Schlichting, I., Fischak-Treitl, B. and Ladentrog, M. (2013) The Transcrestal Hydrodynamic Ultrasonic Cavitation Sinuslift: Results of a 2-Year Prospective Multicentre Study on 404 Patients, 446 Sinuslift Sites and 637 Inserted Implants. *Open Journal of Stomatology*, **3**, 471-485.
<https://doi.org/10.4236/ojst.2013.39078>
 - [14] Nolan, P.J., Freeman, K. and Kraut, R.A. (2014) Correlation between Schneiderian Membrane Perforation and Sinus Lift Graft Outcome: A Retrospective Evaluation of 359 Augmented Sinus. *Journal of Oral and Maxillofacial Surgery*, **72**, 47-52.
<https://doi.org/10.1016/j.joms.2013.07.020>
 - [15] Vazquez, J.C.M., de Rivera, A.S.G., Gil, H.S. and Mifsut, R.S. (2014) Complication Rate in 200 Consecutive Sinus Lift Procedures: Guidelines for Prevention and Treatment. *Journal of Oral and Maxillofacial Surgery*, **72**, 892-901.
<https://doi.org/10.1016/j.joms.2013.11.023>
 - [16] Hernández-Alfaro, F., Torradeflot, M.M. and Marti, C. (2008) Prevalence and Management of Schneiderian Membrane Perforations during Sinus-Lift Procedures. *Clinical Oral Implants Research*, **19**, 91-98.
 - [17] Troedhan, A., Kurrek, A. and Wainwright, M. (2012) Biological Principles and Physiology of Bone Regeneration under the Schneiderian Membrane after Sinus Lift Surgery: A Radiological Study in 14 Patients Treated with the Transcrestal Hydrodynamic Ultrasonic Cavitation Sinus Lift (Intralift). *International Journal of Dentistry*, **2012**, Article ID: 576238. <https://doi.org/10.1155/2012/576238>
 - [18] Stelzle, F. and Benner, K.U. (2011) Evaluation of Different Methods of Indirect Sinus Floor Elevation for Elevation Heights of 10 mm: An Experimental *ex Vivo* Study. *Clinical Implant Dentistry and Related Research*, **13**, 124-133.
<https://doi.org/10.1111/j.1708-8208.2009.00190.x>
 - [19] Cases, C. (2007) Schneiderian Membrane Perforation Rate during Sinus Elevation Using Piezosurgery: Clinical Results of 100 Consecutive Cases. *International Journal of Periodontics and Restorative Dentistry*, **27**, 413-419.
 - [20] Seoane, J., López-Niño, J., García-Caballero, L., Seoane-Romero, J.M., Tomás, I. and Varela-Centelles, P. (2013) Membrane Perforation in Sinus Floor Elevation-Piezoelectric Device versus Conventional Rotary Instruments for Osteotomy: An Experimental Study. *Clinical Implant Dentistry and Related Research*, **15**, 867-873.
<https://doi.org/10.1111/j.1708-8208.2012.00447.x>
 - [21] Troedhan, A.C., Kurrek, A., Wainwright, M. and Jank, S. (2010) Hydrodynamic Ultrasonic Sinus Floor Elevation—An Experimental Study in Sheep. *Journal of Oral and Maxillofacial Surgery*, **68**, 1125-1130.
<https://doi.org/10.1016/j.joms.2009.12.014>
 - [22] Vitkov, L., Gellrich, N.C. and Hannig, M. (2005) Sinus Floor Elevation via hydraulic Detachment and Elevation of the Schneiderian Membrane. *Clinical Oral Im-*

- plants Research*, **16**, 615-621. <https://doi.org/10.1111/j.1600-0501.2005.01161.x>
- [23] Sotirakis, E.G. and Gonshor, A. (2005) Elevation of the Maxillary Sinus Floor with Hydraulic Pressure. *Journal of Oral Implantology*, **31**, 197-204. [https://doi.org/10.1563/1548-1336\(2005\)31\[197:EOTMSF\]2.0.CO;2](https://doi.org/10.1563/1548-1336(2005)31[197:EOTMSF]2.0.CO;2)
- [24] Kühl, S., Kirmeier, R., Platzer, S., Bianco, N., Jakse, N. and Payer, M. (2016) Transcrestal Maxillary Sinus Augmentation: Summers' versus a Piezoelectric Technique—An Experimental Cadaver Study. *Clinical Oral Implants Research*, **27**, 126-129. <https://doi.org/10.1111/clr.12546>
- [25] Jesch, P., Bruckmoser, E., Bayerle, A., Eder, K., Bayerle-Eder, M. and Watzinger, F. (2013) A Pilot-Study of a Minimally Invasive Technique to Elevate the Sinus Floor Membrane and Place Graft for Augmentation Using High Hydraulic Pressure: 18-Month Follow-Up of 20 Cases. *Oral Surgery, Oral Medicine, Oral Pathology and Oral Radiology*, **116**, 293-300. <https://doi.org/10.1016/j.oooo.2013.05.014>
- [26] Better, H., Slavescu, D., Barbu, H., Cochran, D.L. and Chaushu, G. (2014) Minimally Invasive Sinus Lift Implant Device: A Multicenter Safety and Efficacy Trial Preliminary Results. *Clinical Implant Dentistry and Related Research*, **16**, 520-526. <https://doi.org/10.1111/cid.12021>
- [27] Wainwright, M., Troedhan, A., Kurrek, A. (2007) The IntraLift™: A New Minimal Invasive Ultrasonic Technique for Sinus Grafting Procedures. *Implants*, **3**, 30-34.
- [28] Troedhan, A., Kurrek, A., Wainwright, M. and Jank, S. (2014) Schneiderian Membrane Detachment Using Transcrestal Hydrodynamic Ultrasonic Cavitation Sinus Lift: A Human Cadaver Head Study and Histologic Analysis. *Journal of Oral and Maxillofacial Surgery*, **72**, 1503.e1-1503.e10. <https://doi.org/10.1016/j.joms.2014.02.021>
- [29] Jank, S., Kurrek, A., Wainwright, M., Bek, V.E. and Troedhan, A. (2011) Rupture Length of the Sinus Membrane after 1.2 mm Puncture and Surgical Sinus Elevation: An Experimental Animal Cadaver Study. *Oral Surgery, Oral Medicine, Oral Pathology, Oral Radiology, and Endodontology*, **112**, 568-572. <https://doi.org/10.1016/j.tripleo.2010.11.014>
- [30] Velázquez-Cayón, R., Romero-Ruiz, M.M., Torres-Lagares, D., Pérez-Dorao, B., Wainwright, M., Abalos-Labruzzi, C. and Gutiérrez-Pérez, J.L. (2012) Hydrodynamic Ultrasonic Maxillary Sinus Lift: Review of a New Technique and Presentation of a Clinical Case. *Medicina Oral, Patología Oral y Cirugía Bucal*, **17**, e271-e275. <https://doi.org/10.4317/medoral.17430>
- [31] Wainwright, M., Torres-Lagares, D., Pérez-Dorao, B., Serrera-Figallo, M.A., Gutiérrez-Pérez, J.L., Troedhan, A. and Kurrek, A. (2016) Histological and Histomorphometric Study Using an Ultrasonic Crestal Sinus Grafting Procedure. A Multicenter Case Study. *Medicina Oral, Patología Oral y Cirugía Bucal*, **21**, e367-e373. <https://doi.org/10.4317/medoral.20994>
- [32] Abadzhiev, M. (2009) Alternative Sinus Lift Techniques Literature Review. *Journal of IMAB*, **16**, 23-27.
- [33] Ravichandran, D. (2013) Sinus Lift De-Mystified. *National Journal of Medical and Dental Research*, **1**, 61-64.
- [34] Llopet, J., Montaudon, M., Guillaud, E. and Ella, B. (2014) Comparison of 2 Crestal Sinus Floor Lift Techniques Performed on Human Cadavers. *Implant Dentistry*, **23**, 626-632. <https://doi.org/10.1097/id.0000000000000143>
- [35] Troedhan, A., Schlichting, I., Kurrek, A. and Wainwright, M. (2014) Primary Implant Stability in Augmented Sinuslift-Sites after Completed Bone Regeneration: A Randomized Controlled Clinical Study Comparing Four Subantrally Inserted Biomaterials. *Scientific Reports*, **4**, 5877. <https://doi.org/10.1038/srep05877>

- [36] Scheiderbauer, G.C. (2012) Hydrodynamischer Sinuslift Mit Augmentation und Implantation. *Zeitschrift für Zahnärztliche Implantologie*, **4**, 314-324.
- [37] Kim, J.M., Sohn, D.S., Heo, J.U., Park, J.S., Jung, H.S., Moon, J.W., Park, I.S., *et al.* (2012) Minimally Invasive Sinus Augmentation Using Ultrasonic Piezoelectric Vibration and Hydraulic Pressure: A Multicenter Retrospective Study. *Implant Dentistry*, **21**, 536-542.
- [38] Kim, J.M., Sohn, D.S., Bae, M.S., Moon, J.W., Lee, J.H. and Park, I.S. (2014) Flapless Transcrestal Sinus Augmentation Using Hydrodynamic Piezoelectric Internal Sinus Elevation with Autologous Concentrated Growth Factors Alone. *Implant Dentistry*, **23**, 168-174. <https://doi.org/10.1097/ID.0000000000000053>



Scientific Research Publishing

Submit or recommend next manuscript to SCIRP and we will provide best service for you:

Accepting pre-submission inquiries through Email, Facebook, LinkedIn, Twitter, etc.

A wide selection of journals (inclusive of 9 subjects, more than 200 journals)

Providing 24-hour high-quality service

User-friendly online submission system

Fair and swift peer-review system

Efficient typesetting and proofreading procedure

Display of the result of downloads and visits, as well as the number of cited articles

Maximum dissemination of your research work

Submit your manuscript at: <http://papersubmission.scirp.org/>

Or contact ojst@scirp.org

