

# Duodenal Atresia-Tandler's "Epithelial Plug Stage" Revisited

Ralf-Bodo Tröbs

Department of Pediatric Surgery, St. Marie's Hospital, Saint Elisabeth Group, Ruhr University of Bochum, Witten, Germany

Email: troebbs@icloud.com

**How to cite this paper:** Tröbs, R.-B. (2019) Duodenal Atresia-Tandler's "Epithelial Plug Stage" Revisited. *Open Journal of Pediatrics*, 9, 103-110.

<https://doi.org/10.4236/ojped.2019.91010>

**Received:** February 22, 2019

**Accepted:** March 25, 2019

**Published:** March 28, 2019

Copyright © 2019 by author(s) and Scientific Research Publishing Inc.

This work is licensed under the Creative

Commons Attribution International

License (CC BY 4.0).

<http://creativecommons.org/licenses/by/4.0/>



Open Access

## Abstract

**Background:** Duodenal atresia is the most common type of intestinal atresia. Pathogenesis of duodenal atresia can be explained by an embryological theory that involves persistent physiologic epithelial occlusion ("epithelial plug"), first published in 1900. *Tandler's* developmental arrest theory has been accepted by the majority of recognized modern textbooks to date. The aim of the presented study is to re-evaluate the relevance of Tandler's observations. **Method:** Tandler's paper was reviewed retrospectively and discussed from the point of view of subsequent research. **Results and Discussion:** Local epithelial proliferation, vacuolization failure and mesenchyme ingrowth may continuously serve as a partly convincing but incomplete embryologic model to explain membranous duodenal atresia. Tandler's theory has some weak points regarding the epithelial-mesenchymal interaction, the predisposition of the post-ampullary region, the association of duodenal atresia with other malformations and trisomy 21, and familial occurrence. Shrinkage artifacts, misinterpretation of a three-dimensional problem investigated with a two-dimensional tool (light microscope), animal studies, and the lack of apoptosis call the real existence of a solid stage in early duodenal embryology into question. **Conclusion:** More sophisticated morphologic, genetic and molecular-biological investigations revealed new insights regarding endoderm to mesoderm signaling as an important key to the pathogenesis of duodenal atresia.

## Keywords

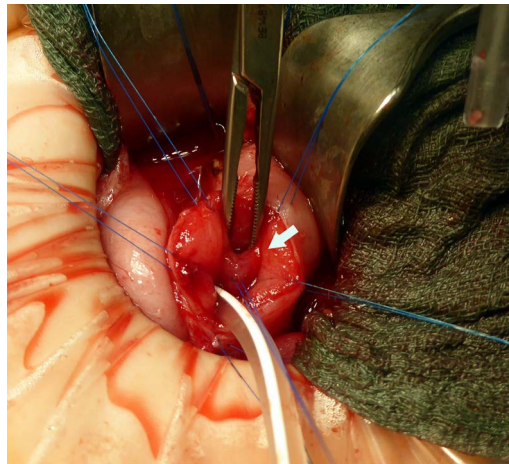
Duodenal Atresia, Embryology, Epithelial Plug, Tandler's Theory

## 1. Introduction

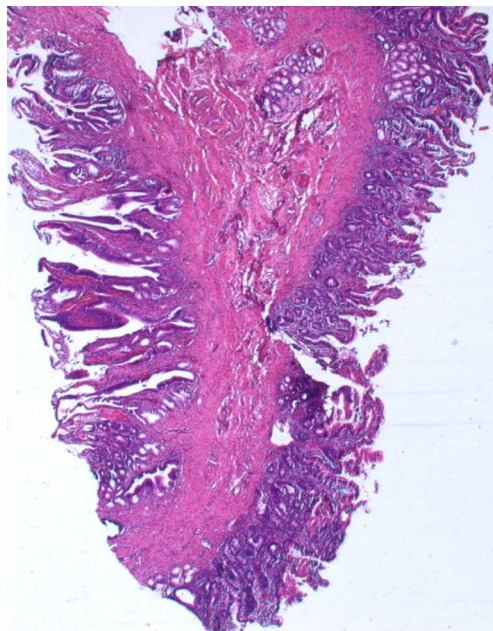
Duodenal atresia is the most common intestinal atresia with a prevalence of 0.9 per 10,000 births. The pathogenesis of duodenal atresia has been a matter of de-

bate for over 125 years. Until Tandler's report in 1902, theories were mainly based on the assumption that intestinal atresia would generally result from late *fetal* intrauterine events or "catastrophes" [1].

Bilious vomiting soon after birth is the leading symptom of duodenal atresia given that the blockage is located at the level of or below the hepatopancreatic ampulla [2]. Membranous obstruction (duodenal septum, web or diaphragm) is noted in 9 of 10 cases. No interruption of the duodenal wall is noted in this type, and the membrane may be solid or perforated (Figure 1 and Figure 2). The



**Figure 1.** Intraoperative appearance of a duodenal membrane (arrow). The second part of the duodenum is opened longitudinally (with permission from Thieme, Stuttgart [15]).



**Figure 2.** Histological section of a duodenal membrane of the duodenum (H&E,  $\times 25$ ). Epithelial lining, fibrous stroma, and Brunner's glands.

microscopic appearance of this septum does not differ from that of a Kerkring's fold. In segmental forms of duodenal atresia, a fibrous cord connects the two blind segments of the duodenum, or no connection exists.

Calder described the first case of congenital duodenal obstruction in 1733, and Vidal reported the first successful treatment by gastrointestinal bypass anastomosis in 1905. Sutton (1898) formulated the hypothesis that "congenital obstruction... of the alimentary canal is always found in the context of embryological events" [2].

Persistence of the temporary embryonic epithelial occlusion of the duodenum serves as an explanation for the pathogenesis of duodenal atresia. Tandler's developmental arrest theory was an outstanding hypothesis that was accepted by the scientific community of his time.

Since then, Tandler's theory has been the object of scientific debate and research, and the advantages and limits of this theory should be elucidated. In addition, the suitability of the epithelial plug theory to explain atresia of other parts of the gastrointestinal tract should also be discussed.

## 2. Material and Method

Tandler's paper was reviewed retrospectively and discussed from the point of view of subsequent research.

## 3. Results

Tandler's paper "Developmental history of the human duodenum during early embryological stages" serves as an example of scientific networking at the beginning of the last century [1]. Well established anatomists, including Zuckerkandl, Hochstetter, and Kollmann, contributed specimens to the study. Tandler examined histological sections of 7 human embryos with a body length between 7 and 21.6 mm. Near total or total epithelial occlusion of the duodenal lumen was present in embryos of 12.5, 14.5, and 15 mm length. Then, epithelial occlusion recanalization occurred. Furthermore, Tandler described a cranio-caudal direction of epithelial and mesenchymal proliferation and a delayed increase in the diameter of the duodenal tube during subsequent development. In addition, he reported closely comparable duodenal embryology in rats and guinea pigs. However, the latter observations are not reported in detail. Furthermore, Tandler compared his observations with earlier observations regarding the pathogenesis of jejunoileal atresia, and fetal intrauterine events, such as torsion of the bowel, embryonic ligamentous residuals, fetal peritonitis, and vascular thrombosis, seemed to be causative [3]. Tandler concluded that a failure of physiologic recanalization of the duodenum might be the most likely mechanism for the pathogenesis of duodenal atresia.

In his outstanding textbook, Bromann (1911) described the existence of a temporary "physiologic duodenal atresia" in human embryos of 12 to 14 mm length. Duodenal atresia was explained as the persistence of epithelium with

mesenchymal “growing-through” [4].

Sixty years after Tandler’s work, the *developmental arrest theory* for duodenal atresia was questioned by Lynn and Espinas (1959) [5]. In this study, plugging and/or vacuolation of the duodenal region was seen in less than one third of embryos in the 5- to 8-week age group. Furthermore, epithelial proliferation and plugging of the colon was found in the vast majority of embryos. They added the opinion that “many other processes may be of equal or even greater importance” for the pathogenesis of intestinal atresia.

An extensive human embryologic investigation was performed by Moutsouris (1966), who confirmed epithelial proliferation during the 6<sup>th</sup> and 7<sup>th</sup> weeks but never identified complete occlusion without vacuolization [6]. This author concluded that true plugging of the lumen, if it occurs at all, must be a rare phenomenon confined to the duodenum. In contrast, Boyden *et al.* (1967) described an epithelial proliferation within the entire duodenum extending from the pylorus to the jejunum [2]. They assumed that an impaired embryologic formation of the pancreaticobiliary junction would induce the occurrence of duodenal atresia. Ando *et al.* (1999) continued to explain the formation of duodenal atresia as an impaired interaction between the pancreaticobiliary junction and vacuolization of the duodenum [7]. However, the importance of this theory remains unclear to date given that the majority of clinical cases with atresia are not associated with hepatobiliary anomalies. **Table 1** provides results from embryological studies made on *human* specimens.

In newer morphologic studies on the embryologic rat duodenum, complete closure of the duodenal lumen was not observed. Conventional microscopic examination in a series of fetal duodenal rat specimens revealed a maximum of narrowing on days 12 and 13. A solid core stage and vacuolization was not observed [8]. Computerized three-dimensional reconstruction revealed “the

**Table 1.** Important *human* studies regarding the epithelial plug theory.

Author	Number of specimens	Duodenal plug	Crown-Rump Length	Explanation for Atresia
Tandler, 1902 [1]	7 + 4 descriptions	Yes	12.5 to 15 mm	Persistence of epithelial plug
Lynn & Espinas, 1959 [5]	89	Plugging and/or vacuolation in less than one third of cases	7 to 59 mm	Epithelial proliferation simultaneously in the colon.
Moutsouris, 1966 [6]	70	No complete occlusion	7 to 40 mm	Never complete occlusion, always vacuolation
Boyden, <i>et al.</i> 1967 [2]	4	Epithelium fills or fills partially the lumen	9.5 to 25 mm	Induction of atresia due to impaired formation of the pancreaticobiliary junction

perviousness of the whole digestive tract, although sometimes the path is sinuous” [9]. These observations in rats led to the conclusion that a pure “solid core” stage described by Tandler does not exist during embryonic development.

In addition, the role of apoptosis during the development of rat and mouse duodenum was questioned [10]. It was hypothesized that apoptosis might be the cellular biological mechanism for “recanalization” of the temporarily occluded duodenum. However, researchers found out that this process in rats is not based on apoptosis of the epithelial plug but is simply the result of growth that predominantly involves the circumference of the duodenal wall.

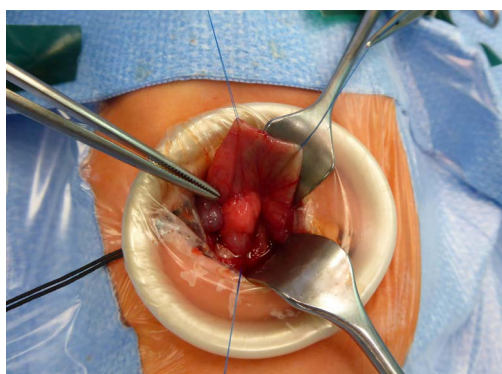
### 3.1. Application of Tandler’s Theory beside the Duodenum

Unlike duodenal atresia, membranes of the middle and lower gastrointestinal tract exist only in the minority of cases. Given that occasional light microscopic observations have demonstrated that the near solid stage or epithelial plug was not limited to the duodenum, selected cases of esophageal, gastric, ileal or colonic atresia might be explained as a failure to recanalize. Tandler’s theory seems not suitable to explain nonmembranous types of duodenal atresia with fibrous cord connection or gaps. In these cases, a duodenal maldevelopment secondary to extensive gut elongation that outpaces epithelial growth must be taken into account. Increased lengthwise intestinal growth occurs between weeks 4.5 to 12 in human embryos.

Annular pancreas (**Figure 3**) in association with intraluminal web or atresia is an common cause of congenital duodenal obstruction. Generally, it is not clear whether annular pancreas is a failure of duodenal development rather than a true constricting lesion. It is well accepted that failure during the embryonal rotation of the two primordia of the pancreas can result in the ventral anlage being drawn around the right side of the duodenum. During this process, the role of the epithelial plug stage remains questionable.

### 3.2. Genetic and Molecular Aspects

In addition to morphologic investigations, genetic and molecular science provides



**Figure 3.** Annular pancreas. Constriction of the second part of the duodenum (with permission from Thieme, Stuttgart [15]).

new insights into the pathogenesis of duodenal atresia. Approximately one-third of infants with duodenal atresia have trisomy 21. Congenital heart syndrome and malrotation of the gut are the most common accompanying malformations. Recurrence among siblings and among subsequent generations in one family suggests that genetic factors play a role. The role of teratogenic drugs, such as thalidomide, in the induction of duodenal atresia requires further investigation.

Recently, it has been discovered that Sonic hedgehog (*Shh*) and Indian hedgehog genes are involved in the interaction between intestinal endoderm and mesoderm. Individuals who are homozygous for a mutation in *Shh* presented a stenosis of the duodenum and developed a variant of anorectal malformation. The importance of an impaired “genetic transmissive factor” in the pathogenesis of intraluminal obstruction was discussed by Boyden *et al.* (1967) [2]. Some signalling molecules, such as sonic hedgehog and members of the fibroblast growth factor family (*FGF*) are positive regulators of growth in several developing organs. Mutations in the gene for fibroblast growth factor (FGF) receptor 2IIIb (*Fgfr2IIIb*) or the gene encoding its ligand *Fgf10* (fibroblast growth factor-10 (-/-) deficient mice) result in different types of both duodenal atresia and colonic atresia that are comparable to human forms [11]. The presence of in addition, mutations in the *Fgfr2* coding region in humans are associated with duodenal stenosis (Matthew-Wood syndrome) [12]. The association of duodenal atresia and/or annular pancreas with gall bladder hypoplasia, biliary atresia and diabetes was observed in a male infant with a biallelic mutation in the transcription factor *RFX66* [13].

### 3.3. Limitations of the Epithelial Plug Theory

The introduction of video microscopy and computerized image processing together with immunohistochemical, molecular and genetic methods have opened new horizons in recent decades. In contrast to Tandler’s observations, recent and more sophisticated embryological investigations on rats and mice performed during the last 20 years have not been able to confirm the existence of a solid stage during embryonic development [9].

However, Jirásek, (2004) stated that “the best model for human development is the human” [14].

## 4. Conclusion

Given that intestinal membranes consist of epithelial surfaces and an internal layer of connective tissue (mesenchymal origin) [Figure 1], persistence of the pure epithelial plug alone does not explain this morphology. Impaired epithelial-mesenchymal interaction must occur. In light of modern molecular biology, it seems probable that disruption in the endoderm and endoderm to mesoderm signaling plays a key role in the pathogenesis of duodenal atresia.

## Acknowledgements

Many thanks to Prof. Andrea Tannapfel and Dr. Matthias Neid (Department of

Pathology, Ruhr-University of Bochum) who provided **Figure 2**.

### Conflicts of Interest

The author has indicated he has no potential conflicts of interest to disclose.

### Financial Disclosure

The author has indicated he has no financial relationships relevant to this article to disclose.

### Funding

No external funding.

### References

- [1] Tandler, J. (1902) Zur Entwicklungsgeschichte des menschlichen Duodenum in frühen Embryonalstadien. *Morph Jahrb*, **29**, 187-216.
- [2] Boyden, E.A., Cope, J.G. and Bill, A.H. Jr. (1967) Anatomy and Embryology of Congenital Intrinsic Obstruction of the Duodenum. *The American Journal of Surgery*, **114**, 190-202. [https://doi.org/10.1016/0002-9610\(67\)90372-8](https://doi.org/10.1016/0002-9610(67)90372-8)
- [3] Louw, J.H. (1964) Investigations into the Etiology of Congenital Atresia of the Colon. *Diseases of the Colon & Rectum*, **7**, 741-748. <https://doi.org/10.1007/BF02616944>
- [4] Broman, I. (1911) Normale und abnorme Entwicklung des Menschen. Bergmann, Wiesbaden, 346-356. <https://doi.org/10.1007/978-3-642-51340-4>
- [5] Lynn, H.B. and Espinas, E.E. (1959) Intestinal Atresia. *The Archives of Surgery*, **79**, 357-361. <https://doi.org/10.1001/archsurg.1959.04320090005001>
- [6] Moutsouris, C. (1966) The "Solid Stage" and Congenital Intestinal Atresia. *Journal of Pediatric Surgery*, **1**, 446-450. [https://doi.org/10.1016/0022-3468\(66\)90132-1](https://doi.org/10.1016/0022-3468(66)90132-1)
- [7] Ando, H., Kaneko, K., Ito, F., *et al.* (1999) Embryogenesis of Pancreaticobiliary Maljunction Inferred from Development of Duodenal Atresia. *Journal of Hepato-Biliary-Pancreatic Surgery*, **6**, 50-54.
- [8] Cheng, W. and Tam, P.K. (1998) Murine Duodenum Does Not Go through a "Solid Core" Stage in Its Embryological Development. *European Journal of Pediatric Surgery*, **8**, 212-215. <https://doi.org/10.1055/s-2008-1071156>
- [9] Meio, I.B., Siviero, I., Ferrante, S.M.R., *et al.* (2008) Morphologic Study of Embryonic Development of Rat Duodenum through a Computerized Three-Dimensional Reconstruction: Critical Analysis of Solid Core Theory. *Pediatric Surgery International*, **24**, 561-565.
- [10] Cheng, W. and Tam, P.K.M. (2000) Apoptosis in Murine Duodenum during Embryonic Development. *Pediatric Surgery International*, **16**, 485-487. <https://doi.org/10.1007/s003830000408>
- [11] Kanard, R.C., Fairbanks, T.J., De Langhe, S.P., *et al.* (2005) Fibroblast Growth Factor 10 Serves a Regulatory Role in Duodenal Development. *Journal of Pediatric Surgery*, **40**, 313-316. <https://doi.org/10.1016/j.jpedsurg.2004.10.057>
- [12] Botham, R.A., Franco, M. and Zaremba, K.M. (2012) Formation of Duodenal Atresias in Fibroblast Growth Factor Receptor 2IIb<sup>-/-</sup>-Mouse Embryos Occurs in the Absence of an Endodermal Plug. *Journal of Pediatric Surgery*, **47**, 1369-1379.

<https://doi.org/10.1016/j.jpedsurg.2012.02.001>

- [13] Concepcion, J.P., Reh, C.S., Daniels, M., *et al.* (2014) Neonatal Diabetes, Gallbladder Agenesis, Duodenal Atresia, and Intestinal Malrotation Caused by a Novel Homozygous Mutation in *RFX6*. *Pediatric Diabetes*, **15**, 67-72.
- [14] Jirásek, J.E. (2004) *An Atlas of Human Prenatal Developmental Mechanics*. Taylor & Francis, London, IX.
- [15] Tröbs, R.B. (2019) *Gastrointestinal Malformations and Diseases of the Newborn*. German Language. *Neonatologie Scan*, 8. (In Press)