

Efficacy of Intravenous Immunoglobulin in a Case of Emanuel Syndrome

Yasuyo Kashiwagi*, Yasuyuki Morishima, Kazushi Agata, Soken Go, Shigeo Nishimata, Hironao Numabe, Hisashi Kawashima

Department of Pediatrics, Tokyo Medical University, Tokyo, Japan

Email: *hoyohoyo18@hotmail.com

How to cite this paper: Kashiwagi, Y., Morishima, Y., Agata, K., Go, S., Nishimata, S., Numabe, H. and Kawashima, H. (2017) Efficacy of Intravenous Immunoglobulin in a Case of Emanuel Syndrome. *Open Journal of Pediatrics*, 7, 32-36. <https://doi.org/10.4236/ojped.2017.71005>

Received: February 13, 2017

Accepted: March 6, 2017

Published: March 9, 2017

Copyright © 2017 by authors and Scientific Research Publishing Inc.

This work is licensed under the Creative Commons Attribution International License (CC BY 4.0).

<http://creativecommons.org/licenses/by/4.0/>



Open Access

Abstract

We report a case of a male patient with Emanuel syndrome (ES) with multiple systemic malformations. He had frequent recurrent seizures and infectious diseases after six months. Because the level of immunoglobulin (IgG) was below the normal range for his age, he was administered intravenous immunoglobulin (IVIG) whenever infection occurred. As he grew up, the frequency of infections and seizures were reduced after IVIG therapy. Although the mechanism was not identified, IVIG might be effective for not only recurrent infections, but also for reducing recurrent seizures.

Keywords

Emanuel Syndrome, IVIG

1. Introduction

Emanuel syndrome (ES) is a rare anomaly associated with multiple systemic malformations and is characterized by severe intellectual disability, microcephaly, failure to thrive, preauricular tags or pits, ear anomalies, cleft or high-arched palate, micrognathia, kidney abnormalities, congenital heart defects, and genital abnormalities in males. The frequency of ES has been reported as 1 in 110,000, and the estimated number of ES cases in Japan is 1063 [1].

Mental and developmental retardation are major clinical features. Treatment of manifestations and prevention of secondary complications are needed. Recurrent seizures and infections are complications in ES.

We report a case of ES treated with regular injections of intravenous immunoglobulin (IVIG) and review the literature about immunological status in ES. Informed consent was obtained from parental consent to report this case.

2. Case Report

A male infant was delivered at full term by vaginal delivery. Intracytoplasmic sperm injection (ICSI) had been performed; the antenatal period was uneventful. The birth weight was 3022 g, height was 48 cm, and head circumference was 32.5 cm. He had remarkable multiple congenital anomalies and craniofacial dysmorphism which involved ear pits, preauricular tags, Pierre Robin sequence, micrognathia, excess nuchal skin, and abnormalities in ear shape, size, and position. Hearing assessment revealed severe hearing loss. He also had a small penis. Echocardiography revealed atrial septal defect (ASD), ventricular septal defect (VSD), and pulmonary stenosis (PS). Karyotyping using SKY analysis showed 47, XY, +der(22)t(11;22)(q23.3;q11.2) (**Figure 1**). He was diagnosed with ES. Karyotyping for his parents was not performed (no consent). After he was born, he became bed-ridden because of hypoxia-related brain encephalopathy. Treatment of manifestations (gastro-esophageal reflux, cardiac defects, cleft palate, hearing loss, epilepsy, cryptorchidism, and micropenis) was performed by multidisciplinary teams. During the 5-year follow-up, he was found to have significant developmental delay. He had frequent recurrent seizures and infectious diseases after six months. **Figure 2** reveals the level of immunoglobulin (IgG) and the clinical course. As the level of endogenous IgG decreased over his first six months, he had frequent episodes of bronchitis and pneumonia and fistula formation by infections of the preauricular pits. Because the level of IgG was below the normal range for his age, he was administered IVIG (200 mg/kg) whenever an infection occurred. As he grew up, the frequency of infections and seizures were reduced after IVIG therapy.

3. Discussion

ES is characterized by multiple congenital anomalies and craniofacial dysmorphism and is treated by multidisciplinary teams. The der(22) may arise from a parental balanced t(11;22)(q23;q11.2) or can be created *de novo* [2]. Mental and developmental retardation is frequently seen. There are several reports about immunological status in ES (**Table 1**). Carter *et al.* reported on 63 individuals with ES [3]. They demonstrated that recurrent infections might be partly responsible for failure to thrive as ES children get older and that chronic and recurrent ear infections were seen in 96% [3]. Emanuel *et al.* demonstrated that

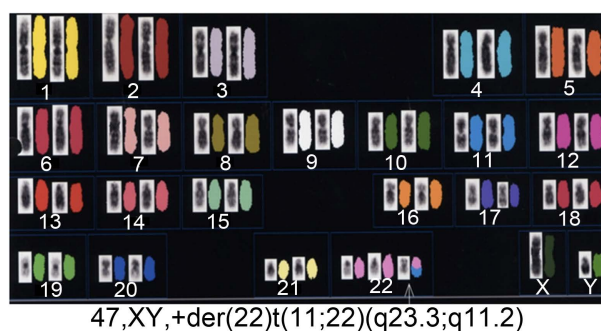


Figure 1. Karyotyping using SKY analysis.

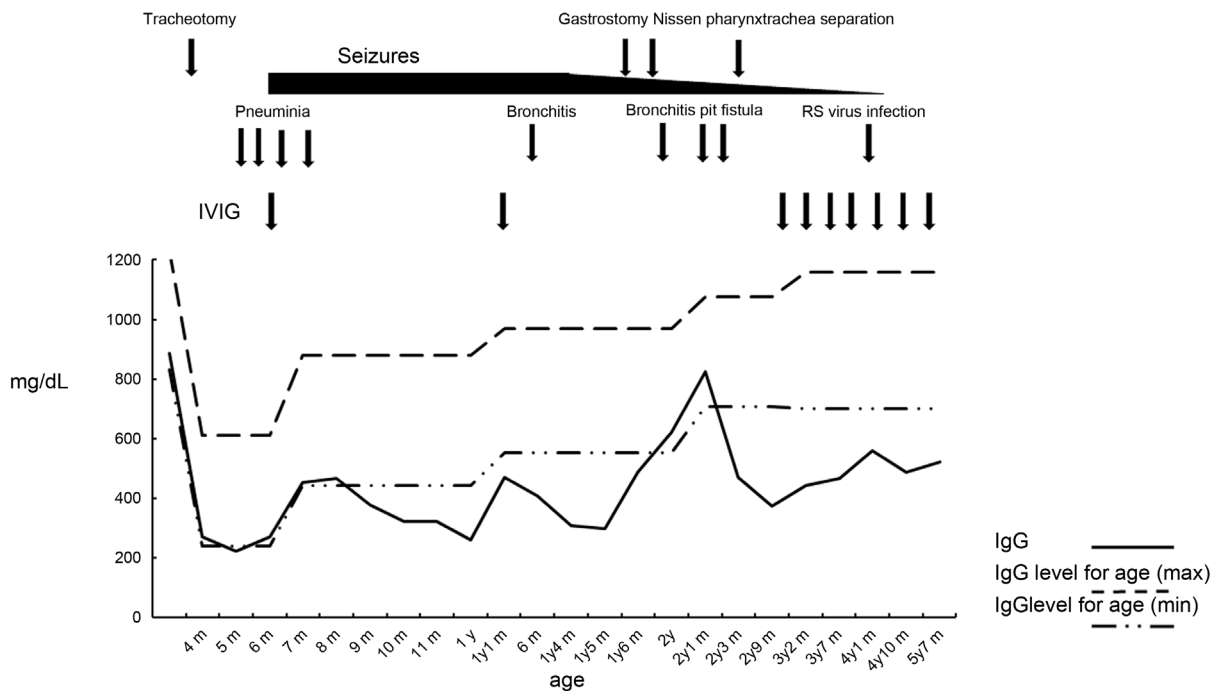


Figure 2. Level of immunoglobulin and clinical course. (IgG is indicated by a black line. Maximum IgG level for age is indicated by a dashed line. Minimum IgG level for age is indicated by a dashed-dotted line).

Table 1. Immunological status in affected ES patients.

Reference	Title	Infections & Immune Status	Follow up results
Carter MT <i>et al.</i> [3]	Phenotypic delineation of Emanuel syndrome (supernumerary derivative 22 syndrome): Clinical features of 63 individuals.	Recurrent ear infections were seen in 96%; 19% had low immunoglobulins and 9% were treated with IVIG which had reported benefit.	no conclusions can be drawn about the use of IVIG.
Emanuel BS <i>et al.</i> [4]	Abnormal chromosome 22 and recurrence of trisomy-22 syndrome.	Recurrent pneumonia developed in nearly 47% of affected patients.	No mention about results
Kapoor S [6]	Emanuel syndrome: A rare disorder that is often confused with Kabuki syndrome.	Cryptorchidism was seen in 46% of ES patients while recurrent urinary tract infections were seen in 18% of affected individuals.	No mention about results
Tovo <i>et al.</i> [7]	Thymic hormone dependent immunodeficiency in an infant with partial trisomy of chromosome 22.	Decreased immunoglobulin levels were found in affected patients.	Thymostimulin increased IgG levels.
Our case	Efficacy of intravenous immunoglobulin in a case of Emanuel syndrome	The level of IgG was below the normal range for his age and recurrent seizures occurred.	Decreased the frequency of infections and seizures after IVIG therapy.

ES patients were especially prone to recurrent infections, particularly recurrent otitis media that nearly 54% of affected patients develop gastro-esophageal reflux, and that recurrent pneumonia developed in nearly 47% of affected patients [4]. It was demonstrated that nearly one fifth of affected patients end up requiring a G tube [5]. In addition, Kapoor reported that cryptorchidism was seen in 46% of ES patients while recurrent urinary tract infections were seen in 18% of affected individuals [6]. The mechanism of susceptibility to infections is not completely clear, although Tovo *et al.* reported decreased immunoglobulin levels in affected patients [7].

In this report, although the level of IgG was below the normal range for his

age, the frequency of infections and seizures were reduced after IVIG therapy. In our case, immunological examinations revealed normal cellular and humoral immune function; however, immunoglobulin levels were low. Probably craniofacial dysmorphism seem to be part of the cause for recurrent infections. This patient had received tracheotomy due to micrognathia, possibly making him susceptible to pneumonia.

Seizures frequently occur in nearly 48% in patients with ES [8]. IVIG has previously been shown to be of potential benefit in epilepsies in which immunological causation is directly implicated, such as Rasmussen's encephalitis and autoimmune limbic encephalitis [9] [10] [11]. Chen *et al.*, using an experimental model of epilepsy, demonstrated that IVIG reduced local activation of glial cells and complement system activation and caused blood-brain barrier damage [12]. In our case, although the mechanism was not identified, frequency of seizures was reduced after IVIG therapy. IVIG might be effective for not only recurrent infections, but also for reduction of recurrent seizures.

Carter *et al.* demonstrated that 19% of ES patients had low IgG and 9% were treated with IVIG which had reported benefit; however, no conclusions could be drawn about the use of IVIG in children with ES as the numbers were small [3].

The mortality rate in ES is unknown because it depends on degree of multiple congenital anomalies. However, long-term survival is possible [3]. Approach, treatment, and careful follow-up for immunological status in patients affected with ES are needed to ensure a better quality of life.

Acknowledgements

The authors thank the native English-speaking medical editors from the Department of International Medical Communications of Tokyo Medical University for editing and reviewing the initial English manuscript.

Declaration of Conflicts of Interest

All the authors report no conflicts of interest.

References

- [1] Ohye, T., Inagaki, H., Kato, T., Tsutsumi, M. and Kurahashi, H. (2014) Prevalence of Emanuel Syndrome: Theoretical Frequency and Surveillance Result. *Pediatrics International*, **56**, 462-466. <https://doi.org/10.1111/ped.12437>
- [2] Jancevska, S., Kitanovski, M., Laban, N., Danilovski, D., Tasic, V. and Gucev, Z.S. (2015) Emanuel Syndrome (ES): New Case-Report and Review of the Literature. *Pril (Makedon Akad Nauk Umet Odd Med Nauki)*, **36**, 205-208.
- [3] Carter, M.T., St Pierre, S.A., Zackai, E.H., Emanuel, B.S. and Boycott, K.M. (2009) Phenotypic Delineation of Emanuel Syndrome (Supernumerary Derivative 22 Syndrome): Clinical Features of 63 Individuals. *American Journal of Medical Genetics Part A*, **149A**, 1712-1721. <https://doi.org/10.1002/ajmg.a.32957>
- [4] Emanuel, B.S., Zackai, E.H., Aronson, M.M., Mellman, W.J. and Moorhead, P.S. (1976) Abnormal Chromosome 22 and Recurrence of Trisomy-22 Syndrome. *Journal of Medical Genetics*, **13**, 501-506. <https://doi.org/10.1136/jmg.13.6.501>

- [5] Budarf, M., Sellinger, B., Griffin, C. and Emanuel, B.S. (1989) Comparative Mapping of the Constitutional and Tumor-Associated 11;22 Translocations. *American Journal of Human Genetics*, **45**, 128-139.
- [6] Kapoor, S. (2015) Emanuel Syndrome: A Rare Disorder That Is Often Confused with Kabuki Syndrome. *Journal of Pediatric Neurosciences*, **10**, 194-195. <https://doi.org/10.4103/1817-1745.159183>
- [7] Tovo, P.A., Davi, G., Franceschini, P. and Delpiano, A. (1986) Thymic Hormone Dependent Immunodeficiency in an Infant with Partial Trisomy of Chromosome 22. *Thymus*, **8**, 313-318.
- [8] Nakai, H., Yamamoto, Y. and Kuroki, Y. (1979) Partial Trisomy of 11 and 22 Due to Familial Translocation t (11; 22)(q23; q11), Inherited in Three Generations. *Human Genetics*, **51**, 349-355. <https://doi.org/10.1007/BF00283408>
- [9] Modoni, A., Masciullo, M., Spinelli, P., Marra, C., Tartaglione, T., Andreetta, F., Tonali, P. and Silvestri, G. (2009) Successful Treatment of Acute Autoimmune Limbic Encephalitis with Negative VGKC and NMDAR Antibodies. *Cognitive and Behavioral Neurology*, **22**, 63-66. <https://doi.org/10.1097/WNN.0b013e318190d195>
- [10] Leach, J.P., Chadwick, D.W., Miles, J.B. and Hart, I.K. (1999) Improvement in Adult-Onset Rasmussen's Encephalitis with Long-Term Immunomodulatory Therapy. *Neurology*, **52**, 738-742. <https://doi.org/10.1212/WNL.52.4.738>
- [11] Villani, F., Spreafico, R., Farina, L., Giovagnoli, A.R., Bernasconi, P., Granata, T. and Avanzini, G. (2001) Positive Response to Immunomodulatory Therapy in an Adult Patient with Rasmussen's Encephalitis. *Neurology*, **56**, 248-250. <https://doi.org/10.1212/WNL.56.2.248>
- [12] Chen, M., Arumugam, T.V., Leanage, G., Tieng, Q.M., Yadav, A., Ullmann, J.F., She, D.T., Truong, V., Ruitenber, M.J. and Reutens, D.C. (2017) Disease-Modifying Effect of Intravenous Immunoglobulin in an Experimental Model of Epilepsy. *Scientific Reports*, **7**, 40528. <https://doi.org/10.1038/srep40528>

Abbreviations

ES, Emanuel syndrome;

IgG, Immunoglobulin;

IVIg, Intravenous immunoglobulin.

Submit or recommend next manuscript to SCIRP and we will provide best service for you:

Accepting pre-submission inquiries through Email, Facebook, LinkedIn, Twitter, etc.

A wide selection of journals (inclusive of 9 subjects, more than 200 journals)

Providing 24-hour high-quality service

User-friendly online submission system

Fair and swift peer-review system

Efficient typesetting and proofreading procedure

Display of the result of downloads and visits, as well as the number of cited articles

Maximum dissemination of your research work

Submit your manuscript at: <http://papersubmission.scirp.org/>

Or contact ojped@scirp.org