

Anterior and posterior urethral valves: a rare association

Sahnoun Lassaad^{1*}, Lamiri Rachida¹, Ben Saad Manel¹, Salem Randa², Mekki Mongi¹, Maazoun Kais¹, Krichene Imed¹, Jamila Chahed¹, Nouri Abdellatif¹

¹Department of Pediatric Surgery, Fattouma Bourguiba Hospital, Monastir, Tunisia;

²Department of Radiology, Fattouma Bourguiba Hospital, Monastir, Tunisia.

Email: lassaad.sahnoun@rns.tn

Received 7 May 2011; revised 15 June 2011; accepted 22 July 2011.

ABSTRACT

Association of anterior and posterior urethral valve is a rare congenital anomaly causing lower urinary tract obstruction in children. This paper highlights our experience with a two-month-old boy with double urethral valves. Antenatal ultrasonography failed to detect any abnormality. At the age of 1 month, he presented with urinary dribbling, straining at micturition, and febrile urinary tract infection. Clinically, the urethra was dilated at micturition. Diagnosis was confirmed by retrograde urethrogram and urethroscopy. Endoscopic ablation of both valves was done by electrocautery hook.

Keywords: Anterior Urethral Valve; Posterior Urethral Valve; Renal Disorders; Double Infravesical Obstruction

1. INTRODUCTION

Posterior urethral valve (PUV) is the most common cause of congenital obstructive uropathy in boys. However anterior urethral valve (AUV) is an uncommon cause of a lower urinary tract obstruction. Association of the two is extremely rare and only four cases have been reported [1]. In this study, we describe our case.

2. CASE REPORT

A two-month-old boy with a history of febrile urinary tract infection at the age of one month, was referred to our department for evaluation of continuous dribbling of urine and straining at micturition. Clinical examination revealed a palpable bladder. The external genitalia were normal. A swelling was palpable in the region of the bulbar urethra. Urinalysis, urine culture, and renal function tests were normal. The catheterization was not successful because the catheter did not pass through the urethra. An anterior urethral valve or urethral diverticulum was recognized.

Renal ultrasonography showed a thick walled bladder

without hydronephrosis (Figure 1).

A retrograde cysto-urethrogram revealed the double infravesical obstruction and the dilated urethra suggestive of concomitant anterior and posterior urethral valves. The AUV was located at the bulbar urethra (Figure 2).

There was no vesicoureteral reflux.

With the patient under general anesthesia, an endoscopic ablation of both valves was done by electrocautery hook. The bladder appeared trabeculated. An urinary catheter was left in place.

Postoperatively, the patient was able to pass urine with good stream and had normal stable renal function. He was discharged 12 days after surgery.

Three months later, the patient presented with urinary infection and dribbling. A renal ultrasound scan failed to show any abnormality. On cystoscopy, there were obs-

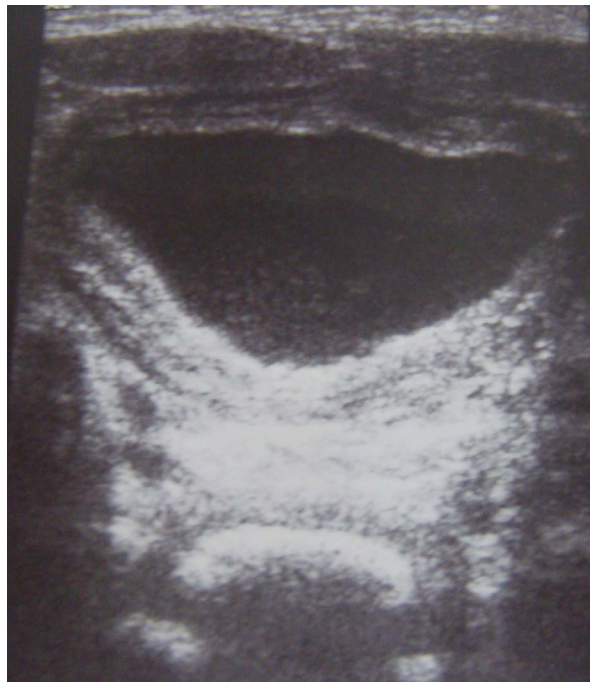


Figure 1. Thickened bladder wall.

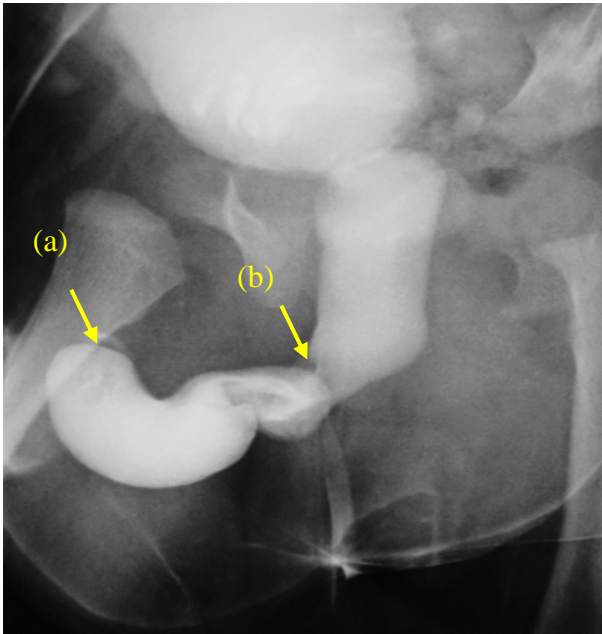


Figure 2. Voiding cystography showing double obstruction and urethral dilatation: (a) anterior urethral valve; there is a bulbous dilatation of the anterior urethra ending in a smooth bulge, which marks the site of the AUV; (b) posterior urethral valve: an elongated and dilated posterior urethra with abrupt narrowing.

tracting anterior and posterior residual urethral valves. An electrocautery hook was done to both the residual valves.

The postoperative course was uneventful. The patient is now 2 years old and continues to void with good stream.

3. DISCUSSION

The association of anterior urethral valve (AUV) with posterior urethral valve (PUV) is rare; only 4 cases have been reported [1-3].

PUV is seven times more common than AUV; however, the obstructive effects of AUV can be equally damaging.

The association of AUV and PUV could not be explained on an embryological basis as the source of AUV and PUV development is different.

The etiology of AUV is still controversial, but faulty union of the glandular and penile urethral segments, incomplete formation of the corpus spongiosum, congenital cystic dilation of the periurethral glands, and abortive attempt at urethral duplication have been proposed as possible mechanisms [1,2,4].

AUV can be located anywhere distal to the membranous urethra and, in terms of distribution; these valves are most common in the bulbar urethra (40%) [1,2,5].

The clinical manifestation of AUV and PUV is highly variable and depends on patient age and degree of ob-

struction. It may range from minimal obstruction to severe obstruction with bilateral severe hydronephrosis, end-stage renal disease, and even bladder rupture [1,2,6,7]. Physical examination findings can be normal.

Prenatal ultrasonography may suggest the diagnosis of AUV and PUV through visualization of urethral dilatation and hydronephrosis, oligohydramnios and bladder distension highly suggestive of infravesical obstruction.

In our case, the antenatal and the postnatal ultrasonography were normal probably because the obstruction was not complete.

Cystourethrography is the mainstay of the diagnosis. It can reveal a thickened trabeculated bladder, a dilated or elongated posterior urethra, a dilation of the anterior urethra, and a hypertrophied bladder neck. Diverticula and vesicoureteral reflux may also be present.

The spectrum of severity of AUV ranges from mild urethral dilatation to bilateral hydronephrosis with renal insufficiency (**Figure 3**) [8,9].

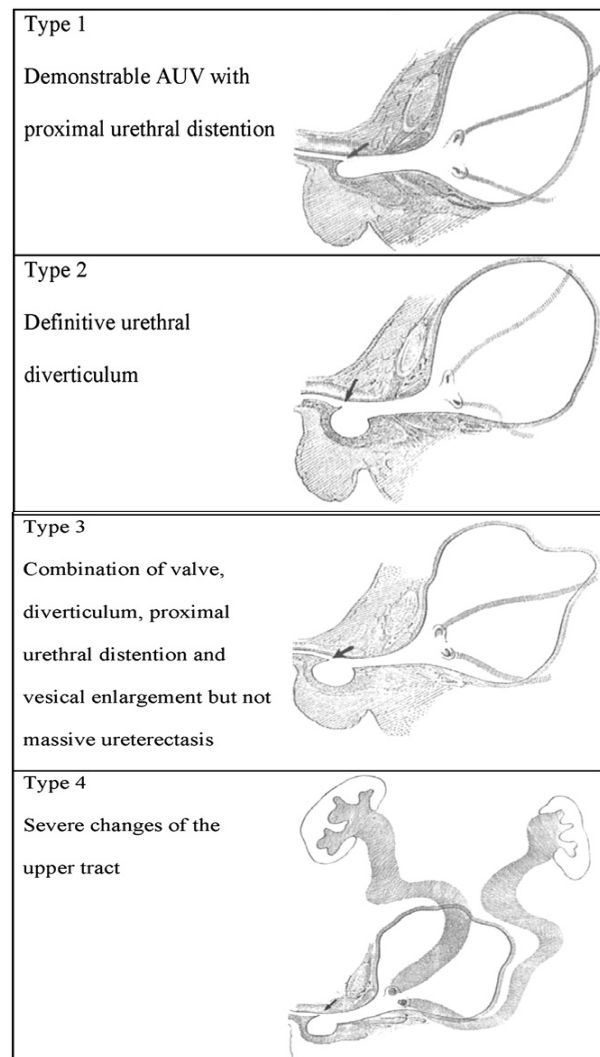


Figure 3. The four types of AUV.

The simplest form is the type 1 like our case [5].

There are various treatment methods such as open urethrotomy and excision of the valve, segmental urethrectomy of the valve-bearing area along with a primary end-to-end anastomosis, cold disruption and transurethral resection of the valve. But endoscopic valve ablation by electrocautery has been the procedure of choice. In our case the endoscopic resection gave good results after 6 months of follow up.

4. CONCLUSIONS

Association of AUV and PUV is a rare entity generally described in case reports. It can cause early proximal urinary tract damage and renal failure if not intervened in time. Transurethral resection is the treatment of choice.

REFERENCES

- [1] Bhagat, S.K., Gopalakrishnan, G., Kekre, N.S. and Kumar, S. (2008) Anterior and posterior urethral valves with subcoronal hypospadias: A rare association. *Journal of Pediatric Surgery*, **43**, E23-E25.
- [2] Kajbafzadeh, A.M., Jangouk, P. and Ahmadi Yazdi, C. (2005) Anterior urethral valve associated with posterior urethral valves. *Journal of Pediatric Urology*, **1**, 433-435. [doi:10.1016/j.jpurol.2005.05.007](https://doi.org/10.1016/j.jpurol.2005.05.007)
- [3] Graham, S.D. Jr., Krueger, R.P. and Glenn, J.F. (1982) Anterior urethral diverticulum associated with posterior urethral valves. *Journal of Urology*, **128**, 376e8.
- [4] McLellan, D.L., Gaston, M.V., Diamond, D.A., Lebovitz, R.L., Mandel, J., Atala, A., *et al.* (2004) Anterior urethral valves and diverticula in children: A result of ruptured Cowper's duct cyst. *British Journal of Urology International*, **94**, 375e8.
- [5] Kibar, Y., Coban, H., Irkilata, H.C., Erdemir, F., Seekin, B. and Dayanc, M. (2007) Anterior urethral valves: An uncommon cause of obstructive uropathy in children. *Journal of Pediatric Urology*, **3**, 350-353.
- [6] Firlit, C.F. and King, L.R. (1972). Anterior urethral valves in children. *Journal of Urology*, **108**, 972e6.
- [7] Aygün, C., Güven, O., *et al.* (2001) Anterior valve as a cause of end stage renal disease. *International Journal of Urology*, **8**, 141-143. [doi:10.1046/j.1442-2042.2001.00270.x](https://doi.org/10.1046/j.1442-2042.2001.00270.x)
- [8] Narashiman, K.L., Choudhary, S.K. and Kaur, B. (2005) Anterior urethral valves. *Indian Pediatrics*, **42**, 708-710.
- [9] Bhagat, S.K., Gopalakrishnan, G., Kekre, N.S. and Kumar, S. (2008) Anterior and posterior urethral valves with subcoronal hypospadias: A rare association. *Journal of Pediatric Surgery*, **43**, e23-e25. [doi:10.1016/j.jpedsurg.2008.04.026](https://doi.org/10.1016/j.jpedsurg.2008.04.026)