

Prostate Tumors Diagnosis: Place of Fine Needle Aspiration in Congolese Patients

C. F. S. Ngatali^{1*}, S. E. Okouango¹, A. F. Bolenga Liboko², L. M. A. Boumba³, E. Ndounga², Y. Mabila², D. Moukassa⁴, J. B. Nkoua-Mbon²

¹Department of Oncology and Internal Medicine, Loandjili General Hospital, Pointe Noire, Congo

²Medical Oncology Department, CHU-Brazzaville, Brazzaville, Congo

³Laboratory of Anatomy Pathology, Loandjili General Hospital, Pointe Noire, Congo

⁴Hospital General Edith Lucie Bongo, Oyo, Congo

Email: *christianngatali2003@yahoo.fr

How to cite this paper: Ngatali, C.F.S., Okouango, S.E., Bolenga Liboko, A.F., Boumba, L.M.A., Ndounga, E., Mabila, Y., Moukassa, D. and Nkoua-Mbon, J.B. (2020) Prostate Tumors Diagnosis: Place of Fine Needle Aspiration in Congolese Patients. *Open Journal of Pathology*, 9, 1-15.
<https://doi.org/10.4236/ojpathology.2020.101001>

Received: July 15, 2019

Accepted: October 28, 2019

Published: October 31, 2019

Copyright © 2020 by author(s) and Scientific Research Publishing Inc. This work is licensed under the Creative Commons Attribution-NonCommercial International License (CC BY-NC 4.0).
<http://creativecommons.org/licenses/by-nc/4.0/>



Open Access

Abstract

Objective: To determine the kappa (κ) concordance coefficient between fine needle aspiration and serum prostatic antigen (PSA) coupled with digital rectal examination and prostatic ultrasound. **Material and Methods:** We conducted a cross-sectional study covering the period from January 1st to June 30th, 2018 in the city of Pointe-Noire. It is a study of 31 cases of prostate tumors in Congolese subjects at the General Hospital of Loandjili in Pointe-Noire of Congo Brazzaville. The clinical, biological, ultrasound and cytological aspects were the variables of the study. **Results:** The mean age was 71.06 years with extremes of 57 and 93 years. One patient had a family history of prostate cancer that was found at his brother's house at the age of 52. Dysuria was the most represented sign in all of our patients. Suspicion of prostate cancer was the most commonly talked in digital rectal examination. Prostate specific antigen (PSA) was greater than or equal to 10 ng/ml in more 74% of our patients. 61.3% of our patients had a heterogeneous prostatic ultrasound. 48.3% of malignant tumors and 32.3% of benign tumors were found cytologically. The association between digital rectal examination and prostatic ultrasound was statistically significant ($p \leq 0.05$) and good agreement was found between cytological diagnosis coupled with digital rectal examination and prostatic echostructure ($0.6 \leq \kappa \leq 0.8$). A low concordance between prostatic specific antigen (PSA) and cytological concordance was noted ($0.2 \leq \kappa \leq 0.4$). **Conclusion:** Prostatic tumors in Congo in their diagnostic particularities are dominated by malignant tumors with a large number of patients to watch. The fine needle aspiration is suitable for orientation examinations of prostatic tumors and can be performed by any doctor and provides us a fast, effective diagnostic orientation with a strong clinico-morphological correlation in our low incomes countries.

Keywords

Fine Needle Aspiration, Prostate Tumors, Diagnosis, Congolese

1. Introduction

Prostate tumors include prostate cancer or malignant tumor and benign prostatic hypertrophy (BPH) or benign tumor. Prostatic tumors are common conditions in people over 50 years of age. They develop at the expense of the prostate gland and are expressed clinically by a change or not in prostatic volume associated or not with symptoms of the lower urinary tract [1]. They constitute a real public health problem. Worldwide prostate cancer is the second most common cancer in men with an incidence of 13.5%, and is the fifth leading cause of cancer death in men with a mortality rate of 6.7%. In Australia/New Zealand, in America Northern and Western Europe, its incidence varies respectively to 86.4%, 73.7% and 75.8% [2]. In Europe, Tuppin P *et al.* reported an incidence estimate of more than 71,000 new cases per year, which represents 34% of all male incident cancers [3]. In Africa, prostate cancer ranks fifth among human cancers in terms of mortality [4]. In 2006, Sow *et al.* in Cameroon, in their study on the epidemiological and histopathological aspects of urogenital tumors, there was a predominance of prostate tumors, 1586 cases out of 2371, including 520 cases of malignant tumors (32.8%) compared to 1066 cases of benign tumors (67.2%) [5]. In Congo, few studies have been conducted on this subject; no national register exists, which underestimates the statistics at the national level. The few data relating to prostate cancer come from the cancer registry of the city of Brazzaville (2013), which reveals that it ranks second among men's cancers after that of the liver [6]. The histological incidence of benign prostatic hypertrophy increases from 80% to 90% from the fourth to the ninth decade. In France, nearly 2 million men have urinary disorders [7]. Numerous studies using the International Prostate Symptom Score (IPSS) have shown, however, that the prevalence of the disease is as high as 40% of men over 50 years of age and their association with age [8]. A Mac Farlane study of 2000 men over the age of 50 showed that 20% had no symptoms, 60% had modest symptoms (IPSS < 7), 15% moderate symptoms (13 ≤ IPSS ≤ 20) and 5% of severe symptoms [9]. In Congo, the underestimation of its statistics at the national level could be explained by, among other things, the lack of adequate structures, the insufficiency of qualified personnel and the inaccessibility of patients to health structures, but above all the difficulties related to diagnosis. Indeed, the elevation of prostate specific antigen (PSA) level frequently attributed to a simple prostatic hypertrophy or the possible presence of a non-palpable cancer, sometimes associated with a digital rectal examination, and a transrectal ultrasound has led some authors to propose systematic echo-guided prostatic biopsies [10]. Although it is a confirmatory diagnostic examination, the practice of the act remains an excessive conduct of low profitability, especially when the level of PSA is less than 10 ng/ml. However, the

increase in this rate requires a better approach to better target biopsy indications for an anatomo-pathological study to obtain a reliable diagnosis [11]. However, the realization of ultrasound-guided prostatic biopsies for histological study is a real problem in countries with limited resources in general and in Congo in particular, because of the scarcity of qualified staff and the inadequacy of the technical platform [12].

In its conditions, the fine needle aspiration of the prostate remains an important alternative technique, which retains all its indications in certain countries and under certain conditions such as the follow-up of the cases treated by chemotherapy and in the bacteriological examinations [13] [14] [15]. Fine-needle aspiration allows cytological smears after puncture of the tissue with a needle less than 1 mm in diameter [13]. Several studies on cytological diagnosis of prostate cancer have been carried out in the world [16] [17]; this is the case of Judith JT *et al.* (2014) in India [16] and AL-Nasiri US *et al.* (2014) in Iraq [17]. On the other hand, in Congo, to our knowledge, no study has yet been carried out to this technique of puncture. Thus we set ourselves the objective of determining the kappa (κ) concordance coefficient between fine needle aspiration and serum prostatic specific antigen (PSA) coupled with digital rectal examination and prostatic ultrasound.

2. Materials and Methods

This was a cross-sectional study covering the period from January 1st to June 30th, 2018, that is, six (06) months, which took place at the General Hospital of Loandjili in the Department of Oncology, General Surgery and the Medical Analysis Laboratory and Morphologies. Have been Included in our study: patients with a normal prostate in the digital rectal examination associated with lower urinary tract symptoms; or an enlarged prostate in the digital rectal examination with or without the presence of lower urinary tract symptoms; patients aged over 50 and those aged 45 years with a family or ethnic risk factors for prostate cancer; the patients coming for a prostatic fine needle aspiration and having the results of serum total PSA and prostatic ultrasound. We excluded from our study: patients whose anal examination revealed an anal fistula or a haemorrhoidal pathology; patients whose samples were non-cellular. In total, fifty four (54) patients were retained. After examination and sampling, thirty-one (31) patients met the inclusion criteria (57.4%) of the original population.

2.1. Necessary Material

Apart from the standard equipment of cytopathology, our material consisted of the FRANZEN kit which included: needles 21 cm long, 0.7 mm in diameter (needle of 22 or 23 gauge still needle PL); the guide and the 10 ml syringe; the RAL555 kit for staining and optical microscope for reading. After sampling, clinical and paraclinical data were collected for each patient from a survey card. Prior to this data collection, an information sheet and a consent form, developed solely for this purpose, were provided to patients.

2.2. The Technique of Fine Needle Aspiration

The technique consisted of taking a sample, which was done by an anatomical pathologist, assisted by a general practitioner. This was the transrectal technique of modified FRANZEN technique. The main disadvantage of the FRANZEN technique was the risk of contaminating the stool sample. In order to prevent this risk, we modified the method of sampling by proceeding perineally. A rectal preparation of 1 to 2 rectal enemas and an antibiotic prophylaxis (Norfloxacin 400 mg) 30 minutes before collection were performed. After treatment, prophylaxis was continued for 5 days every 12 hours. The patient was in the left lateral decubitus, or in the prone position (supine patient, legs folded over the thighs) which was the most convenient. After wearing gloves, the sampling site was disinfected with polyvidone iodine dermal ointment and the patient under regional anesthesia. The technique consisted of simultaneously performing a digital rectal examination with one hand and cytological sampling with the other. The needle was introduced into the perineum (1 to 3 cm in the parenchyma) after the digital rectal examination with polyvidone iodine ointment. The digital rectal examination made it possible to palpate the prostate, which was mobilized by the index finger and the middle finger of one hand (the index finger compressed the prostate, that is, stretched the capsule before it was painful). Then the contralateral hand possessed a needle which was parallel to the rectum and perpendicular to the perineum. After taking cues, 6 to 8 back and forth movements were made to improve cell collection. The plunger is pulled out and the cleat engages, creating a significant depression in the syringe body. Use of the 0.7 mm needle resulted in repeated removal of material from palpable suspicious areas (2 to 3 times) and, compared to the normal lobe, according to the area anatomy of Mc NEAL (the Prostate cancer is most often located in the peripheral part, especially in the posterior lobe but also in the lateral lobes of the prostate gland and benign prostatic hyperplasia in the median lobe). The puncture is complete, when the needle and its dispositive are removed, the rest of the cell suspension is sucked into the syringe and sent to the anatomical pathology laboratory in a padded envelope without additional information (digital rectal examination, serum PSA level, total and ultrasound aspects) other than those provided by the reading grid. The preparation and completion of fine-needle aspiration is 5 to 10 minutes. In principle, interventional pain is no more severe than that caused by an ordinary intramuscular injection. The patient will feel pain during sampling only when the prostate is inflammatory or when the subject has a catheter in place. The needle was as parallel as possible to the rectum to puncture the tumor over its entire cephalo-caudal length and not in its anteroposterior thickness.

2.3. Judgment Criteria

These criteria were used to verify the research hypothesis and to show the diagnostic agreement (diagnostic confirmation coefficient). The criteria were total serum PSA level. It is only used in the diagnosis of prostate cancer, according to the 2013 onco-urology recommendations; the level of PSA varies according to

the location or extension of prostate cancer in the gland, so:

- Serum total PSA level < 4 ng/ml. This is the threshold value for suspecting prostate cancer; the sensitivity of total PSA to detect a cancer with this threshold value is about 70%, and its specificity of 90%.
- $4 \leq$ total serum PSA < 10 ng/ml. 70% of diagnosed prostate cancers are localized. The positive predictive value of total PSA is 25% to 35%.
- Total serum PSA \geq 10 ng/ml. Prostate cancer is metastatic. The positive predictive value of total PSA is 50% - 80%.

2.4. Digital Rectal Examination

A prostate of indurated consistency with an undissolved posterior median furrow and/or presence of nodule cause cancer is to be suspected. A firm-looking prostate, with an eroded furrow and no nodules, suggests benign prostatic hypertrophy.

2.5. The Result of the Cytological Analysis

The malignant cytology was the presence of cytological and nuclear atypical. Benign cytology was the absence of cytological and nuclear atypical.

2.6. The Kappa (κ) Concordance Coefficient between Two Diagnostic Tests

The interpretation of the kappa test depended on the calculated value of the coefficient κ :

- Discordance between two tests: $\kappa < 0$;
- Very low concordance: $0 < \kappa \leq 0.2$;
- Low concordance: $0.2 < \kappa \leq 0.4$;
- Moderate agreement: $0.4 < \kappa \leq 0.6$;
- Good concordance: $0.6 < \kappa \leq 0.8$;
- Excellent concordance: $0.8 < \kappa \leq 1$.

2.7. Statistical Analysis

Statistical analyses were performed by Microsoft Excel software version 2013 for the preparation of the database, the Graph Pad Prism version 5.0.0.3 for data processing. The Fisher and chi-square test were used to compare the rates with a significance if p value is less than or equal to 0.05. An interval of 95% was used for the calculation of the results. The results were expressed in average for the quantitative variables and in number or percentage for the qualitative variables.

2.8. Ethical Considerations

This work was conducted as part of a scientific research. As a result, it has been approved by the Health Research Ethics Committee, and the related survey has ensured the confidentiality of the data. No patient was included without his prior consent and informed and signed consent. The analyses were free for all

patients.

3. Results

The average age was 71.06 ± 9.09 years with extremes ranging from 57 to 93 years. The median was 70 years old. More than 45% of the study population was between 67 and 76 years old. Patients with an age of less than or equal to 66 represented 29%, while those over 87 represented only 3.2% of the study population (**Figure 1**). The majority of the study population (96.8%) had no family history of prostate cancer, only one patient had a family history of cancer (siblings at age 52) (**Table 1**). Our study population consisted of 100% black race (Congolese subjects). Dysuria and pollakiuria were the main symptoms with 39.7% and 35.9% respectively (**Table 2**). In 64.5% of the patients studied, the consistency of the prostate was indurated, the posterior median furrow was present, and the contours were irregular in digital rectal examination (**Table 3**). The diagnoses evoked at the end of digital rectal examination revealed the suspicion of prostate cancer in 64.5% of patients and a benign hypertrophy or benign tumor in 35.5% of patients (**Figure 2**). From a biological point of view, the total serum PSA was measured in all patients. Over 74.2% of our patients had a total serum PSA level greater than or equal to 10 ng/ml (**Figure 3**). A little over 61% of our study population had a heterogeneous prostatic ultrasound structure, 38.7% of patients had a homogeneous ultrasound structure (**Figure 4**). In our series, of 31 cases of prostatic tumors, 48.3% ($n = 15$) were malignant tumors, 32.3% ($n = 10$) were benign tumors, and 19.3% ($n = 6$) were suspects of malignant, those whose evolutionary potential requires rigorous surveillance. Malignant and suspicious cytologies were considered as positive diagnosis, benign cytologies were considered as negative diagnosis (**Figure 5**). Malignant tumors of the prostate were evoked during the digital rectal examination and confirmed by cytology in 61.3% ($n = 19$) of the patients and 3.2% were benign tumors. Among the evoked benign tumors during the digital rectal examination 29% were confirmed benign tumors by cytology and 6.5% were malignant tumors. A statistical difference was observed between digital rectal examination and cytological diagnosis ($p = 0.0001$) (**Table 4**). Malignant prostate tumors accounted for 76.2% in patients with total serum PSA ≥ 10 ng/ml and 70% were benign tumors. There were respectively 30% of benign tumors and 14.3% of malignant tumors among patients with the total serum value of PSA between 4 and 10 ng/ml. In contrast, 9.5% of patients with malignant tumors had a total serum PSA level < 4 ng/ml. No statistically significant difference ($p = 0.3962$) was observed between PSA level and cytological diagnosis (**Figure 6**). Among patients with homogeneous prostate ultrasound structure there were 100% of benign tumors and 4.76% of malignant tumors. There were 95.2% of malignant tumors among patients with heterogeneous ultrasound prostate structure (**Figure 7**).

The PSA level ranged from 0.8 to 6490 ng/ml with an average of 431.9 ± 1302.2 . Nearly 42% of the study population had a total serum PSA level greater than 41.9 ng/ml.

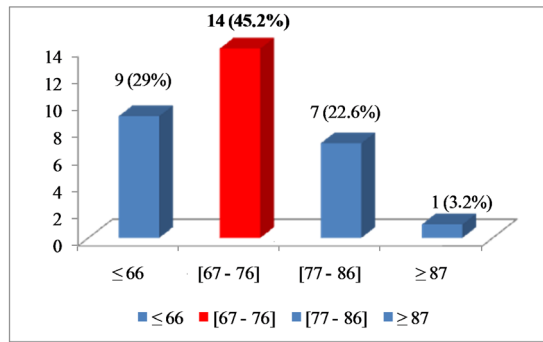


Figure 1. Distribution of patients by age.

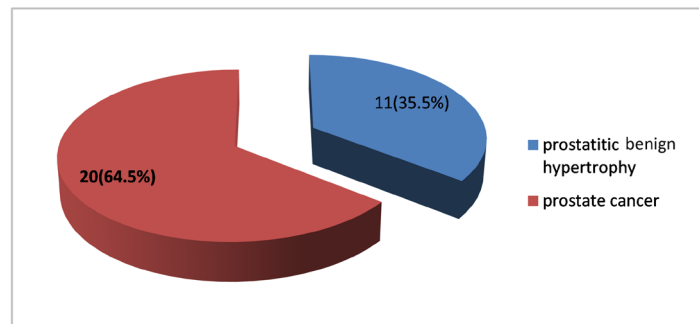


Figure 2. Distribution of patients according to diagnoses mentioned after digital rectal examination.

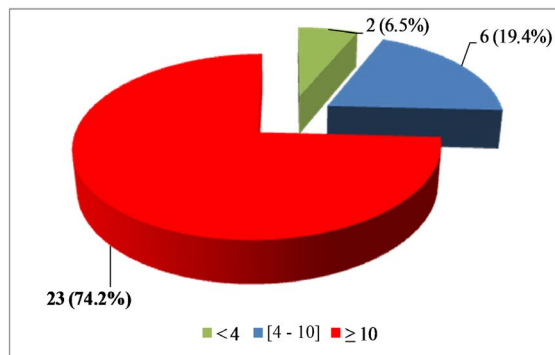


Figure 3. Distribution of patients according to the value of the total serum PSA level.

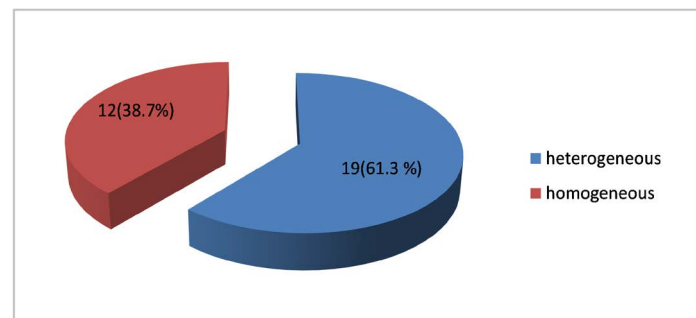


Figure 4. Distribution of patients according to ultrasound structures of the prostate.

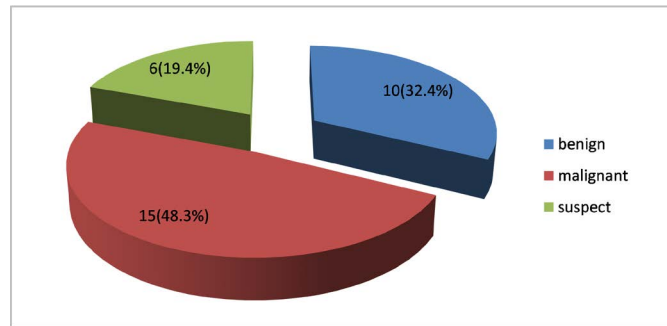


Figure 5. Distribution of patients according to cytological diagnosis.

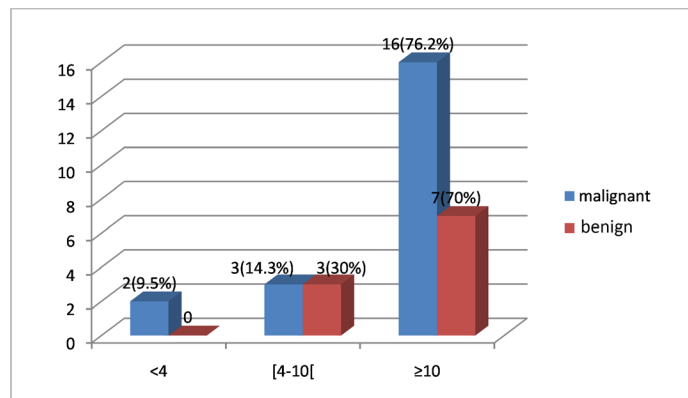


Figure 6. Distribution of patients according to cytological diagnosis and PSA. $p > 0.05$ result at non significatif.

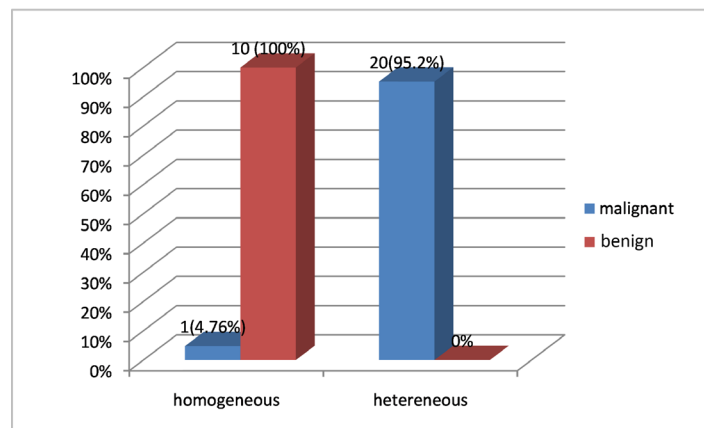


Figure 7. Distribution of patients according to cytological diagnosis and prostatic ultrasound structure. $p < 0.0001$ result statistically significant.

Table 1. Distribution of patients according to family cancer history.

Family cancer history	Number	Percentage
yes	1	3.2
no	30	96.8
Total	31	100.0

Our study population consisted of 100% black race (Congolese subjects).

Table 2. Distribution of patients according to lower urinary tract symptom (LUTS).

Symptome	Number	Percentage
Dysuria	31	39.7
Pollakiuria	28	35.9
Compelling urinating	2	2.6
Hematuria	3	3.8
Urine retention	2	2.6
Mictional burns	2	2.6
Others	1	1.2
Total	78	100

Dysuria and pollakiuria were the main symptoms with respectively 39.7% and 35.9%.

Table 3. Distribution of patients according to the characteristics of the prostate in digital rectal examination.

Chracteristic DRE	Number	Percentage
Consistency		
Firm	11	35.5
Indured	20	64.5
Existence of median furrow		
No	11	35.5
Yes	20	64.5
Prostatic contours		
Regular	11	35.5
Irregular	20	64.5
Total	31	100

Table 4. Distribution of patients according to cytological diagnosis and digital rectal examination (DRE).

DRE	Cytological diagnosis					
	Malignant		Benign		Total	
	Number	Percentage	Number	Percentage	Number	percentage
Prostatic benign hypertrophy	2	6.5	9	29	11	35.5
Prostate cancer	19	61.3	1	3.2	20	64.5
Total	21	67.7	10	32.3	31	100

$p < 0.0001$ (DS).

Table 5. Patient distribution by kappa coefficient of concordance.

Examination	Cytological diagnosis			κ	p
	Malignant	Benign	Total		
DRE	19	1	20	0.7842	0.0001
	2	9	11		
PSA	2	0	2	0.0617	1813
	3	3	6		
	16	7	23		
Ultrasound structure	1	20	21	0.7547	0.0001
	10	0	10		

4. Discussion

The perineal needle aspiration of the prostate, which by cytology, also allows the diagnosis of orientation or presumption emergency prostate tumors [13] and especially pending histological results. As a reminder, cytology and histology are not two competitive exams [13] but rather alternative, the only and only definitive examination of prostate cancer remains histology. The difficulties of our study were essentially the realization of the modified Franzen technique such as: Normal size prostates that were hardly noticeable; important adipose panicle; the refusal of Franzen's needle; and working methodologies (study duration), this also explains the small size of our study sample. The sampling strategy consisted of obtaining a number of cases necessary for a statistical significance of the results. Saleh AFM *et al.* [18] in Bangladesh in 2005 in a study to describe the role of transrectal needle aspiration in the diagnosis of prostatic lesions correlated to histological lesions, included 64 cases for needle aspiration and 60 cases for histology; as well as Tariqul I *et al.* [19] in 2007 in Bangladesh included 62 cases, Judith JT *et al.* [16] in 2014 in India analyzed 100 cases of prostatic tumors and Chayanika P *et al.* [20] in 2012 in India who had a sample size of 121. This type of sampling wiser than in our study was possible through cohort studies of about 1 year. However, the small size of the sample, thus limiting the extrapolation of epidemiological data to the national scale, does not in any way affect the quality of this study, which is fundamental to us. Indeed, Engelstein D *et al.* [21] in 1994, Piaton E [22] in 1994 in France, Ito H *et al.* [23] in 1995 in France and Al-Nasiri US *et al.* [17] in 2014 in Iraq also had in similar studies to ours, a small sample size.

We used the modified FRANZEN transrectal technique. The main disadvantage of the FRANZEN technique was the risk of contaminating the stool sample, to prevent this risk; we changed the method of sampling by perineal procedure. The judgment criteria made it possible to compare the results obtained according to the international recommendations. Indeed, several studies carried out on fine needle aspiration in the diagnosis of prostatic tumors used the same criteria of judgment. Chayanika P *et al.* [20] in 2012 in India, Tariqul I *et al.* [19] in 2007 in Bangladesh and Saleh AFM *et al.* [18] in Bangladesh in 2005, used the same judgment criteria for the description of the role of transrectal fine-needle aspiration in the diagnosis of prostatic lesions correlated with histology. Prostate tumors are the preserve of men over the age of 50; the obsession would be to develop prostate cancer. The age of our patients was between 57 and 93 years old with an average of 71.06 years. There was a peak incidence in the 67 to 76 age group with 45.2% (14 cases). These data were comparable to those reported in the international literature, particularly those observed in Bangladesh by Saleh AFM *et al.* who had a mean age of 70 years [18] and those observed in Germany by Norming U *et al.* [24] and Norberg M *et al.* [25] who had an average age of 68 years and 65 years respectively. The digital rectal examination, based on the examination of a patient with a prostatic tumor [26] found an enlarged prostate in

all cases and 64.5% of patients had a prostate suspected of neoplasia. In Bangladesh, Saleh AFM *et al.* have made the same finding in almost all of their patients [18], Judith JT *et al.* [16] in India have objectified 64% of tumors suspected of neoplasia. The PSA assay is only indicated in prostate cancer, but the diagnosis of benign prostate hypertrophy (BPH) is limited to digital rectal examination. Digital rectal examination remains recommended in combination with the total PSA assay for the diagnosis of prostate cancer [27]. The threshold value of the serum total PSA that causes cancer to be suspected is typically 4 ng/ml. With this threshold value, the sensitivity of the total PSA to detect a cancer is about 70%, and its specificity of 90% [28]. The positive predictive value of total PSA is 25% to 35% for a value of between 4 and 10 ng/ml and 50% to 80% for a level greater than 10 ng/ml [28]. When the total PSA is between 4 and 10 ng/ml, 70% of diagnosed cancers are located. In our series, 74.2% of our patients had a serum total PSA level greater than or equal to 10 ng/ml. Our observation is corroborated by the data of the literature. Al-Nasiri US *et al.* [17] in Iraq noted the same trends. This high serum total PSA level could be explained by repeated infections because Pointe-Noire is in a bilharzic endemic zone. Ultrasonography is insensitive and inaccurate for the detection of prostate cancer [29]; it is used primarily for prostate volume evaluation and remains the gold standard for performing prostate biopsies that can be sensitized by microbubble injection, elastography, and image fusion, MRI [30]. It is used in benign prostatic hypertrophy to evaluate bladder and kidney impact and the weight or volume of the prostate before any therapeutic indication (pre-therapeutic assessment) [7]. Prostate ultrasound is used primarily for the evaluation of prostatic volume [29]. It remains the reference examination for the realization of prostate fine needle aspiration and biopsies [29]. In 61.3% of cases, the ultrasound structure of the prostate was heterogeneous; it should be noted that despite the quality of the ultrasound image when it is performed endorectally, it has been shown that there is no specific aspect of cancer although hypoechoic images are twice as often cancerous biopsies [31]. Prostatic ultrasound was used in Germany by Norming U *et al.* [21], in India by Judith JT *et al.* [16] and in Iraq by Al-Nasiri US *et al.* [17]. The diagnosis of certainty has been made by cytology in all cases. Thus, in our series, of 31 cases of colloidal prostatic tumors, 48.4% (n = 15) were malignant tumors, 32.2% (n = 10) were benign tumors, and 19.4% (n = 6) were benign tumors, whose evolutionary potential requires careful monitoring. Saleh AFM *et al.* [20] on a study of 64 cases of prostatic lesions found after 76.6% (n = 49) fine-needle transrectal needle aspiration of nodular hyperplasia, 20.3% (n = 13) of cancers and 28.1% (n = 18) of cancer suspicions. Al-Nasiri US *et al.* [17] on a study of 50 cases of prostatic tumors found after transrectal needle aspiration 48% (n = 24) of malignant tumors and 52% (n = 26) of benign tumors. Tariqul I *et al.* [19] on a study of 62 cases of prostatic lesions, found after cytology 58.06% (n = 36) of benign lesions, 33.8% (n = 21) of malignant tumors, and 8.06% (n = 5) of atypical lesions of the prostate. In our study, there was no significant difference in the

correlation between cytological diagnosis and age ($p = 1618$). However, there was a predominance of the age group of 67 to 76 years (38.7%); this could be explained by the aging of the population and the contribution of digital rectal examination in the detection of tumors prostate cancer and the provision of serum PSA levels in screening for prostate cancer. Our study allowed us to note a statistically significant difference between the cytological diagnosis in the prostate gland and the digital rectal examination ($p < 0.0001$). Prostate cancer was reported by digital rectal examination and confirmed by cytology in 61.3% of patients. Digital rectal examination and cytology are two tests that can be used to confirm the diagnosis of prostatic tumors. Total serum PSA was elevated in the majority of our patients; however, the crossover between needle aspiration and serum PSA level revealed a non-significant association ($p = 0.3962$). A significant correlation has been found between the cytological diagnosis and the prostate ultrasound structure of our patients. Our study was conducted on the basis of three examinations below: digital rectal examination, total serum PSA and prostatic ultrasound, although only the first two exams are the only ones recommended [11] [32]. We have dwindled to the three examinations as in other previous studies [11] [33]. We are aware of the under-detection of prostate cancer when the punctures are manually compared to those that are echo-guided. The present study found that high levels of PSA, abnormalities of digital rectal examination and prostatic ultrasound are associated with a strong suspicion of prostate cancer.

5. Conclusion

Fine needle aspiration is a diagnostic method used to determine the type of tumor lesions by classifying them as three (3) degrees of malignancy. Rapid, efficient diagnosis with a strong clinical and morphological correlation (rectal examination and ultrasound of the prostate gland), a strong kappa agreement between cytological diagnosis and digital rectal examination coupled with the ultrasound of the prostate gland and the low percentage of complications are the essential qualities of this method. This method can be indicated in low incomes countries, where the staff is rare.

Conflicts of Interest

The authors declare no conflicts of interest regarding the publication of this paper.

References

- [1] Richard, F., Luckas, B., Jardin, A., Lanson, Y., Chevret-Meason, M., Grange, R.J.C. and Navratil, H. (2001) Résultats d'une enquête épidémiologique menée chez les hommes âgés de 50-80 ans étudiant les troubles mictionnels, qualité de vie et fonction sexuelle. *Progrès en Urologie*, **11**, 250-263.
- [2] Bray, F., Ferlay, J., Soerjomataram, I., Siegel, R.L., Torre, L.A. and Jemal, A. (2018) Global Cancer Statistics: GLOBOCAN Estimates of Incidence and Mortality World-

- wide for 36 Cancers in 185 Countries. *CA: A Cancer Journal for Clinicians*, **68**, 394-424. <https://doi.org/10.3322/caac.21492>
- [3] Tuppin, P., et al. (2012) Consommation du dosage de l'antigène spécifique de la prostate (PSA) en France chez les hommes sans cancer de la prostate déclaré. *Bulletin du Cancer*, **99**, 521-527.
- [4] Chang, B.L., Spangler, E., Gallagher, S., et al. (2012) Validation of Genome-Wide Prostate Cancer Association in Men of African Descent. *Cancer, Epidemiology, Biomarkers and Prevention*, **20**, 23-32. <https://doi.org/10.1158/1055-9965.EPI-10-0698>
- [5] Sow, M., Nkégoum, B., Essame Oyono, J.L. and Garoua, N.A. (2006) Aspects épidémiologiques et histopathologiques des tumeurs urogénitales au Cameroun. *Progrès en Urologie*, **16**, 36-39.
- [6] Nsonde Malanda, J., Nkoua-Mbon, J.B., Bamara, et al. (2013) Douze années de fonctionnement du registre des cancers de Brazzaville. *Bulletin du Cancer*, **100**, 135-139. <https://doi.org/10.1684/bdc.2013.1701>
- [7] (2011) Hyperplasie benigne de la prostate (HBP). <http://www.urofrance.org>
- [8] McKelvie, G.B., Collins, G.N., Hehir, M. and Rogers, A.C. (1993) A Study of Benign Prostatic Hyperplasia: A Challenge to British Urology. *British Journal of Urology*, **71**, 38-42. <https://doi.org/10.1111/j.1464-410X.1993.tb15877.x>
- [9] Mac Farlane, G.J., Sagnier, P.P., Richard, F., Teillac, P., Botto, H. and Boyle, P. (1995) Troubles mictionnels de l'homme âgé: Quels sont les symptômes qui poussent les patients à consulter? *British Journal of Urology*, **76**, 714-718. <https://doi.org/10.1111/j.1464-410X.1995.tb00762.x>
- [10] Chauvet, B., Villers, A., Davin, J.L. and Nahon, S. (2002) Actualités sur le dépistage, le diagnostic et le traitement des cancers de prostate. *Bulletin du Cancer*, **89**, 37-45.
- [11] Punga-Maole, A.M.L., Moningo, D.M., Kayembe, P.K., Tshikuela, M.L. and Kabongo, J.M.M. (2008) Etude de dépistage du cancer de la prostate au sein d'une population d'employés d'une entreprise de Kinshasa en République Démocratique du Congo. Taux de détection et facteurs de risque nutritionnels et géographiques. *Progrès en Urologie*, **18**, 512-518. <https://doi.org/10.1016/j.purol.2008.04.009>
- [12] Demura, T., Shinohara, N., Tanaka, M., et al. (1996) The Proportion of Free to Total Prostate Specific Antigen. *Bulletin du Cancer*, **77**, 1137-1143. [https://doi.org/10.1002/\(SICI\)1097-0142\(19960315\)77:6<1137::AID-CNCR20>3.0.CO;2-1](https://doi.org/10.1002/(SICI)1097-0142(19960315)77:6<1137::AID-CNCR20>3.0.CO;2-1)
- [13] Faryna, J. (1997) Cytoponction à l'aiguille fine de la prostate: Indications, techniques et limites. *Masson*, **295**, 103-107. [https://doi.org/10.1016/S0338-9898\(97\)80299-5](https://doi.org/10.1016/S0338-9898(97)80299-5)
- [14] De la Taille, A., et al. (1998) Détection in vitro des cellules circulaires dans le cancer de la prostate par immunocytochimie, cytométrie en flux et RT-PCR-PSA. *Progrès en Urologie*, **8**, 1058-1064.
- [15] Lieber, M.M. (1995) Practical Clinical Utility of DNA Ploidy for Managing Patients with Prostate Carcinoma. *Urology*, **45**, 558-562. [https://doi.org/10.1016/S0090-4295\(99\)80042-9](https://doi.org/10.1016/S0090-4295(99)80042-9)
- [16] Judith, J.T., Balachandran, K., Poothode, U. and Bhat, S. (2014) Validity of Fine Needle Aspiration in Diagnosis of Prostatic Lesions and Correlation with Trucut Biopsy. *Medical Sciences*, **7**, 75-80.
- [17] Al-Nasiri, U.S., Hamoodi, A.H. and Raghbi, J.H. (2014) Value of Fine Needle Aspiration Cytology under Ultra-Sound Guided Biopsy in the Diagnosis of Prostatic

Cancer. *The Iraqi Postgraduate Medical Journal*, **13**, 384-389.

- [18] Saleh, A.F.M., Nahar Rahman, A.J.E., Salam, M.A. and Islam, F. (2005) Role of Fine Needle Aspiration Cytology (FNAC) in the Diagnosis of Prostatic Lesions with Histologic Correlation. *Bangladesh Medical Research Council Bulletin*, **31**, 95-103.
- [19] Tariqul, I., Tamanna, C., Khan, K.H., Barua, A.R., Mohammed, K. and Nahar Rahman, A.J.E. (2007) Fine Needle Aspiration Cytology of Prostatic Lesions with Histologic Correlation. *Ibrahim Medical College Journal*, **1**, 7-10.
<https://doi.org/10.3329/imcj.v1i1.2888>
- [20] Chayanika, P., Sanjay, K., Singh, P.K., Asha, A. and Sonal, A. (2012) A Correlative Study between Transrectal FNAC and Histology of the Prostate for the Detection of Prostate Carcinoma. *IOSR Journal of Dental and Medical Sciences*, **1**, 18-20.
<https://doi.org/10.9790/0853-0111820>
- [21] Engelstein, D., Makumel, E., Cytron, S. and Konichzky, S. (1994) A Comparison between Digitally-Guided Fine Needle Aspiration and Ultrasound-Guided Transperinéale Core Needle Biopsy of the Prostate for the Detection of Prostate Cancer. *British Journal of Urology*, **74**, 210-213.
<https://doi.org/10.1111/j.1464-410X.1994.tb16588.x>
- [22] Piaton, E. (1994) La cyto-aspiration prostatique transrectale. *Andrologie*, **4**, 223-227.
<https://doi.org/10.1007/BF03034289>
- [23] Ito, H., Yamaguchi, K., Kotake, T., Metsuzaki, O. and Nagao, K. (1995) Usefulness of Aspiration Cytology in Prostate Cancer Detection. *International Urology and Nephrology*, **27**, 93-100. <https://doi.org/10.1007/BF02575226>
- [24] Norming, U., Gustafsson, O., Nymant, C.R., Raaschou, N.T. and Naslund, I. (1991) Fine-Needle Aspiration Biopsy with a New Automatic Fine Needle Gun versus Histological Core in Ultrasonically-Guided Transrectal Biopsy for Detection of Prostate Cancer. *Acta Oncologica*, **30**, 155-157.
<https://doi.org/10.3109/02841869109092340>
- [25] Norberg, M., Busch, C., Stavinoha, J., Scardino, P.T. and Magnusson, A. (1994) Transrectal Ultrasound-Guided Core Biopsies of the Prostate: A Comparison between the Standard 1,2-mm Needle and Three Thinner Needles. *Acta Radiologica*, **35**, 463-465. <https://doi.org/10.1177/028418519403500514>
- [26] Brock, M., Eggert, T., Palisaar, R.J., Roghmann, F., Braun, K., Loppenberg, B., *et al.* (2012) Multiparametric Ultrasound of the Prostate: Adding Contrast Enhanced Ultrasound to Real-Time Elastography to Detect Histopathologically Confirmed Cancer. *Journal of Urology*, **189**, 93-98. <https://doi.org/10.1016/j.juro.2012.08.183>
- [27] Ferguson, R.S. (1930) Prostatic Neoplasms: Their Diagnosis by Needle Puncture and Aspiration. *The American Journal of Surgery*, **9**, 507-511.
[https://doi.org/10.1016/0002-9610\(30\)90126-2](https://doi.org/10.1016/0002-9610(30)90126-2)
- [28] Salomon, L., Azria, D., Bastide, C., Beuzebec, P., Cormier, L., Cornud, F., *et al.* (2010) Recommandations en onco-urologie 2010: Cancer de la prostate. *Progrès en Urologie*, **20**, 217-251. [https://doi.org/10.1016/S1166-7087\(10\)70042-7](https://doi.org/10.1016/S1166-7087(10)70042-7)
- [29] Salomon, L., *et al.* (2013) Recommandations en onco-urologie 2013 du CCAFU: Cancer de la prostate. *Progrès en Urologie*, **2**, 69-102.
[https://doi.org/10.1016/S1166-7087\(13\)70048-4](https://doi.org/10.1016/S1166-7087(13)70048-4)
- [30] American Cancer Society (1989) Survey of Physician's Attitudes and Practices in Early Cancer Detection. *CA: A Cancer Journal for Clinicians*, **40**, 77-80.
<https://doi.org/10.3322/canjclin.40.2.77>
- [31] Hammerer, P. and Huland, H. (1994) Systematic Sextant Biopsies in 651 Patients Referred for Prostate Evaluation. *Journal of Urology*, **151**, 99-102.

[https://doi.org/10.1016/S0022-5347\(17\)34880-2](https://doi.org/10.1016/S0022-5347(17)34880-2)

- [32] Mongiat-Artus, P. and Teillac, P. (2016) Screening for Prostate Cancer: Synthesis. *Annales d'Urologie*, **40**, 106-110. <https://doi.org/10.1016/j.anuro.2006.01.009>
- [33] Yamamoto, T., Itio, K., Ohio, M., *et al.* (2001) Diagnostic Significance of Digital Rectal Examination and Transrectal Ultrasonography in Men with Prostate Specific Antigen Level of 4 ng/ml or Less. *Urology*, **58**, 994-998. [https://doi.org/10.1016/S0090-4295\(01\)01409-1](https://doi.org/10.1016/S0090-4295(01)01409-1)