

Surgical Treatment of Ectropion at Polyclinic “SHOSHI” in Prishtina—Case Report

Fjolla Shoshi¹, Fitore Shoshi¹, Mire Hoxha-Shoshi¹, Avdyl Shoshi², Anita Sylja Lokaj³,
Flaka Shoshi^{4,5}

¹College of Medical Sciences, REZONANCA, Prishtina, Kosova

²Polyclinic, SHOSHI, Prishtina, Kosova

³Eye Clinic, UCCK, Prishtina, Kosova

⁴University of Prishtina, Prishtina, Kosova

⁵International Medical School, Sapienza University of Rome, Rome, Italy

Email: mireshoshi@hotmail.com, shoshifitore@gmail.com, fiolla@hotmail.com

How to cite this paper: Shoshi, F., Shoshi, F., Hoxha-Shoshi, M., Shoshi, A., Lokaj, A.S. and Shoshi, F. (2018) Surgical Treatment of Ectropion at Polyclinic “SHOSHI” in Prishtina—Case Report. *Open Journal of Ophthalmology*, 8, 64-68.
<https://doi.org/10.4236/ojoph.2018.81009>

Received: January 20, 2018

Accepted: February 25, 2018

Published: February 28, 2018

Copyright © 2018 by authors and Scientific Research Publishing Inc.
This work is licensed under the Creative Commons Attribution International License (CC BY 4.0).
<http://creativecommons.org/licenses/by/4.0/>



Open Access

Abstract

Ectropion is an outward turning of the *eyelid* margin, as a result the conjunctiva is permanently irritated, thickened and dry. Since the lacrimal puncta are moved away from the eyeball, the tear elimination is difficult, tears are always present. **Materials and Methods:** This study includes patients suffering from senile ectropion, who were treated surgically at Polyclinic “SHOSHI” in Prishtina. Our study includes 19 patients suffering from senile ectropion, out of which, 17 were older than 75 years old and in those patients the ectropion was present on both lower eyelids, while 2 patients were under 75 years old and the ectropion was present only on one side lower eyelid. Prior to surgery, patients have undergone laboratory examinations. The surgery was performed under local anesthesia. The suturing was done in three layers using 6.0 vicryl sutures. No operative or post-operative complications were encountered. **Purpose:** The purpose of this case report study is to show the success of the surgical treatment of ectropion, a procedure that is mainly performed so the tear elimination is enabled, and there are no tears present constantly. **Conclusion:** In old patients where the eyelid is turned outwards its margin, conjunctiva is constantly irritated, thickened and dry, the best method of treatment is the surgical treatment, making it possible for the tears to drain properly.

Keywords

Ectropion, Conjunctiva, Irritation, Presence of Tears, Surgical Treatment

1. Introduction

The eyelids are composed of muscular tissue, covered with the mucosa and skin.

They are positioned vertically and in front, closing the orbital area. The upper eyelid is twice wider than the lower eyelid. Open eyelids border the palpebral fissure which length is 7 - 12 mm and the width around 30 mm [1].

The loose end of the eyelid has two edges, the anterior and the posterior edge. The posterior sharp edge fits on the eyeball while the anterior edge has an oval shape, and it is where the eyelashes are located. The eyelid is 2 mm thick and is built of the skin, sub-dermal tissue, orbicularis oculi muscle, orbital septum, anterior part of the adipose tissue of the orbit, levator muscle, Miller's muscles, tarsus and the conjunctiva. The sub-dermal disuse is very schist and has no adipose composition, this characteristic of this tissue, enables the skind to slide easily during the eyelid movement. The orbicularis oculi muscle is innervated by the facial nerve, the lacrimal part contraction enables the tear flow, palpebral part contraction enables the eyelid closure and the contraction of both orbital and palpebral parts enables the eyes to close firmly.

The tarsal plates build up the hard part of the fibrotic skeleton of the eyelid, a part that does not shrink during the eyelid closure.

They have a semi-circular shape with a convex peripheral edge and a horizontal central edge, which is included in the free edge of the eyelid. The most inner layer of the eyelid is composed of the conjunctiva; it is attached firmly to the inner surface of the tarsal plates. The eyelids are rich in blood circulation and this characteristic enables a fat recovery and regeneration of the tissues after any injury or surgical interventions and increases the resistance towards infections.

Ectropion as an eyelid pathology is the is an outward turning of the *eyelid* margin, as a result the conjunctiva is permanently irritated, thickened and dry. [2] [3] [4] [5]. Since the lacrimal puncta are moved away from the eyeball, the tear elimination is difficult, tears are always present.

Based on the etiopathogenesis, there are various types of ectropions. The spastic ectropion is usually common in young patients and is presented with an inflamed thickened conjunctiva moving the eyelid away from the eyeball, therefore, the blepharospasm turns the eyelid outwards of its normal margins.

Paralytic ectropion is common for the palsy and paralysis of the facial nerve where the lower eyelid is on the loose downwards. As a result of the impossibility of the eyelid to close completely, lagophthalmus is present [6].

Senile ectropion of the lower eyelid is common on elderly people as a result of the decreased muscle tonus of the orbicularis oculi muscle and other tissues that compose the eyelid [2] [3].

Cicatrix ectropion appears as a result of the cicatrix changes on the skin of the eyelids, as a result of injuries, burnings, anthrax and ulcerative dermatitis [1]. Treatment method of ectropions is related to the causative agents, in spastic and paralytic ectropion the first choice treatment is the elimination of the causative agents, if this method is not successful then surgery is performed, while in the senile and cicatrix ectropion, the treatment is exclusively surgical. In the initial phase, surgical treatment is very successful in both aesthetic and functional aspects. There are various surgical methods that are used to treat ectropion, such

as: 1) Punctal cauterly; 2) Lazy-T procedure; 3) Horizontal lid shortening; 4) Kuhnt-Szymanowski procedure; 5) Medial conjunctivoplasty.

2. Materials and Methods

This study includes patients suffering from senile ectropion (**Figure 1**), who were treated surgically at Polyclinic “SHOSHI” in Prishtina. Our study includes 19 patients suffering from senile ectropion, out of which, 17 were older than 75 years old and in those patients the ectropion was preset on both lower eyelids, while 2 patients were under 75 years old and the ectropion was present only on one side lower eyelid.

The method that has been used the most in this case study is the horizontal lid shortening in all eyelid layers. Laboratory and ophthalmologic examinations and surgical procedure plan were performed in all patients prior to surgery. The surgical interventions were performed under local anesthesia with Lidocain 2%, 2.0 mmL, applied on the lower eyelid, sub-dermal and under the tarsus. The eyelid was fixed using the chalazion tweezers, 3 - 4 mm from the outer angle; we performed a triangle-like-incision, 3 - 4 mm in diameter along the whole depth of the eyelid. The suturing was done in three layers: the skin, the tarsus and the tarsal conjunctiva, using 6.0 vicryl sutures (**Figure 2** and **Figure 3**).

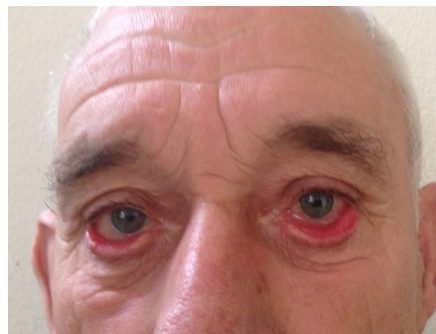

Figure 1. Bilateral ectropion, irritated conjunctiva and the presence of tears.

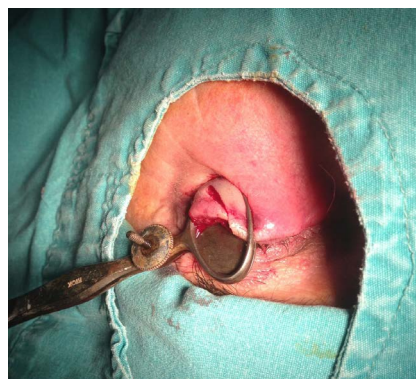

Figure 2. Local anesthesia application, the eyelid fixation using the chalazion tweezers and the incision of all lid layers.

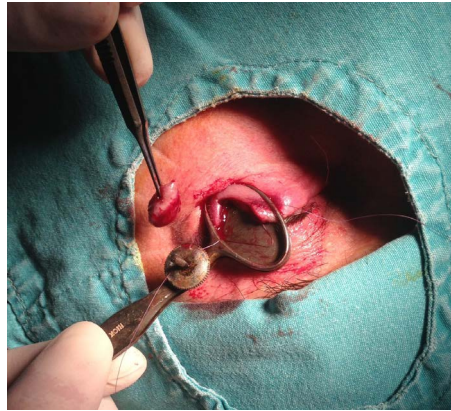


Figure 3. The removed part of the eyelid and the three layer suturing of the eyelid.

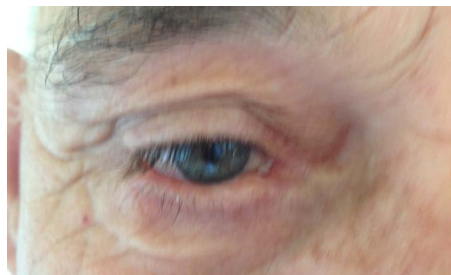

Figure 4. The state of the patient 2 weeks after the sutures' removal.

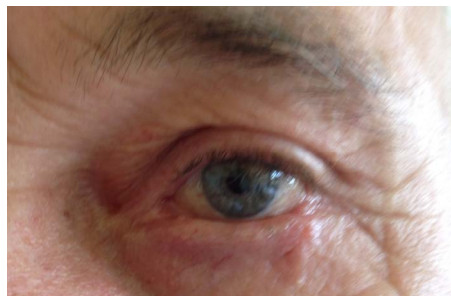

Figure 5. The state of the patient 2 weeks after the sutures' removal.

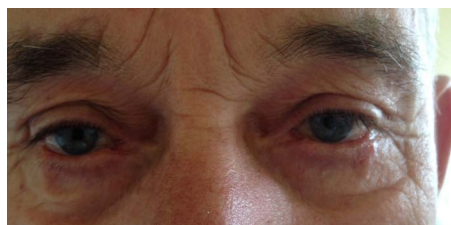

Figure 6. The state of the patient 2 weeks after the sutures' removal.

Post-operative treatment included the application of Dexamethasone-Gentamycin eye drops 6 × 1 drop and ointment one time per day, for 2 weeks.

The sutures we removed after two weeks and there we neither operative nor post-operative complications. The eyelid fitted the eyeball perfectly; the lacrimal puncta were on the physiological levels, the conjunctiva was smooth and moist (Figures 4-6).

3. Purpose

The purpose of this case report study is to show the success of the surgical treatment of ectropion, a procedure that is mainly performed so the tear elimination is enabled, and there are no tears present constantly. The surgical treatment still remains the first choice treatment on senile and cicatrix ectropion [2] [3] [4].

4. Conclusion

In old patients where the eyelid is turned outwards its margin, conjunctiva is constantly irritated, thickened and dry, the best method of treatment is the surgical treatment, making it possible for the tears to drain properly [7]. Ectropion's surgical treatment remains a golden standard of treatment [7]. As also shown by our research the success rate of the surgical treatment of ectropion is very high.

References

- [1] Caviggioli, F., Klinger, F., Villani, F., et al. (2008) Correction of Cicatricial Ectropion by Autologous Fat Graft. *Aesthetic Plastic Surgery*, **32**, 555-557. <https://doi.org/10.1007/s00266-008-9117-y>
- [2] Miletić, D., Elabjer, B.K., Bosnar, D. and Busić M. (2010) Our Approach to Operative Treatment of Lower Lid Ectropion. *Acta Clinica Croatica*, **49**, 283-287.
- [3] Vallabhanath, P. and Carter, S.R. (2000) Ectropion and Entropion. *Current Opinion in Ophthalmology*, **11**, 345-351. <https://doi.org/10.1097/00055735-200010000-00010>
- [4] Fea, A., Turco, D., Actis, A.G., De Sanctis, U., Actis, G. and Grignolo, F.M. (2013) Ectropion, Entropion, Trichiasis. *Minerva Chirurgica*, **68**, 27-35.
- [5] Sommer, F. (2009) Surgical Correction of Eyelid Malpositions. *Klinische Monatsblätter Für Augenheilkunde*, **226**, 529-540. <https://doi.org/10.1055/s-0028-1109512>
- [6] Piskiniene, R. (2006) Eyelid Malposition: Lower Lid Entropion and Ectropion. *Medicina*, **42**, 881-884.
- [7] Brady, K.M., Patrinely, J.R. and Soparkar, C.N. (1998) Surgery of the Eyelids. *Clinics in Plastic Surgery*, **25**, 579-586.