

Eye Rubbing as a Possible Cause of Clinical Progressive Keratoconus in a Forme Fruste Keratoconic Family

George D. Kymionis^{1,2}, Konstantinos I. Tsoularas^{1*}, Stella V. Blazaki¹,
Michael A. Grentzelos¹

¹Vardinoyiannion Eye Institute of Crete (VEIC), Faculty of Medicine, University of Crete, Heraklion, Crete, Greece

²Department of Ophthalmology, Bascom Palmer Eye Institute, University of Miami, Miami, FL, USA
Email: [*tsoularas@yahoo.gr](mailto:tsoularas@yahoo.gr)

Received 30 December 2014; accepted 9 February 2015; published 11 February 2015

Copyright © 2015 by authors and Scientific Research Publishing Inc.

This work is licensed under the Creative Commons Attribution International License (CC BY).

<http://creativecommons.org/licenses/by/4.0/>



Open Access

Abstract

We report a case of a 21-year-old male patient who underwent corneal cross-linking (CXL) due to bilateral progressive keratoconus. Topographical screening of his family members was performed for the detection of possible familial keratoconus and showed abnormal topographical patterns resembling to Forme Fruste Keratoconus (FFK) in all the members of his family. The reported keratoconic patient that underwent CXL was the only individual of this family that referred eye rubbing in his personal ocular history; ocular and medical history of the other family members was clear. Eye rubbing could be a possible adjuvant risk factor that contributes to conversion of FFK to clinical progressive keratoconus.

Keywords

Eye Rubbing, Family, Forme Fruste, Keratoconus, Topography

1. Introduction

Although keratoconus appears as an independent and isolated disorder, there are many keratoconic cases related with atopy, connective tissue disorders, referred eye rubbing and contact lens intolerance [1]. Despite the fact that etiology of keratoconus is not yet elucidated, inheritance and environmental factors seem to contribute to its pathogenesis [1]. Previous studies have already shown that familial pattern of keratoconus is possible and the in-

*Corresponding author.

cidence of familial keratoconus in keratoconic patients is estimated at 6% - 8% [2]. In these cases familial keratoconus inheritance follows the autosomal dominant and/or recessive pattern [2].

Eye rubbing is deemed a significant predictor for keratoconus progression and it is considered abnormal in connection with frequency, intensity and duration [3]. McMonnies maintained that rubbing could cause thermal effect to cornea that might increase collagenase activation [3]. It is also supported that rubbing-related mechanical epithelial trauma is responsible for the release of inflammatory mediators, which contribute to keratoconus pathogenesis [3].

In this case we present a keratoconic patient's family in which all members (including the two parents and their four children) are affected by *Forme Fruste Keratoconus (FFK)* documented by Dual-Scheimpflug topography. Clinical progressive keratoconus was evident in the only family member that reported eye rubbing.

2. Case Report

A 21-year-old male with recently diagnosed bilateral progressive keratoconus referred to our institute with gradually decreased visual acuity during the last six months. He had never used any spectacles or contact lenses (CL). Medical history was negative for any keratoconus-associated disease; however he mentioned chronic allergic conjunctivitis and bilateral eye rubbing. Uncorrected distance visual acuity (UDVA) was 20/100 and 10/150 in his right and left eye, respectively. Best spectacle corrected visual acuity (BSCVA) was 20/25 with manifest refraction of $+0.25 - 3.50 \times 70^\circ$ in his right eye not improving with rigid gas permeable (RGP) CL trial, while BSCVA was 20/40 with manifest refraction of $+1.50 - 6.50 \times 110^\circ$ in his left eye improving to 20/25 with RGP CL trial. Keratometry readings (Galilei dual-Scheimpflug analyzer, Ziemer Ophthalmic Systems AG, Port, Switzerland) were 47.79D/44.29D and 52.81D/46.56D in the right and left eyes, respectively. Minimum corneal thickness (MCT) measured by ultrasound pachymetry (Sonogage Corneo Gage Plus, Cleveland, Ohio) was 451 μm and 429 μm for the right and left eyes, respectively. Slit lamp examination showed no other anterior or posterior abnormalities. The patient underwent uneventful corneal cross-linking (CXL) [4].

As part of an ongoing research protocol of our institute concerning topographical screening of keratonic patients' families, all of the patient's family members were recruited to undergo slit lamp examination and topographical analysis of their eyes for the detection of FFK [5]. Institutional Review Board approval was obtained and all members were appropriately informed before their participation in the current study, and they gave written informed consent in accordance with institutional guidelines, according to the Declaration of Helsinki. Ophthalmological and topographical data of the participants are shown in **Table 1**. Axial curvatures of the family members are shown in the provided pedigree tree chart (**Figure 1**).

Table 1. Demographical, ophthalmological and topographical data of the family individuals.

*F/M	Age	Eye	†Ks (†D)	§Kf (D)	¶Pachy (μm)	**I-S (D)	Eye rubbing	Allergy	††A/K class
A1	57	OD	43.75	42.29	472	1.64	-	-	††FFK
		OS	43.04	42.64	474	0.92	-	-	FFK
A2	47	OD	44.40	43.81	513	1.09	-	-	FFK
		OS	44.58	43.61	504	2.21	-	-	FFK
B1	28	OD	45.97	44.81	465	2.85	-	-	FFK
		OS	46.29	44.28	470	2.69	-	-	FFK
B2	26	OD	42.63	42.09	485	3.33	-	-	FFK
		OS	44.75	43.04	483	2.59	-	-	FFK
B3	23	OD	44.71	43.38	474	1.08	-	-	FFK
		OS	43.95	43.45	466	2.06	-	-	FFK
B4	21	OD	47.79	44.29	451	10.40	+	-	1
		OS	52.81	46.56	429	15.67	+	-	2

*F/M = Family member; †Ks = Steep keratometric values; †D = diopters; §Kf = Flat keratometric values; ¶Pachy = Thinnest corneal pachymetry; **I-S index = Inferior-Superior keratometric index; ††A/K class = Amsler-Krumeich classification stage; ††FFK = *Forme Fruste Keratoconus*; OD = right eye; OS = left eye.

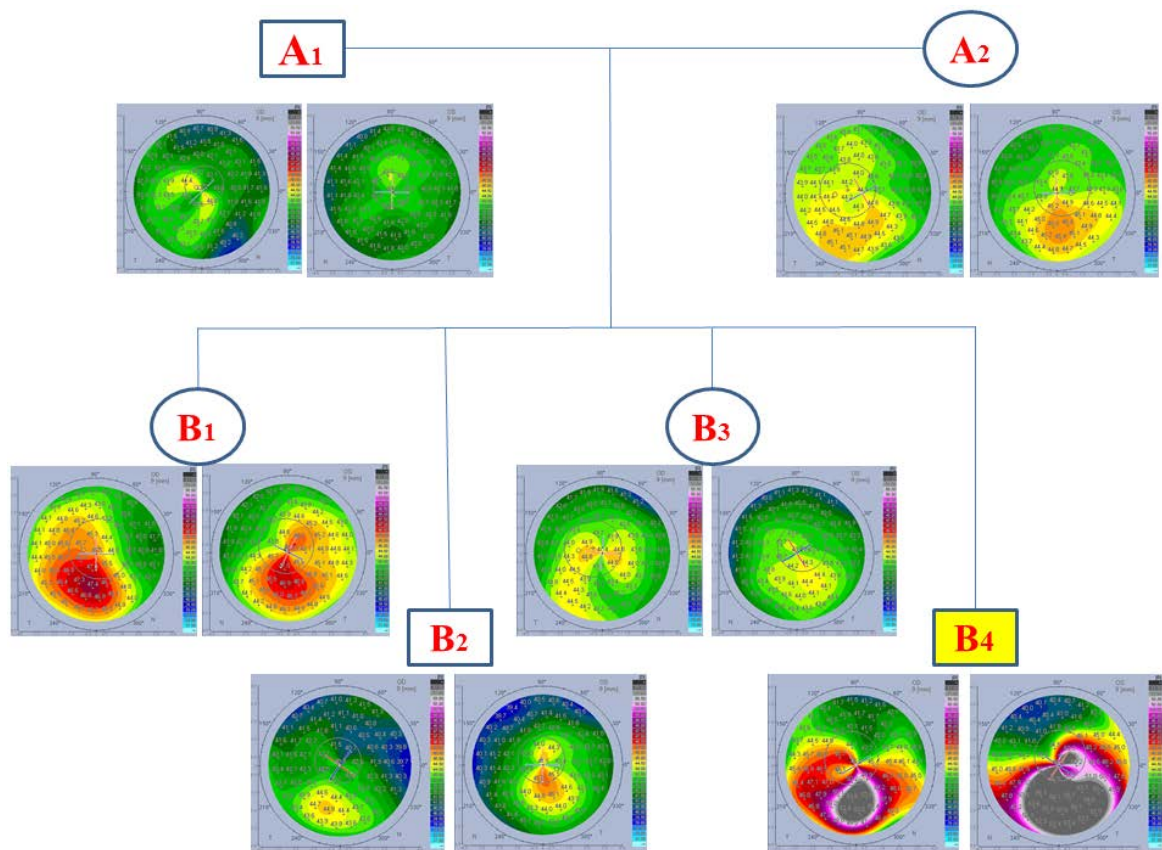


Figure 1. Pedigree tree chart of the keratoconic family; topographical axial curvatures are displayed below every family member. The highlighted B4 individual represents the CXL treated keratoconic patient.

Demographic and topographical data of the participants were collected in an Excel spreadsheet (Microsoft, Redmond, WA). SPSS software for Windows version 18.0 (SPSS, Inc, Chicago, IL) was used for statistical analysis of the results.

All family members' eyes were categorized as FFK, apart from the treated with CXL keratoconic patient; his right and left eye was classified with the Amsler-Krumeich classification as stage 1 and 2 respectively [6]. Mean age of family members was 33.67 ± 13.46 . All members' eyes had clear cornea, with no clinical signs or symptoms of keratoconus. Slit lamp showed no sign of atopic disease (e.g. chronic allergic conjunctivitis) in all family members. None of the family members used any spectacles or contact lenses; none of them was aware of their possible refractive error. Past ocular history was negative for any ocular disease or previous ocular surgery in all family members; medical history was negative for any systemic disease possibly correlated with keratoconus (e.g. collagen tissue disorders and atopy). The keratoconic patient that underwent CXL was the only member of the family that reported chronic allergic conjunctivitis and eye rubbing in both eyes.

All eyes included in our case had abnormal topographic patterns. One eye had central-superior steepening, four eyes had inferior steepening and seven eyes had asymmetric bowtie with skewed radial axes and inferior steepening. Mean steep and flat keratometry values were $45.39\text{D} \pm 2.74\text{D}$ and $43.69\text{D} \pm 1.22\text{D}$, respectively. Mean thinnest corneal pachymetry was $473.83 \mu\text{m} \pm 22.04 \mu\text{m}$. Mean Inferior-Superior asymmetric index was $3.88\text{D} \pm 4.49\text{D}$.

3. Discussion

There are many studies in the literature analyzing familial keratoconus [7]. Most of the currently published studies were performed for the detection of keratoconus genetic background [7]. Although genetic familial pattern of keratoconus has not been established yet, other environmental triggering factors (e.g. eye rubbing and atopy) have been also correlated with keratoconus development and progression [8].

FFK is characterized as subclinical form of keratoconus, which does not reveal any symptoms and remains unnoticed since corneal topography is undertaken (including asymmetric bowtie with a skewed radial axis) [6]. Visual acuity of 20/20 is also achievable with spectacle correction and there is absence of characteristic keratoconic clinical signs while performing slit-lamp examination and corneal pachymetry [6]. According to keratoconus classification based on disease evolution, it should be referred that FFK is a different condition from the early form of keratoconus in which corneal thinning is in progress while cornea scarring is not yet detectable [6].

In our case we present a keratoconic patient's family that all of its members diagnosed with FFK. The CXL-treated patient was the only member of this family that reported eye rubbing.

All family members had bilateral keratoconus according to the topographic findings, while mean thinnest corneal pachymetry was $473.83 \pm 22.04 \mu\text{m}$; therefore this family represents a model of familial FFK. The inheritance pattern of this family seems to be apparent dominant due to the fact that all the family members have diagnosed with a form of keratoconus. The unawareness of these family members about keratoconus disease and their refractive error strengthens the argument that there are many undetected individuals or even family members in the general population that will potentially develop keratoconus.

Rabinowitz reported that keratoconus prevalence is 0.1% and more than 6% in general population and relatives of keratoconic patients, respectively [1]. Considering that nowadays FFK is mainly detected in possible refractive candidates, it could be supposed that more individuals would have been ideally detected when general population was screened by corneal topography. Concerning the keratoconic patients' relatives, it is clarified that this subgroup of population should be topographically screened for the early detection and follow up of these undiagnosed keratoconic cases. Potential keratoconus progression could be managed by stabilization of their corneas with CXL treatment.

4. Conclusion

In conclusion, this is the first report of identification of a keratoconic patient's family that all of its members were diagnosed with FFK. Eye rubbing may converse FFK to clinical keratoconus.

Conflict of Interest

None of the authors has conflict of interest with the submission.

Funding

No financial support was received for the submission.

References

- [1] Rabinowitz, Y.S. (1998) Keratoconus. *Survey of Ophthalmology*, **42**, 297-319. [http://dx.doi.org/10.1016/S0039-6257\(97\)00119-7](http://dx.doi.org/10.1016/S0039-6257(97)00119-7)
- [2] Steele, T.M., Fabinyi, D.C., Couper, T.A. and Loughnan, M.S. (2008) Prevalence of Orbscan II Corneal Abnormalities in Relatives of Patients with Keratoconus. *Clinical Experimental Ophthalmology*, **36**, 824-830. <http://dx.doi.org/10.1111/j.1442-9071.2009.01908.x>
- [3] McMonnies, C.W. (2009) Mechanisms of Rubbing-Related Corneal Trauma in Keratoconus. *Cornea*, **28**, 607-6015. <http://dx.doi.org/10.1097/ICO.0b013e318198384f>
- [4] Wollensak, G., Spoerl, E. and Seiler, T. (2003) Riboflavin/Ultraviolet-A-Induced Collagen Crosslinking for the Treatment of Keratoconus. *American Journal of Ophthalmology*, **135**, 620-627. [http://dx.doi.org/10.1016/S0002-9394\(02\)02220-1](http://dx.doi.org/10.1016/S0002-9394(02)02220-1)
- [5] Saad, A. and Gatinel, D. (2010) Topographic and Tomographic Properties of Forme Fruste Keratoconus Corneas. *Investigative Ophthalmology & Visual Science*, **51**, 5546-5555. <http://dx.doi.org/10.1167/iovs.10-5369>
- [6] Amsler, M. (1946) KeratoconeClassiqueetKeratoconeFruste, Arguments Unitaires. *Ophthalmologica*. **111**, 96-101. <http://dx.doi.org/10.1159/000300309>
- [7] Nielsen, K., Hjortdal, J., Pihlmann, M. and Corydon, T.J. (2013) Update on the Keratoconus Genetics. *Acta Ophthalmologica*, **291**, 106-113. <http://dx.doi.org/10.1111/j.1755-3768.2012.02400.x>
- [8] Balasubramanian, S.A., Pye, D.C. and Willcox, M.D. (2013) Effects of Eye Rubbing on the Levelsof Protease, Protease Activity and Cytokines in Tears: Relevance in Keratoconus. *Clinical and Experimental Optometry*, **96**, 214-218. <http://dx.doi.org/10.1111/cxo.12038>

Scientific Research Publishing (SCIRP) is one of the largest Open Access journal publishers. It is currently publishing more than 200 open access, online, peer-reviewed journals covering a wide range of academic disciplines. SCIRP serves the worldwide academic communities and contributes to the progress and application of science with its publication.

Other selected journals from SCIRP are listed as below. Submit your manuscript to us via either submit@scirp.org or **Online Submission Portal**.

