

# A Recurrent Solitary Exostosis of the Distal End of the Right Radius: A Case Report with a 17-Year Follow-Up

Raphael Dallo Gogoua<sup>1\*</sup>, Moctar Traoré<sup>1</sup>, Maurice Kouamé<sup>1</sup>, Francois D'Horpock<sup>2</sup>, Michel Anoumou<sup>1</sup>

<sup>1</sup>Orthopedics Traumatology Department, Treichville Teaching Hospital, Abidjan, Côte d'Ivoire

<sup>2</sup>Treichville Teaching Hospital, Abidjan, Côte d'Ivoire

Email: \*gogouad@yahoo.fr, \*gogouadallo60@gmail.com

**How to cite this paper:** Gogoua, R.D., Traoré, M., Kouamé, M., D'Horpock, F. and Anoumou, M. (2017) A Recurrent Solitary Exostosis of the Distal End of the Right Radius: A Case Report with a 17-Year Follow-Up. *Open Journal of Orthopedics*, 7, 140-145.

<https://doi.org/10.4236/ojo.2017.75016>

**Received:** February 3, 2017

**Accepted:** May 24, 2017

**Published:** May 27, 2017

Copyright © 2017 by authors and Scientific Research Publishing Inc.

This work is licensed under the Creative Commons Attribution International License (CC BY 4.0).

<http://creativecommons.org/licenses/by/4.0/>



Open Access

## Abstract

Solitary exostosis is a benign tumor usually encountered in children and adolescents. Its treatment is based on complete surgical excision which ensures complete healing. The resumption of a tumor process raises two questions: is it a recurrence or a malignant transformation into chondrosarcoma? We report a case of a resumption of the tumor process of solitary exostosis of the lower metaphysis of the right radius in a 33-year-old patient. This recurrence occurred 10 years after the first surgery and was accompanied by signs of compression of the median nerve and a major bone remodeling raising fears of malignant transformation. But histological examination performed during the excision confirmed the benignity of this lesion. The long-term follow-up examination of 17 years found a patient in a good general condition with a satisfactory local condition. The malignant transformation of solitary exostosis is an exceptional event. Thus, faced with a resumption of the tumor process after excision of solitary exostosis, the inadequacy of the first excision remains the first diagnostic hypothesis.

## Keywords

Solitary Exostosis, Benign Bone Tumors, Chondrosarcoma

## 1. Introduction

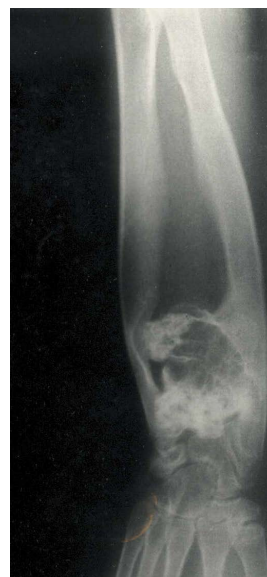Solitary exostosis is a bony outgrowth developed on conjugation cartilage. It is a benign tumor usually encountered in children and adolescents [1] [2]. Its clinical symptomatology is made of a hard tumor, usually painless, without inflammatory sign. Sometimes the tumor can be voluminous becoming unsightly or ac-

accompanied by sign of compression of neighboring soft or bone tissues, requiring then surgical excision. The postoperative course is usually simple with total healing. This course may be marked by a relapse raising fears of malignant transformation.

The case that we report is that of a postoperative recurrence of exostosis of the lower metaphysis of the right radius with a 17-year follow-up.

## 2. Observation

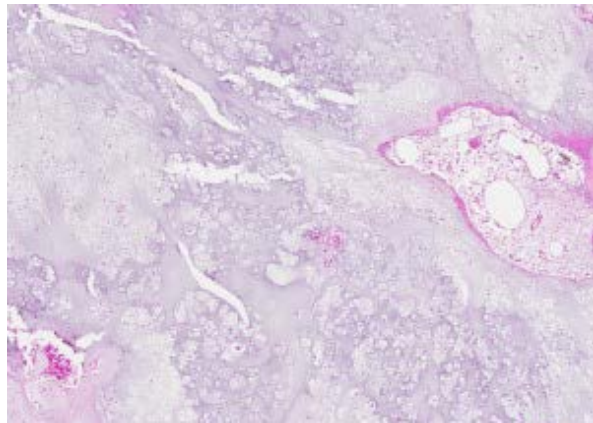
K B, a 33-year-old right-hander, a student was operated on 04 February 1990 (at the age of 7) of exostosis of the distal metaphysis of the radius. An excision was then performed. 10 years later (1 September 2000), he consulted for a voluminous tumor of identical seat; this voluminous tumor was painful and unsightly. The skin was shiny and there were acroparesthesias such as tingling, numbness, burning; which evoked a suffering of the Median Nerve. There was also an onset of amyotrophy of the external theenarian muscles. On the standard X-ray (**Figure 1**), we noted a large bony outgrowth of the distal radial metaphysis. This bony excrescence separated the radius from the ulna. The ulna curved. The cortex of the tumor was prolonged with that of the radial diaphysis. This bone tumor was heterogeneous and associated with gaps and areas of osteosclerosis. This clinical and radiological symptomatology made suggest a malignant tumor. Another excision of the tumor was then decided. During the surgical procedure, we noted a large bony excrescence covered with a thin layer of articular cartilage, pushing back the anterior soft tissues (flexors, radial artery, median nerve). Total excision of the tumor mass was performed. The bone continuity was achieved by a plate screwed with an autologous bone graft removed from the homolateral olecranon. The pathological analysis of the surgical specimen confirmed the benign character of the tumor. On the blades were noted sections of connective




**Figure 1.** Recurrent exostosis (10 years after first excision) (X-ray performed on 01 September 2000).

tissue performed from outside within a perichondrium, a chondroid cap, and spongy bone; the chondroid tissue showed an important chondroblastic activity without cytonuclear anomaly (**Figure 2**).

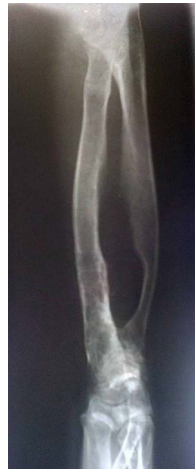At the clinical and radiological control on 27 April 2016, 17 years later, the local skin condition and the X-ray of the wrist were normal (**Figures 3-6**). There was no nervous or muscular sequelae. The movements of pronosupination were slightly limited; which does not prevent the patient from practicing basketball as his hobby. These results confirmed the good postoperative evolution of this recurrence.



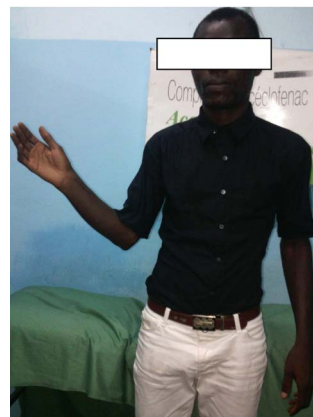**Figure 2.** Anatomopathological aspect of connective tissue made from the outside within a perichondrium, a chondroid cap, and spongy bones; the chondroide tissue presenting an important chondroblastic activity without cytotoxic abnormality.



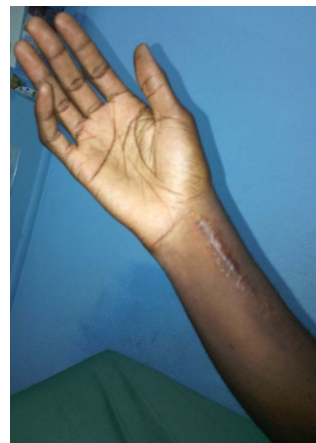**Figure 3.** 17-year follow-up X-ray control (X-ray performed on 27 April 2016).



**Figure 4.** Radiographic control after removal of 17-year follow-up material (X-ray of 31 May 2016).



**Figure 5.** Wrist view at 17-year follow-up.



**Figure 6.** Wrist view at 17-year follow-up.

### 3. Discussion

The long evolutionary stability of our case confirmed the diagnosis of benign

histology. We are thus faced with a case of recurrence of solitary osteogenic-exostosis. This recurrence no longer presented the usual characteristics of solitary exostosis [3] [4]. There was no longer clinically and radiologically a cartilaginous cap, a bone base of sessile or pedicled implantation. Usually this tumor is painless and without inflammatory sign; in our patient there were signs of inflammation and signs of the Median nerve compression. Bone remodeling associated gaps and areas of osteosclerosis. This symptomatology was suspicious because, faced with solitary exostosis already operated, two hypotheses must be considered: either it is a recurrence related to an inadequacy of exostosectomy, or it is a malignant transformation into chondrosarcoma or histiosarcoma. The histological analysis had confirmed the benign character of the tumor. Histology is therefore essential when faced with a recurrence of exostosis. The malignant transformation into chondrosarcoma or histiosarcoma is exceptional as reported by some authors: 1% according to Strauss [4], 7.5% according to Dahlin [2]. Esadki [5], out of a series of 76 operated solitary exostoses, reported no recurrence or malignant transformation. The diagnosis of malignant transformation is suggested by the increase of the volume of the tumor which assumes an inflammatory character. Radiography can show bone erosions, calcifications, anarchic development and a crossing of the cortex of exostosis. Ultrasound, CT and MRI have the advantage of specifying the thickness of the cartilage cap. Beyond 2 cm, this thickness would be in favor of malignancy [6] [7]. These imaging tests could not be performed in our patient. At that time these techniques were not yet popularized in our hospitals. In all cases, only histology confirms the diagnosis.

In our patient it was therefore a recurrence. Our case shows that recurrence may complicate an inadequate exostosectomy. Our case also underlines the necessity of treating this tumor recurrence in a single period by complete excision. In the event of bone loss, bone graft [8] may be performed at the same time.

#### **4. Conclusion**

This case shows that if solitary exostosis recurs after excision, it is because this excision was probably incomplete. Hence the interest of a complete excision is in the case of solitary exostosis. It also confirms the rarity of the malignant transformation of solitary exostoses.

#### **Conflict of Interests**

The authors declare no conflict of interest.

#### **Author's Contributions**

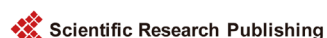The local ethics committee approved this study and all the authors contributed to the writing of this.

#### **Patient Consent**

The patient had given his consent for the case reports to be published.

## References

- [1] Languepin, A., Peyrou, P.L. and Houcke, M. (1980) Exostosant Disease and Solitary Osteogenic Exostoses. Medical and Surgical Encyclopedia, Paris, Elsevier.
- [2] Dahlin, D.C. and Unna, K.K. (1986) General Aspects and Data on 8522 Cases. In: Thomas, C.C., Ed., *Bone Tumors*, vol. 186, 4th Édition Publisher, Springfield, 227-257.
- [3] Malghem, J., Vande Berg, B., Noel, H. and Maldague, B. (1992) Benign Osteosarcomas and Exostoticchondrosarcomas: Evaluation of Cartilage Cap Thickness by Ultrasound. *Skeletal Radiology*, **21**, 33-37. <https://doi.org/10.1007/BF00243091>
- [4] Strauss, J., Chatard, C., Maillefert, J.F., Perret, T. and Tavernier, C. (1994) Exostosis and Exostosant Disease, about a Series of 22 Observations. *Rhum*, **46**, 296-274.
- [5] Essadki, B., Moujtahid, M., Lamine, A., Fikry, T., Essadki, O. and Zryoul, B. (2000) The Solitary Osteogenic Exostosis of the Members. Clinical Review of 76 Cases and Pathogenic Hypothesis. *Acta Orthopaedica*, **66**, 146-153.
- [6] Hudson, M., Springfield, D.S., Spanier, S., Enniking, W.H. and Hamlin, D.J. (1984) Benign Exostosis and Chondrosarcomes. Evaluation of Cartilage Thickness by CT. *Radiology*, **15**, 595-559. <https://doi.org/10.1148/radiology.152.3.6611561>
- [7] Bennani, L., Amine, B., Alaoui, H. and Hassouni, N. (2006) Solitary Exostosis of Humerus Associated with a Retractable Capsulitis of the Ipsilateral Shoulder. *Revue du Rhumatisme*, **73**, 1206. <https://doi.org/10.1016/j.rhum.2006.10.500>
- [8] Gogoua, D.R., Agoh, S., Traoré, M., Anoumou, M. and Varango, G. (2008) Sites of Autologus Bone Grafts in Orthopaedic Traumatology. Analysis of Complications. *Nigerian Journal of Orthopaedy and Traumatology*, **7**, 20-21.



**Submit or recommend next manuscript to SCIRP and we will provide best service for you:**

Accepting pre-submission inquiries through Email, Facebook, LinkedIn, Twitter, etc.

A wide selection of journals (inclusive of 9 subjects, more than 200 journals)

Providing 24-hour high-quality service

User-friendly online submission system

Fair and swift peer-review system

Efficient typesetting and proofreading procedure

Display of the result of downloads and visits, as well as the number of cited articles

Maximum dissemination of your research work

Submit your manuscript at: <http://papersubmission.scirp.org/>

Or contact [ojo@scirp.org](mailto:ojo@scirp.org)