

# Ultra-High Molecular Weight Polyethylene Tape Applied for Distal Humeral Condyle Fracture around Total Elbow Arthroplasty in Patients with Rheumatoid Arthritis: Report of Two Cases

Norio Yamamoto<sup>1\*</sup>, Mitsuhiro Takahashi<sup>2</sup>, Naohito Hibino<sup>1</sup>, Koichi Sairyo<sup>3</sup>

<sup>1</sup>Tokushima Prefecture Naruto Hospital, Tokushima, Japan

<sup>2</sup>Department of Orthopedics and Rehabilitation, Takamatsu Red Cross Hospital, Tokushima, Japan

<sup>3</sup>Department of Orthopedics, Institute of Health Biosciences, The University of Tokushima Graduate School, Tokushima, Japan

Email: \*[norio-yamamoto@umin.ac.jp](mailto:norio-yamamoto@umin.ac.jp)

Received 9 August 2015; accepted 7 September 2015; published 11 September 2015

Copyright © 2015 by authors and Scientific Research Publishing Inc.

This work is licensed under the Creative Commons Attribution International License (CC BY).

<http://creativecommons.org/licenses/by/4.0/>



Open Access

---

## Abstract

Managing fractures of distal humerus in patients with rheumatoid arthritis (RA) is technically challenging. Total elbow arthroplasty (TEA) is one of the treatment options for these fractures. While elbow motion is largely regained by TEA, comminuted condyle fragments are often ignored. Although numerous approaches for repair of condylar fragments around TEA are described, any universal fixation strategy for these fractures has not been established. This report describes, for the first time, application of an ultra-high molecular weight polyethylene (UHMWPE) tape for the treatment of distal humerus fracture in 2 patients with rheumatic elbow arthropathy. The post-operative clinical courses were good. Radiographs showed bony union of the condylar fragments without loosening in two cases. Because of its flat configuration, softness, and flexibility, UHMWPE tape is a promising material for stabilizing fracture of the distal humerus associated with TEA.

## Keywords

Total Elbow Arthroplasty, Distal Humerus, Ultra-High Molecular Weight Polyethylene, Rheumatoid Arthritis

---

\*Corresponding author.

## 1. Introduction

Managing fractures of distal humerus in patients with rheumatoid arthritis (RA) is technically challenging as the articular surface should be reconstructed for joint function while the muscular origins on the condyle are retained for functional elbow and wrist movement. Total elbow arthroplasty (TEA) is one of the treatment options for these fractures [1]-[4]. While elbow motion is largely regained by TEA, comminuted condyle fragments are often ignored if they exist. On the other hand, humeral condyle fracture often occurs in primary TEA, especially during “box cutting” of the condyle, mostly due to peri-articular osteoporosis [3] [4].

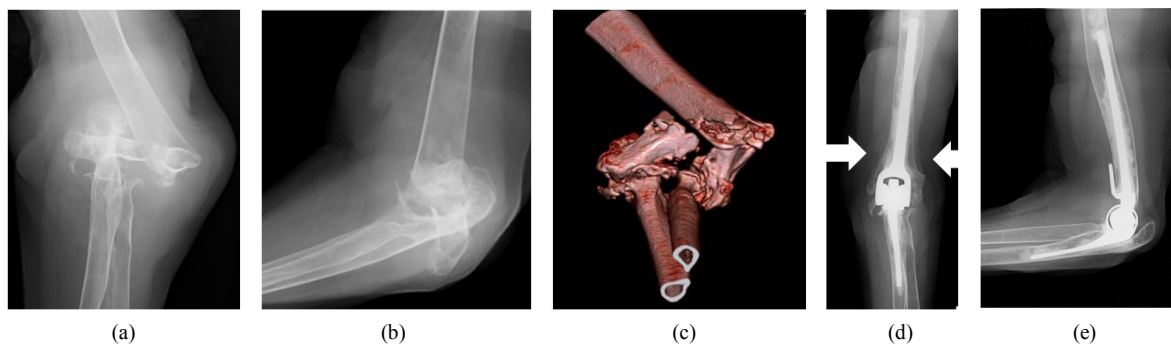
Although numerous approaches for repair of distal humerus fracture around TEA were described in the literatures, complications such as breakage, back out, migration, irritation of the fixation materials, nonunion, and bursitis had been reported. Any comprehensive fixation strategy for these fractures has not been established. Here, we describe, for the first time, fractures of the distal humerus around TEA are successfully managed by using ultra-high molecular weight polyethylene (UHMWPE) tape (NESPLON Cable System, Alfresa Pharma Corporation, Osaka, Japan) in 2 patients with rheumatic elbow arthropathy, and review literatures.

## 2. Case Reports

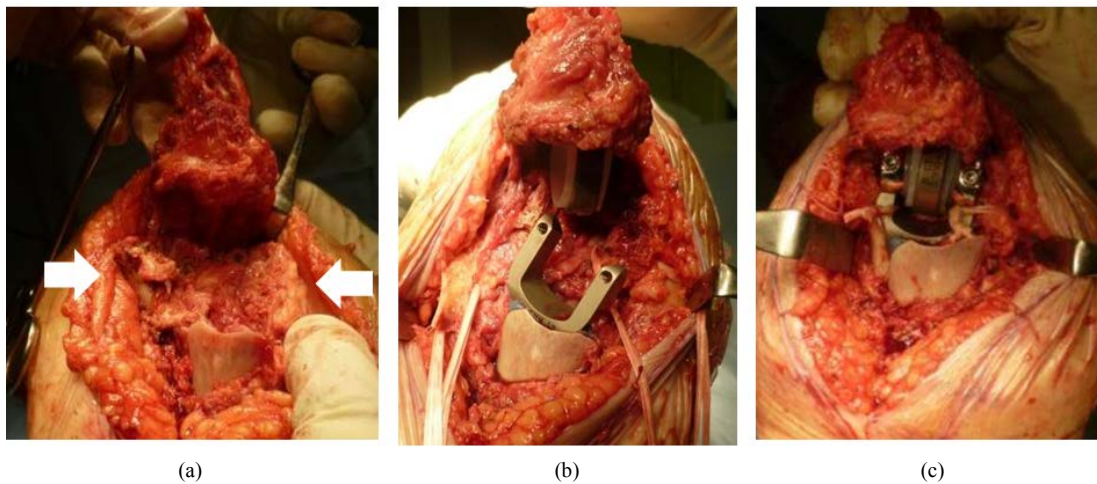
### Case 1

A 74-year-old right-handed woman with a 50-year history of RA fell onto her left hand. She had been diagnosed with arthritis mutilans showing Steinbrocker’s radiographic stage IV and functional class II. Her condition had been controlled without prednisolone or biologic therapy and she had previously suffered a femoral hip fracture. Physical examination revealed swelling and deformity around the left elbow with abnormal mobility but no ulnar neuropathy. The ipsilateral left wrist had an extension-flexion range of 20° to 20°. Radiographs revealed a type C2-1 distal humeral fracture according to the AO classification system and stage IV RA according to Mayo classification of RA [5] (**Figure 1**). The fracture was complicated by comminution of the condyle, osteoporosis, and severe rheumatic changes, making open reduction and internal fixation difficult. TEA with Discovery elbow system (Biomet Orthopedics, Warsaw, IN), but not Coonrad-Morrey prosthesis, was chosen because of its merits that enabled to stabilize the condylar fragments to the humeral component, after which the humeral and ulnar components could be coupled.

Surgery was performed using the posterior approach [6]. The ulnar nerve was protected throughout the procedure. The articular surfaces were grossly resorbed and soft tissues around the elbow, including the collateral ligaments, were destroyed. The fragments of condyle and epicondyle were exposed in continuity with the periosteum and the origins of the forearm musculature (**Figure 2**). Respective UHMWPE (5 mm wide and 0.6 mm thick) tapes were placed circumferentially around the medial and lateral fragments. The humeral component was set on the distal end of the diaphyseal fragment by the flange of the implant, which led to 1 cm of estimated humeral shortening. After humeral and ulnar components being cemented, these tapes were tied to the respective intercondylar arm of the humeral component and tightened using a double loop-sliding knot technique with tension strength of approximately 30N, as indicated by a tension measuring device (**Figure 2**). Finally, the humeral and ulnar components were coupled. The functional integrity and stability of the elbow were restored by fixing the condylar fragments.



**Figure 1.** Preoperative anteroposterior (a) and lateral (b) radiographs of the elbow in Case 1. (c) Preoperative three-dimensional computed tomography showing an AO type C2-1 distal humeral fracture and stage IV arthritic involvement. Anteroposterior (d) and lateral (e) radiographs at 19 months follow-up showing the fragments union (arrow).



**Figure 2.** (a) Intraoperative images of the elbow surgery using Campbell's posterior approach in Case 1 showing the medial (left arrow) and lateral condylar fragments (right arrow); (b) Two pieces of UHMWPE tape were placed circumferentially around the condylar fragments; (c) The tapes were placed in the intercondylar arm of the humeral component and tightened.

Postoperative radiographs showed restoration of the humeral alignment and the fracture fragments. A splint was worn for 1 week after surgery and gentle passive range of motion (ROM) exercise was then started. Active ROM exercise was initiated 4 weeks after surgery. At the 19 months follow-up, the patient could manage daily activities with some limitations associated with the RA. ROM was improved to an extension-flexion (EF) range of  $-35^{\circ}$  to  $135^{\circ}$  and a supination-pronation (SP) of  $35^{\circ}$  to  $70^{\circ}$ . DASH score [7] was 4.5, and the Mayo elbow performance score (MEPS) [8] was 100. Radiographs showed bony union of the fractures without implant loosening (Figure 1).

#### Case 2

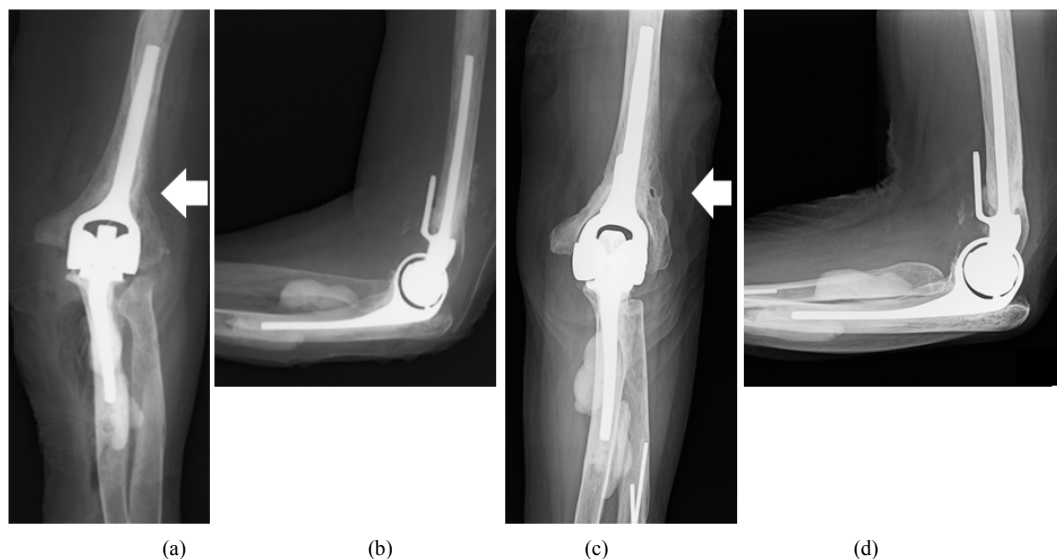
A 76-year-old woman with RA (Steinbrocker's radiographic stage III and functional class III) underwent TEA for destructive arthritis of the left elbow. Preoperative MEPS was 15 with EF range of  $-15^{\circ}$  to  $105^{\circ}$  and SP of  $90^{\circ}$  to  $50^{\circ}$ . Surgery was performed using the posterior approach [6]. Box-cutting of the distal humerus was completed for the humeral component. A lateral epicondylar fracture at the remaining lateral bone column after the box cutting occurred during cementing of the humeral component. The fracture fragment was unstable due to the small bone contact area against tension from the extensor muscles over the lateral condyle. The lateral condylar fragment was fixed with one UHMWPE tape (5 mm wide and 0.6 mm thick) (Figure 3). After cementing of the ulnar component, the humeral and ulnar components were coupled. The functional integrity and stability of the elbow were maintained by fixing the lateral condylar fragment.

At the 2.5-year follow-up, MEPS was improved to 95 with EF range of  $-30^{\circ}$  to  $135^{\circ}$  and SP of  $80^{\circ}$  to  $60^{\circ}$ . The patient underwent ipsilateral total wrist fusion for wrist in RA. Radiographs showed bony union of the fracture without implant loosening (Figure 3).

### 3. Discussion

Linked TEA is one of the treatment options for complicated distal humeral fractures in elderly patients [1], and although it has gained widespread acceptance, various complications such as additional fractures have been reported [3] [4]. Peri-articular osteoporosis, which is common in patients with RA, inevitably increases intraoperative risks for fracture. Intraoperative fracture during TEA tends to occur at preparation or fixation of the humeral component [3]. Gill *et al.* described 3 cases of fracture in 78 linked TEAs for rheumatoid elbow (3.8%) in the United States [4]. On the other hand, Asian populations have smaller skeletons, which may lead to increase in fracture risk due to implant size limitations. Indeed, Ito *et al.* reported the incidence of fracture during TEA in Japanese patients was as high as 32.5% (13/40 cases) [3].

Repair of fracture around TEA or intraoperative fracture during TEA is technically demanding. Some authors suggested that neither mechanical strength nor functional outcome was impaired by resection of the humeral condyle [3] [9]. Furthermore, the anterior flange is thought to provide rotational stability in the Coonrad-Morrey prosthesis (Zimmer, Warsaw, IN) [10] and the epicondyles to condyle may not contribute to implant stability.



**Figure 3.** Immediate postoperative anteroposterior (a) and lateral (b) radiographs in Case 2 showing the lateral condylar fragment (arrow) fixed with UHMWPE tape. Anteroposterior (c) and lateral (d) radiographs at 2.5-year follow-up showing the fragments fused to the diaphysis (arrow).

Morrey *et al.* reported, on the contrary, that intraoperative fracture of the medial or lateral supracondylar bone column resulted in a high rate of aseptic loosening of the implant, and suggested that integrity of the distal end of the humerus and reconstruction of the bone columns were important for good prosthetic fixation and implant stability [11]. We are in agreement with the ideas that even when linked implants are used, the muscular origins on the condyle must be retained for preserving elbow and wrist function, and the medial or lateral supracondylar bone column must be reconstructed for long-term implant stability. Bone stock and congruity of the supracondylar bone column seem to have some advantages if revision TEA should be required in the future.

Numerous approaches for repair of distal humerus fracture around TEA are described in the literatures including plating, pinning, wiring, banding with non-absorbable thread, and screwing [3] [12], however, complications such as breakage, back out, migration, irritation of the fixation materials, nonunion, and bursitis have been reported. These complications frequently require a second surgical procedure for removal of the failed components. UHMWPE tape has been used as an alternative to steel wire to avoid such complications for fracture fixation of the patella, reattachment of the osteotomized greater trochanter in hip surgery [13], and augmentation of the posterior spinal reconstruction [14]. The biomechanical properties of UHMWPE tape have been tested extensively and are reported that both tensile strength and fatigue resistance were equivalent to that of steel wires and cables [15] [16]. Thus, UHMWPE tape provides sufficient strength of fracture fixation, which may enhance fracture healing and allow active motion exercise early after surgery. Due to its wide contact area for bone, the UHMWPE tape decreases the risk of bony cutout, which can occur during fixation of osteoporotic fragile bones in elderly patients. The effectiveness of the tape was reported to be equivalent to that of steel wire during spinal deformity correction [17]. In spinal fusion, the tape was rigidly fixed around metal rod, which decreased the incidence of implant loosening by mechanical stress and chemical effect [14] [17]. Although polyethylene thread may stretch and loosen when subjected to constant loads, experimental studies have proven that sufficient strength would be maintained until bone union [18]. In the two cases presented here, UHMWPE tape was safe and effective application for distal humeral fracture around TEA combined with osteoporotic fragile bone.

#### 4. Conclusion

In conclusion, good outcomes were obtained by applying UHMWPE tape in fixation for fractures of the distal humerus in rheumatic elbow arthropathy. Due to its softness, flexibility and flat configuration, UHMWPE tape should be considered as a feasible option for stabilization of distal humeral fracture around TEA.

## Conflict of Interests

The authors declare that there is no conflict of interests regarding the publication of this paper.

## References

- [1] Kamineni, S. and Morrey, B.F. (2005) Distal Humeral Fractures Treated with Noncustom Total Elbow Replacement. *The Journal of Bone and Joint Surgery (American)*, **87**, 41-50. <http://dx.doi.org/10.2106/jbjs.d.02871>
- [2] Jost, B., Adams, R.A. and Morrey, B.F. (2008) Management of Acute Distal Humeral Fractures in Patients with Rheumatoid Arthritis. A Case Series. *The Journal of Bone and Joint Surgery (American)*, **90**, 2197-2205. <http://dx.doi.org/10.2106/JBJS.G.00024>
- [3] Ito, H., Matsumoto, T., Yoshitomi, H., *et al.* (2007) The Outcome of Peri-Operative Humeral Condylar Fractures after Total Elbow Replacement in Patients with Rheumatoid Arthritis. *The Journal of Bone and Joint Surgery (British)*, **89**, 62-65. <http://dx.doi.org/10.1302/0301-620X.89B1.18264>
- [4] Gill, D.R. and Morrey, B.F. (1998) The Coonrad-Morrey Total Elbow Arthroplasty in Patients Who Have Rheumatoid Arthritis: A Ten- to Fifteen-Year Follow-Up Study. *The Journal of Bone and Joint Surgery (American)*, **80**, 1327-1335.
- [5] Morrey, B.F. and Adams, R.A. (1992) Semiconstrained Arthroplasty for the Treatment of Rheumatoid Arthritis of the Elbow. *The Journal of Bone and Joint Surgery (American)*, **74**, 479-490.
- [6] Campbell, W.C. (1932) Incision for Exposure of the Elbow Joint. *The American Journal of Surgery*, **15**, 65-67. [http://dx.doi.org/10.1016/S0002-9610\(32\)90997-0](http://dx.doi.org/10.1016/S0002-9610(32)90997-0)
- [7] Hudak, P.L., Amadio, P.C. and Bombardier, C. (1996) Development of an Upper Extremity Outcome Measure: The DASH (Disabilities of the Arm, Shoulder and Hand) [Corrected]. The Upper Extremity Collaborative Group (UECG). *American Journal of Industrial Medicine*, **29**, 602-608. [http://dx.doi.org/10.1002/\(SICI\)1097-0274\(199606\)29:6<602::AID-AJIM4>3.0.CO;2-L](http://dx.doi.org/10.1002/(SICI)1097-0274(199606)29:6<602::AID-AJIM4>3.0.CO;2-L)
- [8] Morrey, B.F. and Adams, R.A. (1995) Semiconstrained Elbow Replacement for Distal Humeral Nonunion. *The Journal of Bone and Joint Surgery (British)*, **77**, 67-72.
- [9] McKee, M.D., Pugh, D.M., Richards, R.R., *et al.* (2003) Effect of Humeral Condylar Resection on Functional Outcome after Semiconstrained Total Elbow Arthroplasty. *The Journal of Bone and Joint Surgery (American)*, **85**, 802-807.
- [10] Ramsey, M.L., Adams, R.A. and Morrey, B.F. (1999) Instability of the Elbow Treated with Semiconstrained Total Elbow Arthroplasty. *The Journal of Bone and Joint Surgery (American)*, **81**, 38-47.
- [11] Morrey, B.F., Bryan, R.S., Dobyns, J.H., *et al.* (1981) Total Elbow Arthroplasty: A Five-Year Experience at the Mayo Clinic. *The Journal of Bone and Joint Surgery (American)*, **63**, 1050-1063.
- [12] Ducrot, G., Ehlinger, M., Adam, P., *et al.* (2013) Complex Fractures of the Distal Humerus in the Elderly: Is Primary Total Elbow Arthroplasty a Valid Treatment Alternative? A Series of 20 Cases, *Orthopaedics & Traumatology: Surgery & Research*, **99**, 10-20. <http://dx.doi.org/10.1016/j.otsr.2012.10.010>
- [13] Jingushi, S., Kawano, T., Iida, H., *et al.* (2013) Reattachment of the Osteotomized Greater Trochanter in Hip Surgery Using an Ultrahigh Molecular Weight Polyethylene Fiber Cable: A Multi-Institutional Study. *Open Journal of Orthopedics*, **3**, 283-289. <http://dx.doi.org/10.4236/ojo.2013.36052>
- [14] Imagama, S., Ito, Z., Wakao, N., *et al.* (2012) Posterior Surgery for Adolescent Idiopathic Scoliosis with Pedicle Screws and Ultra-High Molecular Weight Polyethylene Tape: Achieving the Ideal Thoracic Kyphosis. *Journal of Spinal Disorders & Techniques*, Published Online. <http://dx.doi.org/10.1097/BSD.0b013e31826eaf09>
- [15] Dickman, C.A., Papadopoulos, S.M., Crawford, N.R., Brantley, A.G. and Gealer, R.L. (1997) Comparative Mechanical Properties of Spinal Cable and Wire Fixation Systems. *Spine*, **22**, 596-604. <http://dx.doi.org/10.1097/00007632-199703150-00004>
- [16] Marissen, R., Nelis, M., Janssens, M., Meek, M.D.M.E. and Maessen, J.G. (2011) A Comparison between the Mechanical Behavior of Steel Wires and Ultra High Molecular Weight Poly Ethylene Cables for Sternum Closure. *Materials Sciences and Applications*, **2**, 1367-1374. <http://dx.doi.org/10.4236/msa.2011.210185>
- [17] Takahata, M., Ito, M., Abumi, K., *et al.* (2007) Comparison of Novel Ultra-High Molecular Weight Polyethylene Tape Versus Conventional Metal Wire for Sublaminar Segmental Fixation in the Treatment of Adolescent Idiopathic Scoliosis. *Journal of Spinal Disorders & Techniques*, **20**, 449-455. <http://dx.doi.org/10.1097/BSD.0b013e318030d30e>
- [18] Matsumori, H., Ueda, Y., Koizumi, M., *et al.* (2010) Temporal Changes in the Tensile Strength of Ultra-High-Molecular-Weight Polyethylene Cable Embedded in Muscle Tissue. *Clinical Biomechanics*, **25**, 173-176. <http://dx.doi.org/10.1016/j.clinbiomech.2009.10.007>