

# Isolated Triquetrum Fractures: The Importance of Proper Roentgenograms in Ulnar Sided Wrist Pain

Guzelali Ozdemir<sup>1</sup>, Bekir Yavuz Ucar<sup>2</sup>, M. Halis Cerci<sup>3</sup>, Baris Yilmaz<sup>1</sup>, Kerem Basarir<sup>4</sup>

<sup>1</sup>Fatih Sultan Mehmet Training and Research Hospital, Istanbul, Turkey

<sup>2</sup>Sisli Florence Nightingale Hospital, Istanbul, Turkey

<sup>3</sup>Safa Hospital, Istanbul, Turkey

<sup>4</sup>Ankara University School of Medicine, Ankara, Turkey

Email: [bekiryavuzucar@gmail.com](mailto:bekiryavuzucar@gmail.com)

Received 13 June 2015; accepted 21 July 2015; published 24 July 2015

Copyright © 2015 by authors and Scientific Research Publishing Inc.

This work is licensed under the Creative Commons Attribution International License (CC BY).

<http://creativecommons.org/licenses/by/4.0/>



Open Access

---

## Abstract

Triquetrum fractures are the second most common carpal fractures after scaphoid. However they are seldom encountered due to their clinical symptoms and since they cause less functional disability. They can be misdiagnosed as soft-tissue injuries by considering the similar localization of pain and prolonged symptoms. The majority of triquetrum fractures can be diagnosed with direct X-ray. Obtaining three plane (anterior-posterior, lateral and oblique) X-rays is especially important in diagnosing dorsal chip fractures. Accurate diagnosis provides both controlling the symptoms with adequate immobilization, sufficient information of the patient in the acute period and preventing unnecessary diagnostic work up in the subacute period because of prolonged discomfort. In our study, fifteen patients with isolated triquetrum fractures admitted within six year period were presented with their clinical, radiological features and treatment outcomes.

## Keywords

Triquetrum Fracture, Direct Lateral Roentgenogram

---

## 1. Introduction

Triquetrum fractures are seen together with fractures of distal radius, forearm and commonly with other scaphoid fractures or they may rarely occur in isolation. Due to underdiagnosis or misdiagnosis, frequently real incidence of these fractures cannot be known exactly. Diagnosis of these fractures, most of them can be successfully

**How to cite this paper:** Ozdemir, G., Ucar, B.Y., Cerci, M.H., Yilmaz, B. and Basarir, K. (2015) Isolated Triquetrum Fractures: The Importance of Proper Roentgenograms in Ulnar Sided Wrist Pain. *Open Journal of Orthopedics*, 5, 186-188.

<http://dx.doi.org/10.4236/ojo.2015.57025>

treated with simple immobilization, is based on keeping in mind the possibility of triquetrum fractures and evaluation of appropriate radiographs. Assessment of the fracture as wrist sprain with inappropriate radiographs may cause prolongation of the patient's complaints. In our study, fifteen patients were presented with their clinical and radiological features to emphasize the importance of direct radiological investigation in appropriate position for diagnosis of isolated triquetrum fractures.

## 2. Patients and Methods

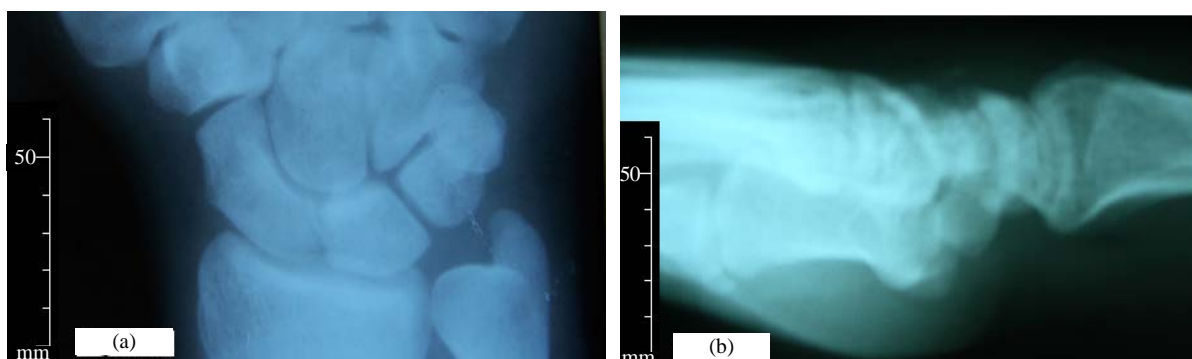
The patients presenting with complaint of acute wrist pain to the orthopedics and traumatology polyclinic and diagnosed with isolated triquetrum fracture between 2008 and 2014 were included in the study. Open fractures and multiple carpal bone fractures were excluded from the study.

Fifteen patients meeting these criteria were included in the study. Ten of the patients were males, mean age was 32.6 (21 - 56) years and 11 of the fractures were on the left side. Dorsal chip fractures comprised of 9 of the cases and triquetral body fractures comprised of 6 of the cases.

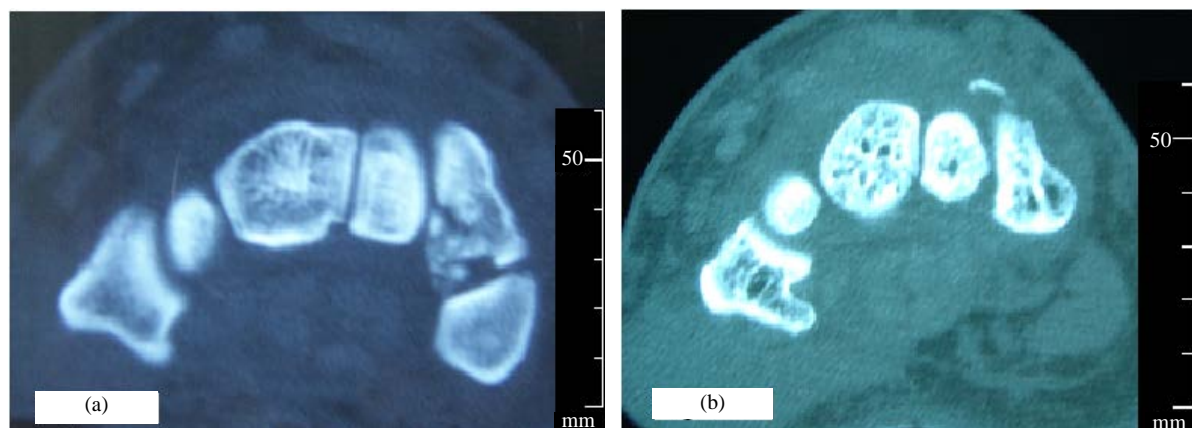
All of the cases presented to our hospital in the acute period (<1 week) and all of the cases were evaluated by using two-dimensional X-ray at the beginning (**Figure 1(a)**, **Figure 1(b)**). Two patients in whom fracture line could not be determined in X-ray clearly were evaluated by using computed tomography (**Figure 2(a)**, **Figure 2(b)**).

## 3. Results

All of the cases were treated with short-term immobilization. In all of the cases, full painless range of motion was reached during 3 months follow-up visits of them.



**Figure 1.** (a) The radiolucent line suggestive of fracture in the triquetral body on posterior-anterior direct wrist radiograph. (b) Triquetral dorsal chip fracture is seen on lateral full wrist radiographs.



**Figure 2.** (a) Non-displaced fracture line is seen on computerized axial tomography scans. (b) Triquetral dorsal chip fracture is seen on computerized axial tomography scans.

## 4. Discussion

Triquetral fractures are generally classified into two groups as body fractures and dorsal chip fractures [1] and there are different views regarding mechanism of injury of triquetral fractures. First, it was accepted that body fractures occurred with compression mechanism and dorsal chip fractures occurred with avulsion mechanism [2] [3], but afterwards it had been suggested that dorsal chip fracture of the triquetrum was caused by the effect of ulnar styloid [1] [4] or the hamate [5] on the dorsum of the os triquetrum upon a fall on the wrist in dorsiflexion. While it was suggested that ulnar styloid process index (USPI) was higher in these kind of cases [1] [4], measurements of ulnar styloid process index were performed and they were determined not to be higher in our cases.

Wrist injuries occurring after a fall on the wrist account for an important portion of daily clinical practice of orthopedics. Although triquetrum fractures causing ulnar-sided wrist pain are the second most common carpal fractures after scaphoid, they are less common seen in daily clinical practice [2] [4] [5]. Most of these fractures are seen after a fall on an outstretched hand and they clinically manifest with painful and edematous wrist and limitation in movement [2] [6]. While localization of the pain to the ulnar side of the wrist is guiding for diagnosis, it should be kept in mind that this condition cannot be observed as in two cases of our series and it will show similar physical examination findings of soft-tissue injuries.

Independently of the type of fracture, as it is in our series, correct diagnosis of triquetrum fractures that can be successfully treated with conservative treatment including immobilization for 4 - 6 weeks as a rule is also the mainstay for the treatment process [5] [7] [8]. Obtaining also oblique wrist radiographs in addition to anterior-posterior and lateral wrist radiographs is important, because dorsal chip fractures undetermined on lateral radiographs have been reported on oblique radiographs [6] [9]. In our series, eight dorsal chip fractures were observed only on lateral radiographs and one dorsal chip fracture was observed on both positions. Therefore, taking lateral and oblique wrist radiographs in appropriate position is very important for correct diagnosis of these fractures. Prolonged symptoms in the patients with acute wrist injury not determined fracture after direct radiological investigation are considered to be suggestive of injuries of ligamentous or cartilaginous structures rather than fracture. In this case, advanced radiological investigations such as CT and MRI are recommended. Failure to diagnose triquetrum fractures and failure to control the symptoms of the patients due to inadequate immobilization are of vital importance regarding obtaining unnecessary advanced investigations for diagnosis of soft-tissue injuries with prolonged symptoms resistant to symptomatic treatment.

We think that obtaining also appropriate lateral full and oblique wrist radiographs in addition to posterior-anterior wrist radiographs in evaluation of the wrist injuries especially with ulnar-sided pain will provide contribution to early diagnosis and treatment of triquetrum fractures.

## References

- [1] Levy, M., Fischel, R.E., Stern, G.M., *et al.* (1979) Chip Fractures of the Os Triquetrum: The Mechanism of Injury. *Journal of Bone and Joint Surgery*, **61**, 355-357.
- [2] Bonnin, J.G. and Greening, W.P. (1944) Fractures of the Triquetrum. *British Journal of Surgery*, **31**, 278-283. <http://dx.doi.org/10.1002/bjs.18003112314>
- [3] Thompson, J.E. (1933) Fractures of the Carpal Navicular and Triquetrum Bones. *The American Journal of Surgical Pathology*, **21**, 214-226. [http://dx.doi.org/10.1016/S0002-9610\(33\)90883-1](http://dx.doi.org/10.1016/S0002-9610(33)90883-1)
- [4] Garcia-Elias, M. (1987) Dorsal Fractures of the Triquetrum-Avulsion or Compression Fractures? *Journal of Hand Surgery*, **12A**, 266-268. [http://dx.doi.org/10.1016/S0363-5023\(87\)80285-X](http://dx.doi.org/10.1016/S0363-5023(87)80285-X)
- [5] Höcker, K. and Menschik, A. (1994) Chip Fractures of the Triquetrum: Mechanism, Classification and Results. *Journal of Hand Surgery*, **19B**, 584-588.
- [6] de Beer, J.V. and Hudson, D.A. (1987) Fractures of the Triquetrum. *Journal of Hand Surgery*, **12B**, 52-53.
- [7] Letts, M. and Esser, D. (1993) Fractures of the Triquetrum in Children. *Journal of Pediatric Orthopaedics*, **13**, 28-31.
- [8] Strohm, P.C., Laier, P., Gutorski, S. and Pfister, U. (2002) Isolierte Korpusquerfraktur de sos triquetrum. *Unfallchirurg*, **105**, 395-396. <http://dx.doi.org/10.1007/s001130100334>
- [9] Fairbank, T.J. (1942) Chip Fractures of the Os Triquetrum (Carpal Cuneiform). *British Medical Journal*, **2**, 310-311. <http://dx.doi.org/10.1136/bmj.2.4262.310>