

Retrospective Descriptive Analysis of the Combined First Trimester of Pregnancy Screening in the Period Included from February 2016 to March 2017, Maternal Fetal Medicine Unit, San Juan de Dios Hospital

Carina Breuning Velásquez, Oscar Durán Soto, Joaquin Bustillos Villavicencio*, Jorge Mora Sandí, Eugenio Calderon, Veronica Saborio, Leonardo Jimenez, Pablo Parra

Hospital San Juan de Dios, San José, Costa Rica

Email: *joaquin.bustillos@gmail.com

How to cite this paper: Velásquez, C.B., Soto, O.D., Villavicencio, J.B., Sandí, J.M., Calderon, E., Saborio, V., Jimenez, L. and Parra, P. (2018) Retrospective Descriptive Analysis of the Combined First Trimester of Pregnancy Screening in the Period Included from February 2016 to March 2017, Maternal Fetal Medicine Unit, San Juan de Dios Hospital. *Open Journal of Obstetrics and Gynecology*, 8, 891-899.

<https://doi.org/10.4236/ojog.2018.810092>

Received: March 15, 2018

Accepted: August 24, 2018

Published: August 27, 2018

Copyright © 2018 by authors and Scientific Research Publishing Inc. This work is licensed under the Creative Commons Attribution International License (CC BY 4.0).

<http://creativecommons.org/licenses/by/4.0/>



Open Access

Abstract

A retrospective descriptive study is conducted at the San Juan de Dios Hospital, San José, Costa Rica, during the period from February 2016 to March 2017, with a total of 37 patients from which a combined screening during the first trimester of pregnancy was conducted, evaluating maternal age, biochemical and sonographic methods that together can predict the risk of fetal chromosomal alterations during pregnancy. The purpose of using combined screening as a noninvasive method is to identify high risk gestations and to minimize the number of invasive procedures to detect the highest number of cases. Four patients with higher risk of aneuploidy during pregnancy were identified through this screening.

Keywords

Protocol, Combined Screening, First Trimester, Aneuploidy, Trisomy

1. Introduction

The following paper is based on the results obtained from the application of a first trimester of pregnancy screening tests that suggest fetal aneuploidy, focused in 21, 13, 18 trisomies, Down, Patau and Edwards syndrome respectively with the final goal of educating parents and foresee the causes of associated perinatal morbidity and mortality.

The first trimester of pregnancy echography and structural chromosomal mutation screening protocol is established at the unit of obstetrics of Hospital San Juan de Dios and the latter is applied during the period between February 2016 and March 2017. The objective of the screening pretends to reduce the number of invasive procedures during pregnancy that might carry a risk of miscarriage as well as to reduce the monetary costs that this measure generates [1].

Given that the screening based on maternal age represents a method with a low sensibility and specificity, the combined method that includes variables such as maternal age, biochemical tests and echography altogether has a superior accuracy, achieving index of detection for Trisomy 21 as high as 90% and a 5% of false positives [1] [2].

The exclusion criteria used to apply the screening method are:

- Younger than 15 years old and older than 35 years old.
- History of aneuploidy as well as congenital malformations or genetic syndrome.
- Pregestational diabetes.
- Epilepsy.
- History of 3 or more abortions.
- Pregnancies achieved through *in vitro* fertilization.
- Patients exposed to radiation during the first trimester of pregnancy.

All of these exclusion criteria are related to high risk of fetal chromosomal alteration, high risk of metabolic or genetic disease as well as a higher risk of perinatal infection.

The protocol contemplates two types of exploration: the ultrasound between the 11 - 13.6 weeks of gestation and biochemical analysis of the beta fraction of the chorionic gonadotropic hormone and a protein associated to pregnancy from maternal blood samples. Both results are expressed as multiples of the median (MoM) for each gestational age. In case of trisomy 21 the β -HCG values are elevated while PAPP-A is reduced. In case of trisomy 13 and 18 both values are reduced.

The most important echography markers of aneuploidy are the nuchal translucency and the nasal bone. An increase in nuchal translucency is due to liquid accumulation behind the fetal neck which is observed during ultrasonographic evaluation during the first trimester of pregnancy and is associated with trisomy 21. 75% of the fetuses with T21 are reported to have an increased nuchal translucency. The absence of the nasal bone not necessarily increases the index of detection of down syndrome, but it can be used as a marker to decrease false positives.

Some other markers used for the echographic scrutiny of the first trimester are the ductus venosus and tricuspid regurgitation, both have an increased incidence in trisomy 21 fetus compared to euploid fetus and in this manner they increase the detection of aneuploidy and reduce the index of false positives. They do not form part of the combined screening since when reported in absence of

other abnormalities, they don't indicate aneuploidy or perinatal pathology, there is need for highly trained personal to carry both explorations and so they are reserved for population of an intermediate to high risk.

In the protocol there is also the possibility to perform a biochemical evaluation during the second trimester of pregnancy in those cases that were not screened during the first trimester of pregnancy. Given such a case, ACOG (American College of Obstetrics and Gynecology) recommends a quadruple scrutiny to be performed. The latter includes: alfa fetal protein, β -HCG, estriol and inhibin A; as well as the evaluation with ultrasound between the week 18 and 20 of pregnancy. The ultrasonographic markers of the second trimester include: choroid plexus cyst, intracardiac echogenic foci, increased nuchal fold, echogenic bladder, one unique umbilical artery, ventriculomegaly, absense or hypoplasia of nasal bone, right aberrant subclavian artery, hydronephrosis, femoral and/or humeral shrinkage. All the above-mentioned markers have elevated incidence in fetuses with aneuploidy compared to normal ones [1] [2] [3] [4].

The software used for the screening makes a basic calculation where all three fundamental variables (age, nuchal translucency, biochemical analysis report) plus gestational age are integrated and expressed in terms of a fraction. The used cut point for positive screening for risk of aneuploidy is 1/270 at 35 years [1].

In case of a positive screening test, it is recommended to perform a fetal karyotype. The elected method is the biopsy of chorionic villi preferably between weeks 11 and 13.6. After week 15 of gestation the gold standard is amniocentesis.

Chorionic villi biopsy must be performed after the 10th week of gestation either by transabdominal route or by transcervical means depending on the experience and preferences of the physician or the location of the placenta. The complications related to this procedure include the risk of miscarriage (reported between 0.2% and 2% of cases) and vaginal bleeding reported in 10% of cases [1] [5] [6].

Factors associated with increased risk of miscarriage after chorionic villi biopsy reported in previous retrospective trials include: African Americans, at least two needle aspirations or insertions, abundant bleeding during procedure, maternal age less than 25 years or gestational age less than 10 weeks.

Low levels of PAPP-A are related with placentation-preeclampsia issues, reason why it is also related to higher miscarriage risk [6].

Amniocentesis must be done after the 15th week of gestation by transabdominal means and guided by ultrasound. The complications reported after this procedure include the risk of fetal loss that varies between 0.1% and 1%, increased risk of amniotic fluid loss up to week 24 of gestation. There has been a reduced risk of chorioamnionitis and uterine infection after an amniocentesis, the risk below 0.7%.

By themselves, the presence of an elevated nuchal translucency and fetal structural anomalies are associated with an increased risk of pregnancy loss. This risk increases after invasive procedures such as chorionic villi biopsy and amni-

ocentesis.

Another test performed in the United States is the analysis of fetal blood sample in search of chromosomal mosaicism, which is obtained by transabdominal means after the 18th week of gestation.

Eligibility criteria for the procedure are:

- High risk for chromosomal fetal alterations.
- High risk of metabolic or genetic diseases.
- High risk of perinatal infection.

Before any invasive procedure, detailed family counsel as well as awareness of associated risks should be done.

2. Methods

A retrospective descriptive trial was performed using data from San Juan de Dios Hospital's maternal fetal unit. 37 patients total were included in the period of time from February 2016 to March 2017. These patients all received the first trimester screening test during their pregnancy.

Data were drawn from the archive of screening results for Down Syndrome of the unit. Both maternal and fetal variables were analyzed. Patients did not sign an informed consent since the screening is already part of the services offered to the pregnant patient in our center. A thorough file search was performed and factors such as maternal age, number of fetuses, gestational age, ethnicity, history of trisomy 21, and the values of the screening tests were recorded. Afterwards a frequency and rate analysis was performed to obtain the main results. All of the data was recorded in Microsoft Office Excel, graphs were also performed using this software [1] [2] [5] [7] [8] [9] [10].

Using the exclusion criteria, patients followed at San Juan de Dios Hospital from February 2016 to March 2017 were included in our study. A recording data table was created and 41 patients were gathered. From this main group, 4 patients lost their control in our center so at the end 37 patients were finally included.

3. Objectives

Perform first trimester screening test to identify asymptomatic individuals at increased risk of having a pregnancy with chromosomal fetal alterations.

Diminish the amount of invasive procedures either by chorionic villi biopsy or amniocentesis that could result in fetal loss.

4. Results

During the period of February 2016 to March 2017 patients were screened with the combined first trimester screening test during their first trimester of pregnancy. From the 37 included patients three presented risk for trisomy 21 and two presented high risk in the combined test (see **Table 1**).

The group ages go from 26.6 to 44.8 years with an average of 36.18 years of

age (see **Figure 1** and **Figure 2**). 23 of the patients included for screening were Caucasian and 14 had no ethnicity recorded.

The screening was performed in patients with pregnancies with gestational ages between 10.4 weeks and 14.2 weeks in average the gestational age was of 12.4 weeks.

The values of the BHCG are located between 0.2 and 2.51 MOM with an average of 0.80 MoM.

The values of PAPP-A were found to be at ranges between 0.27- 3.54 MOM with an average of 1.02.

For the sonographic evaluation the nuchal translucency and the cranium rump length (CRL) were recorded and the cases where the nasal bone could be observed were reported (**Table 2** and **Table 3**).

The range of the CRL was 38 - 82.34 mm with an average of 62.30 mm. For the nuchal translucency a range between 0.4 and 3.9 with an average of 1.41 mm. The nasal bone was present in 5 of the 37 evaluated fetuses (**Figure 3**).

In **Figure 4** and **Figure 5** the results of the serum analysis from high risk patients are summarized.

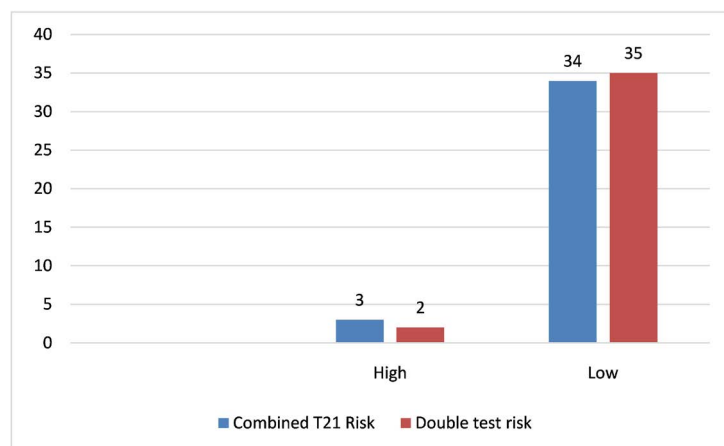


Figure 1. Screening risk.

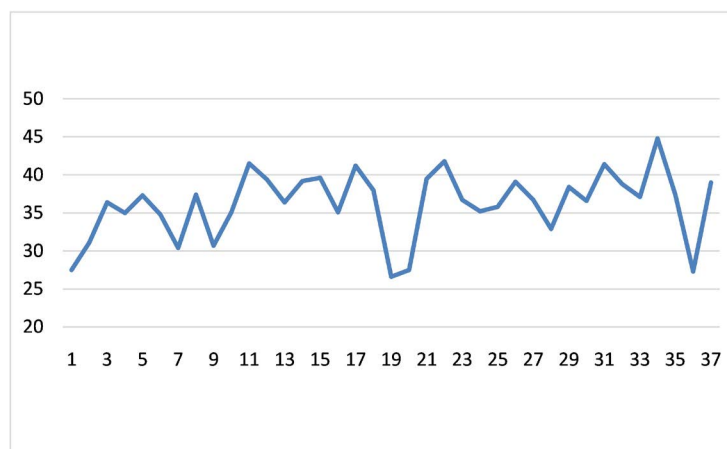


Figure 2. Maternal age.

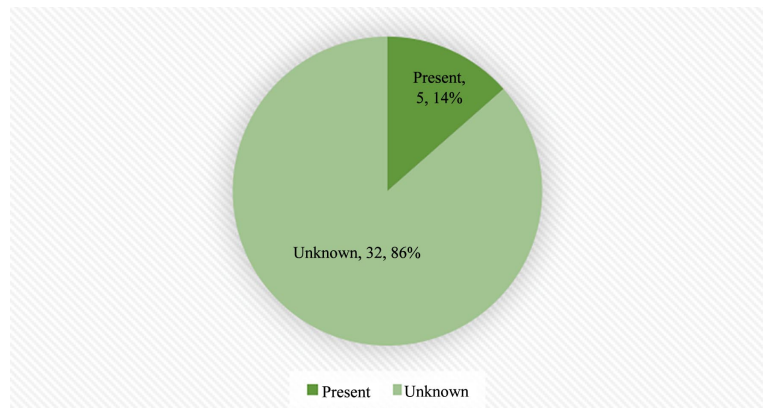


Figure 3. Nasal bone.

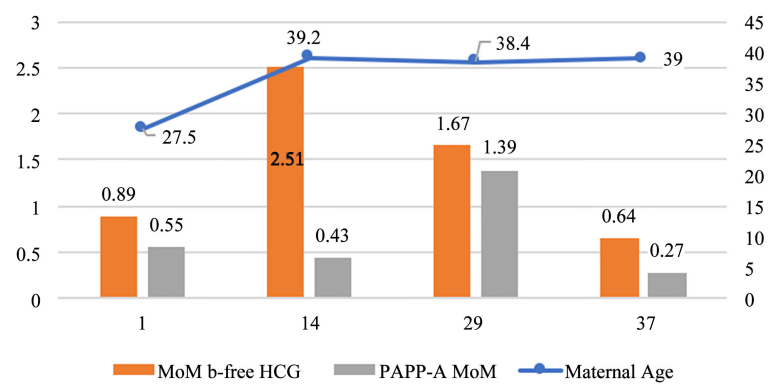


Figure 4. Parameters.

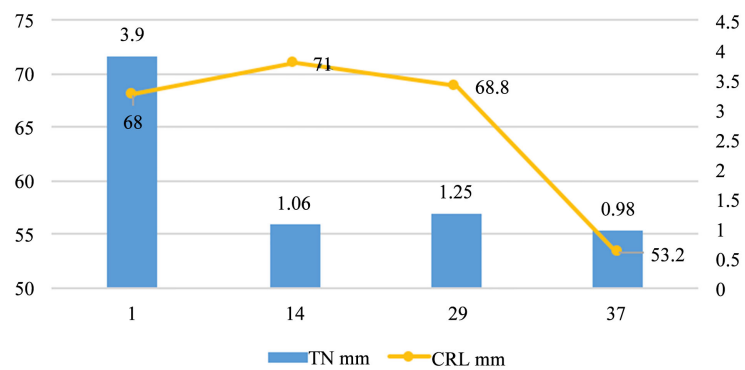


Figure 5. Echographical data.

Table 1. Individuals at risk in the analysis of the combined screening.

Subject	1	14	29	37
Maternal age	27.5	39.2	38.4	39
T21 combined risk	>1:50	1:62	1:118	1:318
Double test risk			>1:50	>1:50
Risk by age	1:837	1:101	1:123	1:99

Table 2. Analyzed data in the combined screening.

	Free β -HCG MoM	PAPP-A MoM	CRL mm	TN mm	.. MoM
Average	0.80	1.02	62.30	1.41	0.88
Minimum	0.2	0.27	38	0.4	0.32
Maximum	2.51	3.54	82.84	3.9	2.27
Range	0.2 - 2.51	0.27 - 3.54	38 - 82.84	0.4 - 3.9	0.32 - 2.27

Table 3. Laboratory analyzed data.

	Estriol	PAPP-A lab	HCG libre	Alpha fetal protein UI/ml	HCG mUI/ml
Average	0.13	5.61	28.78	15.89	87,714.7
Minimum	0.07	1.22	7	6.36	18,394
Maximum	0.6	10	90	33.3	78,248

5. Discussion

The analysis of the results from the combined screening in the first trimester of pregnancy done during one year at Hospital San Juan de Dios, reflects a total of four patients of high risk detected by this protocol. In individuals at risk the average age was of 36 years, which matches with the universal statistics that place increased maternal age as the principal risk correlated to fetal aneuploidy.

It is worth noting that nuchal translucency of one fetus was reported at 3.9, superior to the cut associated with trisomy 21. Nevertheless when following up those cases identified as high risk, after an appropriate counseling to the patients and their family, only one patient was reported and amniocentesis is still pending. Two of the remaining patients rejected the procedure and one of them never came back to prenatal control at the unit, reason why there is a bias of information in this case.

This study concluded 10% of affected cases and, as suggested by foreign sources, in our environment amniocentesis will be performed on the patient who accepted the procedure, corresponding respectively to 1.85% of the screened patients.

Since we practice in social care and our country has limited economical resources, the screening is made on selected patients with inclusion risk criteria that might implicate an increased risk for the gestation, reason why the sample is not significant.

Actually in other countries, a free cell on maternal blood DNA analysis is being performed. Fetal cell-free DNA are fragments of DNA found in maternal serum. Fetal cell-free DNA can be found in circulation as early as 4 weeks gestation. Levels of Fetal cell-free DNA have been shown to increase moderately during a normal pregnancy. Using Fetal cell-free DNA offers big potential as a screening tool due to its increased accuracy over maternal serum markers and

nuchal translucency tests. The accuracy of noninvasive prenatal screening with Fetal cell-free DNA reduces the number of invasive tests needed for a definitive diagnosis. In general obstetric population, Fetal cell-free DNA have lower false-positive rates and higher positive predictive values than standard screening [11].

This method has the ability to detect small elevations in the amount of one respective chromosome in maternal plasma in a pregnancy due to a trisomy. Studies have demonstrated that this method might detect up to 99% of the cases of trisomy 21, 97% of trisomy 18, 92% of the cases of trisomy 13. The false positive rate is of 0.1% for T21, 0.2% for T18 and 0.2% for T13 respectively. The findings in the screening of free cell DNA in maternal blood in the general population resemble those of previous studies in high-risk pregnancies.

It has been shown that this method is feasible for routine screening and allows a reliable diagnosis of aneuploidy, with false-positive rates significantly lower than those of combined screening [12] [13].

Although this screening method is not publicly available, it is ideal for all pregnant patients to have at least one first-trimester ultrasound that includes the measurement of the nuchal translucency, which is a marker not only of fetal chromosomal alterations but also of cardiac defects and other genetic syndromes.

6. Conclusions

The combined screening of the first trimester of pregnancy represents an adequate screening strategy in this population to fundamentally reduce invasive diagnostic procedures and their complications in the case of suspected aneuploidy in the fetus.

In our study, despite being a sample of high-risk pregnant women, 4 patients with a risk of chromosomopathies were detected, which equal 10% of the study population, concordant with published data and demonstrating that counseling for just as screening is essential for the final follow-up of these patients.

This confirms that ultrasound aimed at screening patients with some risk in the first trimester of pregnancy should be a fundamental and mandatory study as a measure even of initial uptake of the patient during a pregnancy and, when combined with other epidemiological variables and biophysical in this population, we stratify the individual risk early on in each patient and thus we can offer a higher quality care in this very determinant stage of being a human being.

Acknowledgements

To the radioimmune analysis laboratory and to the Obstetrics Department of Hospital San Juan de Dios for all the support and collaboration in this project.

Declaration of Conflict of Interest

Authors declare there is no conflict of interest.

References

- [1] Bustillos Villavicencio, J. (2014) Protocolo: Ecografía de primer trimestre y screening de alteraciones cromosómicas y estructurales en el primer trimestre del embarazo. Servicio de Obstetricia, Hospital San Juan de Dios.
- [2] Rao, R. and Platt, L.D. (2016) Ultrasound Screening: Status of Markers and Efficacy of Screening for Structural Abnormalities. *Seminars in Perinatology*. WB Saunders, 67-78. <https://doi.org/10.1053/j.semperi.2015.11.009>
- [3] Chi, T., Huggon, I., Zosmer, N. and Nicolaides, K.H. (2001) Incidence of Major Structural Cardiac Defects Associated with Increased Nuchal Translucency But Normal Karyotype. *Ultrasound in Obstetrics & Gynecology*, **18**, 610-614. <https://doi.org/10.1046/j.0960-7692.2001.00584.x>
- [4] Agathokleous, M., Chaveeva, P., Poon, L.C.Y., Kosinski, P. and Nicolaides, K.H. (2013) Meta-Analysis of Second-Trimester Markers for Trisomy 21. *Ultrasound in Obstetrics & Gynecology*, **41**, 247-261. <https://doi.org/10.1002/uog.12364>
- [5] Howard, C. (2000) Biochemical Screening for Down Syndrome. *European Journal of Obstetrics & Gynecology and Reproductive Biology*, **92**, 97-101. [https://doi.org/10.1016/S0301-2115\(00\)00431-0](https://doi.org/10.1016/S0301-2115(00)00431-0)
- [6] Ghi, T., *et al.* (2016) ISUOG Practice Guidelines: Invasive Procedures for Prenatal Diagnosis. *Ultrasound in Obstetrics & Gynecology*, **48**, 256-268. <https://doi.org/10.1002/uog.15945>
- [7] Nicolaides, K.H., Heath, V. and Cicero, S. (2002) Increased Nuchal Translucency at 11 - 14 Weeks. *Prenatal Diagnosis*, **22**, 308-315. <https://doi.org/10.1002/pd.308>
- [8] Nicolaides, K.H., Sebire, N. and Snijders, R. (1999) Nuchal Translucency and Chromosomal Defects. In: Nicolaides, K.H., Ed., *The 11 - 14 Week Scan. The Diagnosis of Fetal Abnormalities. Diploma in Fetal Medicine Series*, The Parthenon Publishing Group, London, 3-65.
- [9] Cicero, S., Curcio, P., Papageorghiou, A., Sonek, J. and Nicolaides, K.H. (2001) Absence of Nasal Bone in Fetuses with Trisomy 21 at 11-14 Weeks of Gestation: An Observational Study. *Lancet*, **358**, 1665-1667. [https://doi.org/10.1016/S0140-6736\(01\)06709-5](https://doi.org/10.1016/S0140-6736(01)06709-5)
- [10] Alfirevic, Z. and Brigham, S.K. (2003) Amniocentesis and Chorionic Villus Sampling for Prenatal Diagnosis. *Cochrane Database of Systematic Reviews*, **3**, CD003252. <https://doi.org/10.1002/14651858.CD003252>
- [11] Wagner, A., Mitchell, M. and Tomita-Mitchell, A. (2014) Use of Cell-Free Fetal DNA in Maternal Plasma for Noninvasive Prenatal Screening. *Clinics in Perinatology*, **41**, 957-966. <https://doi.org/10.1016/j.clp.2014.08.013>
- [12] Quezada, M.S., Gil, M.M., Francisco, C., Oròsz, G. and Nicolaides, K.H. (2015) Screening for Trisomies 21, 18 and 13 by Cell-Free DNA Analysis of Maternal Blood at 10 - 11 Weeks Gestation and the Combined Test at 11 - 13 Weeks. *Ultrasound in Obstetrics & Gynecology*, **45**, 36-41. <https://doi.org/10.1002/uog.14664>
- [13] Gil, M.M., Quezada, M.S., Revello, R., Akolekar, R. and Nicolaides, K.H. (2015) Analysis of Cell-Free DNA in Maternal Blood in Screening for Aneuploidies: Updated Meta-Analysis. *Ultrasound in Obstetrics & Gynecology*, **45**, 249-266. <https://doi.org/10.1002/uog.14791>