

# Management of an Unusual Complication of Uterine Fibroids in the Gynecological Department of the University and Hospital Center of Treichville (Cote D'ivoire): About 2 Cases of Non-Puerperal Uterine Inversion

Eric Bohoussou<sup>1</sup>, Lamine Dia<sup>1</sup>, Ignace Yao<sup>1</sup>, Kacou Anzoua<sup>2</sup>, Privat Guie<sup>1</sup>, Simplicie Anongba<sup>1</sup>

<sup>1</sup>Gynaecology and Obstetrics Department, Treichville University Hospital Center, Abidjan, Côte d'Ivoire

<sup>2</sup>General Surgery and Digestive Department, Bouaké University Hospital Center, Bouaké, Côte d'Ivoire

Email: [jmlamedia@yahoo.fr](mailto:jmlamedia@yahoo.fr)

**How to cite this paper:** Bohoussou, E., Dia, L., Yao, I., Anzoua, K., Guie, P. and Anongba, S. (2017) Management of an Unusual Complication of Uterine Fibroids in the Gynecological Department of the University and Hospital Center of Treichville (Cote D'ivoire): About 2 Cases of Non-Puerperal Uterine Inversion. *Open Journal of Obstetrics and Gynecology*, 7, 220-225.

<https://doi.org/10.4236/ojog.2017.72023>

**Received:** January 3, 2017

**Accepted:** February 18, 2017

**Published:** February 21, 2017

Copyright © 2017 by authors and Scientific Research Publishing Inc. This work is licensed under the Creative Commons Attribution International License (CC BY 4.0).

<http://creativecommons.org/licenses/by/4.0/>



Open Access

---

## Abstract

Uterine inversion is rare. It is classically described as a complication of the delivery period. Non-puerperal uterine inversion is exceptional and usually results from a tumor implanted on fundus of the uterus. We report two cases of non-puerperal uterine inversion caused by fundal submucosal myoma. Its diagnosis can be difficult and a high index of clinical suspicion is required to make a prompt diagnosis. The delayed diagnosis observed in our cases, caused uterine necrosis, which was managed by hysterectomy. The patients' post-operative course was uneventful.

## Keywords

Non-Puerperal Uterine Inversion, Myoma, Hysterectomy

---

## 1. Introduction

Uterine inversion, a rare complication is defined as the invagination of fundus of the uterus like an overturned finger glove. During their professional practice, few gynecologists have faced it [1]. Several degrees are described according to the localization of the uterine fundus [1] [2]:

- 1<sup>st</sup> degree: the uterine fundus is still in the cavity and has not passed the cervix;
- 2<sup>nd</sup> degree: the fundus has passed the external orifice of the cervix;
- 3<sup>rd</sup> degree: the uterine fundus is externalized at the vulva;

- 4<sup>th</sup> degree: when the vaginal walls participate in the inversion.

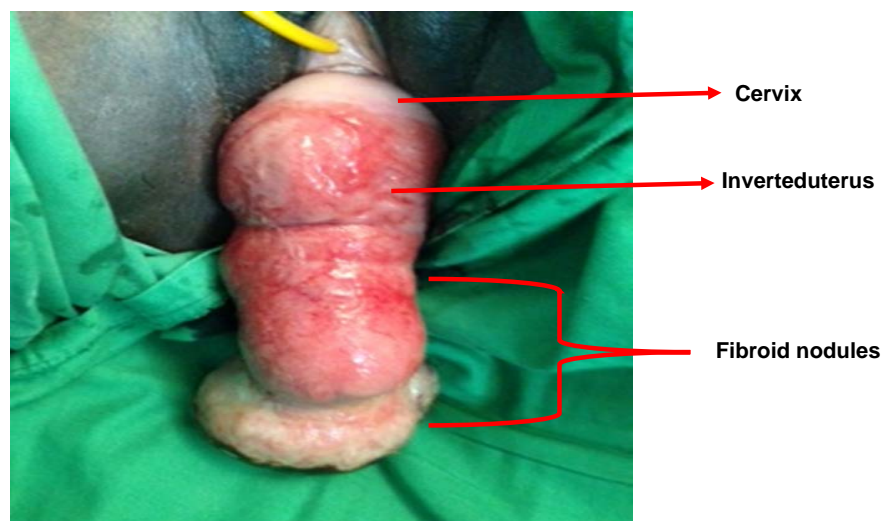
This accident usually occurs during puerperal period and non-puerperal cases are exceptional [1] [2]. The non-puerperal uterine inversion (NPUI) is generally caused by an endocavity tumor which will provoke a traction force and cause the inversion [2]. Its prognosis is linked to the precocity of the diagnosis and a rapid treatment which helps avoid hysterectomy and even the death [4]. However, the extreme rarity of the disease can make diagnosis difficult [1] [3].

From two observations of NPUI, we report our experience of management of this complication in an undermedicalized country, insisting on the diagnostic difficulties and hysterectomy treatment.

## 2. Clinical Cases

### 2.1. Case 1

Mrs D K, a 34 years jobless woman, having 3 children born by cesarean section, consulted at the gynecological emergency unit in our service for a large mass externalized to the vulva. The history revealed intermittent metrorrhagia for several months associated with vaginal discomfort and progressive worsening difficulties of urine voiding. Two months earlier, she had consulted for a large intravaginal mass for which the diagnosis of polyp delivered by the cervix was made. She then refused a surgical procedure. On admission, the patient had paleconjunctivae, blood pressure was 120/70 mm Hg and the temperature at 37°C. The gynecological examination revealed a pink, large, externalized vulvar mass, measuring 20 cm in the long axis with a lower big end (**Figure 1**). The suprapubic palpation showed the absence of uterus in the hypogastric region. The diagnosis of 3rd degree uterine inversion was clinically made. Hemogram showed a haemoglobin rate of 4 g/dl. The patient was transfused and then operated. An abdominal hysterectomy was performed. This was done after excision of uterine myoma vaginally, then reduction of the inversion by a posterior median

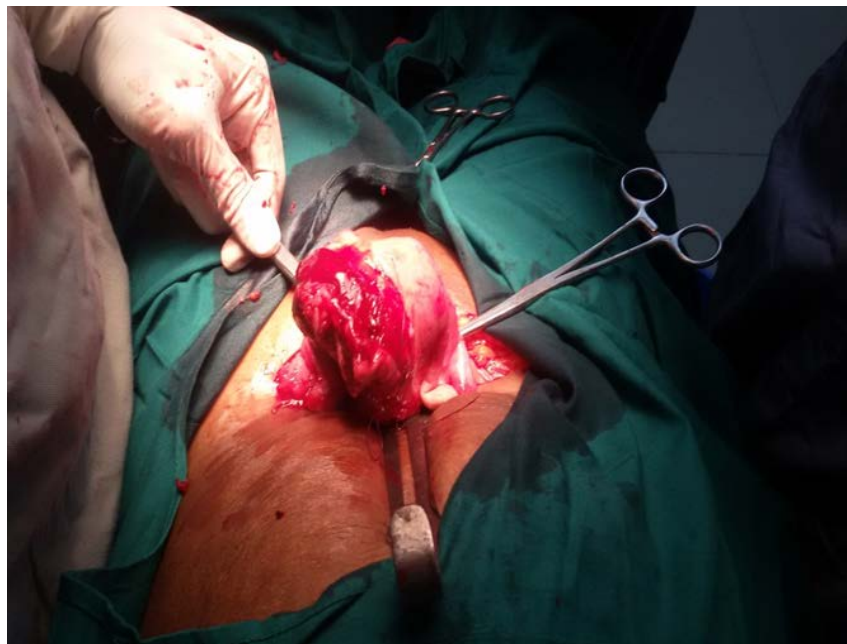


**Figure 1.** Complete inversion of the uterus and the fibroid nodule through the cervix (Observation 1).

colpo-hysterotomy according to the Haultain method. **Figure 2** shows an abdominal view of the uterine before hysterectomy. The following days were uneventful and she was allowed to go home on the fifth postoperative day. The pathological examination of the surgical specimen revealed an infarcted uterus with myomas.

## 2.2. Case 2

Mrs. SYC, 41 years, gravidity 3, parity 1, jobless and primary school education level, consulted at the gynaecological emergency unit in our service for abundant metrorrhagia associated with severe abdominal pain and vaginal discomfort. On examination, the patient was in shock and actively bleeding. The gynecological examination revealed an ulcerated, necrotic and haemorrhagic firm large mass, which filled the entire vaginal cavity. The cervical orifice was not identified. The diagnosis of polyp delivered by the cervix was made. Hemogram revealed a hemoglobin rate of 3.6 g/dl. During the reanimation, following a violent effort of vomiting, the patient presented at the vulva, an externalization of a red and regular soft vulvar mass prolonged at its lower extremity by another mass of about 10 cm in diameter; ulcerated, necrotic with firm consistence and fetid (**Figure 3**). The diagnosis of 3rd degree NPUI was therefore retained. The exposed endometrium was necrotic and infected. A total vaginal hysterectomy was performed. The operating procedure was performed by abdominal surgery in two steps: subtotal hysterectomy away from the bladder and totalization of the hysterectomy after reintroduction of the cervix into the pelvic cavity and bladder dissection. The pathological examination of the surgical specimen confirmed the diagnosis of uterine fibroid. The following days were uneventful and she was allowed to go home on the fifth postoperative day.



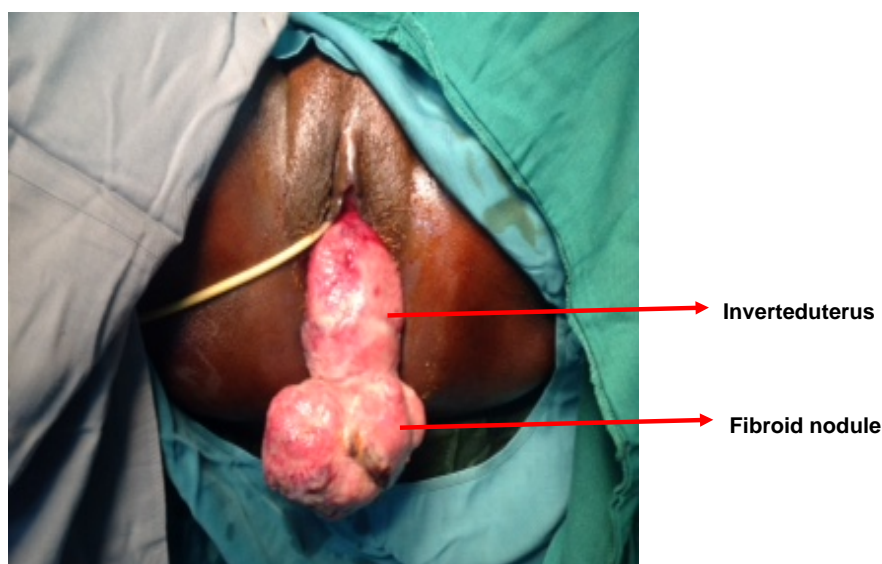
**Figure 2.** Abdominal view after correcting inversion.

### 3. Discussion

The NPUI is a rare complication and literature relates only few clinical cases [1] [2] [3] [4] [5]. In a literature review published in 2005, Lupovitch *et al.* had recorded only 150 cases since 1887 [5], which actually confirm this rarity. At the pathogenic level, the occurrence of this complication requires the presence of a large endo-uterine fundus tumor, which exerts a force of traction [2] [6]. The main etiology found is the submucosal myoma [1] [2] [3]. More rarely, it may be a sarcoma or carcinoma [4].

The epidemiologic and clinical characteristics of our patients (Table 1) share several common points with such described cases in the African literature as the young age of the patients, difficult and even wrong diagnosis, and little resort to medical imaging [1] [3] [7].

The diagnosis of NPUI is primarily clinical but often difficult because we do not think about it at a first glance [1]. These diagnostic difficulties are mainly met in the 1<sup>st</sup> and 2<sup>nd</sup> degree types [3]. A polyp delivered by the cervix can have the same clinical aspect (as the NPUI) and is the most cited diagnostic trap [3] [6]. Indeed in our observations, the intra-vaginal masses initially mistaken for polyps delivered by the cervix were uterine inversion of 2<sup>nd</sup> degree that had been misdiagnosed. The diagnosis of uterine inversion is based on the pathognomonic sign:



**Figure 3.** Complete inversion of the uterus and the fibroid nodule (Observation 2).

**Table 1.** Epidemiological and clinical characteristics of our 2 patients.

Observation	Age (years)	Profession	Education level	Parity	Signs	Degree
1	34	- Jobless	- Illetrate	3	- Metrorrhagia - Vaginal disturbance	3
2	41	- Jobless	- Primary school	3	- Metrorrhagia - Pelvic pain - Vaginal disturbance	3

the non-perception of the cervical orifice. As we examined the first patient, we did not have knowledge of that sign which delayed the diagnosis. In the second case, although we had knowledge of this sign, we could not highlight it. Two reasons can explain this failure: the volume of the intra-vaginal mass and its haemorrhagic character masked the inversion. In case of doubt, pelvic ultrasound, magnetic resonance imaging or laparoscopy may be useful [6] [8].

But the cost of such investigations and their non-availability in emergency situations limit their use in our context of work. On the other hand, in the externalized forms, the diagnosis seems easier by the visualization on at the vulva of the inverted uterus associated with submucosal fibroids. The absence of uterine fundus during abdominal palpation can confirm the diagnosis, and it is possible to perceive tubal ostia [3]. This sign was found in our patients probably because of the uterine gangrene. The NPUI is characterized in the 3<sup>rd</sup> degree by the constitution of a cervical neck ring that consequently exposes to uterus reintegration difficulties, infection and uterine gangrene [4] [8]. Hysterectomy is therefore the only option. It can be performed vaginally or by abdominal surgery depending on the operator's habits or surgical conditions [4] [6]. In the second case, we resorted to vaginal surgery. This has the advantage to limit the inoculation of the abdominal cavity with germs from the vaginal cavity. However, it exposes to a risk of ureter-bladder injuries due to the modifications of current anatomical landmarks [6]. To avoid this risk, we used the same technical artifice like Pelissier [6]. In the first case, we opted for the abdominal surgery, because of probable pelvic adhesions in connection with previous cesarean sections. The association of laparoscopy with vaginal surgery as described by Auber would certainly have been a good indication in this case [9].

As for maternal prognosis linked to hysterectomy, several series do not reveal any death [1]-[9]. However this intervention can be responsible for a non neglectful morbidity in connection with infectious and hemorrhagic complications [4]. Moreover the psychological consequences of these hysterectomies, which lead to definitive sterility, are important in these young women in full genital activity.

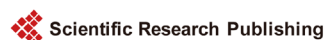#### 4. Conclusion

The NPUI is so exceptional that its extreme rarity can make the diagnosis difficult, if it is not an obvious external form. The gynaecologist must always have in mind the possibility of this complication in any polyp delivered by the cervix and search the cervical orifice through a painstaking examination. The prognosis depends on early diagnosis and rapid management in order to avoid hysterectomy.

#### References

- [1] Fofie, C.O. and Bafoe, P. (2010) Non-Puerperal Uterine Inversion: A Case Report. *Ghana Medical Journal*, **44**, 79-81.
- [2] De Vries, M. and Dam, P. (2010) Non-Puerperal Uterine Inversion due to Submu-

- cous myoma in a Young Woman: A Case Report. *Journal of Medical Case Reports*, **4**, 21. <https://doi.org/10.1186/1752-1947-4-21>
- [3] Umeononihu, O.S., Adinma, J.L., Obiechina, N.J., *et al.* (2013) Uterine Leiomyoma Associated Non-Puerperal Uterine Inversion Misdiagnosed as Advanced Cervical Cancer: A Case Report. *International Journal of Surgery Case Reports*, **4**, 1000-1003. <https://doi.org/10.1016/j.ijscr.2013.08.011>
- [4] Jellab, B., Aboufalah, A. and Abbassi, H. (2008) Hysterectomies for Puerperal Uterine Inversion: A Report of Two Cases. *La Lettre du Gynécologue*, **332**, 8-10.
- [5] Lupovitch, A., England, E.R. and Chen, R. (2005) Non-Puerperal Uterine Inversion in Association with Uterine Sarcoma: Case Report in a 26-Year-Old and Review of the Literature. *Gynecologic Oncology*, **97**, 938-941. <https://doi.org/10.1016/j.ygyno.2005.02.024>
- [6] Pelissier-Komorek, A., Lucereau-Barbier, M., Diab, J., Gavillon, N. and Graesslin, O. (2013) Inversion utérine non puerpérale aiguë du 3e degré. *Gynécologie Obstétrique & Fertilité*, **41**, 130-132. <https://doi.org/10.1016/j.gyobfe.2012.12.006>
- [7] Kouamé, A., Koffi, S.V., Adjoby, R., *et al.* (2015) Non-Puerperal Uterine Inversion in a Young Woman: A Case Report. *Journal of the West African College of Surgeons*, **5**, 78-83.
- [8] El-Agwany, A.S. and El-Badawy, E.S. (2015) Non-Puerperal Total Uterine Inversion with Cervical and Vaginal Inversion: An Unusual Complication of Degenerated Submucous Fundal Fibroid Treated by Vaginal Hysterectomy. *The Egyptian Journal of Radiology and Nuclear Medicine*, **46**, 1323-1326. <https://doi.org/10.1016/j.ejrm.2015.07.012>
- [9] Auber, M., Darwish, B., Lefebure, A., Ness, J. and Roman, H. (2011) Management of Non-Puerperal Uterine Inversion Using a Combined Laparoscopic and Vaginal Approach. *American Journal of Obstetrics and Gynecology*, **204**, 7-9. <https://doi.org/10.1016/j.ajog.2011.01.024>



Scientific Research Publishing

**Submit or recommend next manuscript to SCIRP and we will provide best service for you:**

Accepting pre-submission inquiries through Email, Facebook, LinkedIn, Twitter, etc.

A wide selection of journals (inclusive of 9 subjects, more than 200 journals)

Providing 24-hour high-quality service

User-friendly online submission system

Fair and swift peer-review system

Efficient typesetting and proofreading procedure

Display of the result of downloads and visits, as well as the number of cited articles

Maximum dissemination of your research work

Submit your manuscript at: <http://papersubmission.scirp.org/>

Or contact [ojog@scirp.org](mailto:ojog@scirp.org)