

HIV-Viral Hepatitis C Coinfection or Cross-Reaction of Rapid Diagnostic Orientation Tests? About a Clinical Case Observed in Brazzaville in 2016

Firmin Bossali^{1*}, G. Ndziessi², D. Gassaye³, C. Ahoui Apendi³, M. J. F. Mimiesse³, J. C. Moussoki⁴, B. I. Atipo-Ibara³, J. R. Ibara³

¹Department of Gastro-Enterology, General Hospital of Loandjili, Pointe-Noire, Congo

²Faculty of Health Sciences, Department of Public Health, Brazzaville, Congo

³Department of Gastro-Enterology, University Hospital of Brazzaville, Brazzaville, Congo

⁴WHO Library, Brazzaville, Congo

Email: *Firminbossali@yahoo.fr

How to cite this paper: Bossali, F., Ndziessi, G., Gassaye, D., Ahoui Apendi, C., Mimiesse, M.J.F., Moussoki, J.C., Atipo-Ibara, B.I. and Ibara, J.R. (2018) HIV-Viral Hepatitis C Coinfection or Cross-Reaction of Rapid Diagnostic Orientation Tests? About a Clinical Case Observed in Brazzaville in 2016. *Open Journal of Gastroenterology*, 8, 159-166.

<https://doi.org/10.4236/ojgas.2018.85018>

Received: April 6, 2018

Accepted: May 13, 2018

Published: May 16, 2018

Copyright © 2018 by authors and Scientific Research Publishing Inc.

This work is licensed under the Creative Commons Attribution International License (CC BY 4.0).

<http://creativecommons.org/licenses/by/4.0/>



Open Access

Abstract

Coinfection with human immunodeficiency virus (HIV) and viral hepatitis is associated with high morbidity and mortality in the absence of clinical management, making identification of these cases crucial. Screening for hepatitis viral-HIV coinfection before initiation of treatment for viral hepatitis or HIV is recommended. In this context, we report a case of possible cross-reaction between the serology of viral hepatitis C and HIV infection by rapid diagnostic orientation tests. Although these rapid tests are the main diagnostic tools in developing countries, their scientific validation must be required before they are made available to practitioners. The knowledge and the rigorous application of diagnostic algorithms of viral infections will make it possible to save money and to better organize the prevention and management strategies for patients as part of an integrated Hepatitis/HIV program.

Keywords

HIV, HVC, Rapid Diagnostic Orientation Test-Brazzaville

1. Introduction

The prevalence of coinfection with hepatitis C virus (HCV) in patients infected with the human immunodeficiency virus (HIV) is estimated in France at 24.3% in 2004 [1] [2] and 0.7% in Congo-Brazzaville [3]. In the context of antiretroviral

therapy (ART), HIV-hepatitis C or HIV-hepatitis B has emerged as a major cause of morbidity and mortality in HIV-infected persons in the absence of clinical management, making identification of these cases crucial. A study has shown that the impact of antiretroviral therapy (ART) on survival has unmasked chronic liver disease from viral hepatitis B or hepatitis C as a leading cause of morbidity and mortality in individuals with HIV infection [4]. Thus, for a best clinical management of patients, it is recommended to systematically screening for all these viruses before starting an anti-HIV, antiviral B or anti-viral C treatment. For HIV screening, rapid diagnostic tests are recommended. In the era of ART scaling-up in Africa, significant proportions of false positive but also false negative results are still observed with HIV screening tests commonly used in Africa, resulting in inadequate treatment and prevention strategies [5]. In addition, low specificities of HIV diagnostic tests are currently reported in situation of comorbidities. For example, in study conducted in RDC, Lejon *et al.* reported low specificities of HIV Diagnostic Tests Caused by *Trypanosoma brucei gambiense* Sleeping Sickness [6]. For this study, we report a clinical observation which poses the problem of a possible cross-reaction between the serology of viral hepatitis C and the human immunodeficiency virus infection by rapid diagnostic orientation tests. Our patient had given his written consent for the case report to be published.

2. Case Report

November 26, 2012, Mr. KA. J. aged 61, fisherman, living in a village located at the bank of Congo River, consults a sexologist for erectile dysfunction due to a bilateral hydrocele.

✓ Patient antecedents:

Mr. KA.J is married, polygamous and father of 8 children. He has suffered several times from urogenital infections that have left sequelae of epididymitis and hydrocele objectified with testicular ultrasound. He is not a smoker; he occasionally consumed alcohol at a rate of 50 to 100 g per circumstance. He has no previous surgical history; he had suffered a mild head injury without loss of consciousness several years ago. He had an untreated gingival hypertrophy in the upper central region and complained of chronic headaches for which the neurological, ophthalmological and otorhinolaryngological examinations were normal.

After a preoperative assessment deemed satisfactory by the anesthesiologist, Mr. KA. J. underwent a cure of hydrocele on 02/02/2016 by a urologist with uncomplicated postoperative follow-ups.

✓ History of the disease:

On 04/05/2016, three months after the cure of hydrocele treatment, Mr KA.J. consults for a progressive weight loss and polyarthralgia without fever.

• Physical examination:

The general state was preserved; however we noted a weight loss of 5 kg; the

body mass index was 26 kg/m²; Performance Status of the WHO was 2 and KARNOWSKY index was 80%. On abdomen examination no hepatomegaly or splenomegaly was evident; there were no signs of portal hypertension or hepatocellular insufficiency. The neurological, cardiopulmonary physical examination was normal. The blood pressure was measured at 130 mmHg for systole and for 90 mmHg diastole. Pulse rate was 84 beats per minute. The skin and mucous membranes were well stained and no adenopathy was found.

- **Morphological findings:**

Chest X-ray was normal; the electrocardiogram was normal; upper digestive fibroscopy was normal; colonoscopy was not performed.

Abdominal ultrasound showed homogeneous hepatomegaly with a liver span measured at 140 mm (**Figure 1**) and splenomegaly (**Figure 2**), but signs of portal hypertension or cirrhosis were not detected.

- **Biological findings:**

The complete blood count (CBC) was normal with a hemoglobin 13.4 g/dl; erythrocyte sedimentation rate (ESR) was 8 mm at the 1st hour and 16 mm at the 2nd hour. Glucosemia was normal at 0.70 g/l; serum creatinemia was normal at 12 mg/l; uricemia was normal at 51 mg/l; the blood ionogram was normal with sodium at 140 Meq/l; potassium at 3.8 Meq/l and chlorine at 99 Meq/l. C-reactive protein (CRP) value was inferior to 6 mg/l. Calcemia was normal at 88 mg/l; cholesterolemia was normal at 2 g/l; total bilirubinemia was normal at 3 mg/l; Lipasemia was normal at 31 mg/l. Blood levels of transaminases were normal: aspartate aminotransferases (ASAT) at 32 IU and alanine transpeptidase (ALT) at 29 IU. Prothrombin ratio was 71%. Tumor markers including carcinoembryonic antigen (CEA), alpha-fetoprotein (AFP), Carboxyhydrate 19.9 (CA.19.9) and prostate specific antigen (PSA) were negative. Syphilis serology test was negative; Cytobacteriological examination of the urine revealed a

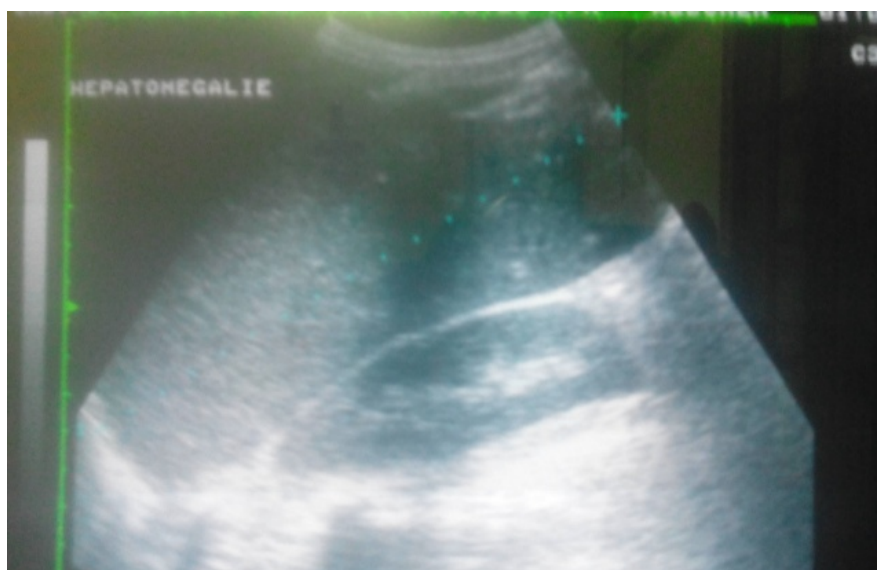


Figure 1. Ultrasound showing Hepatomegaly in our HCV+ patient.

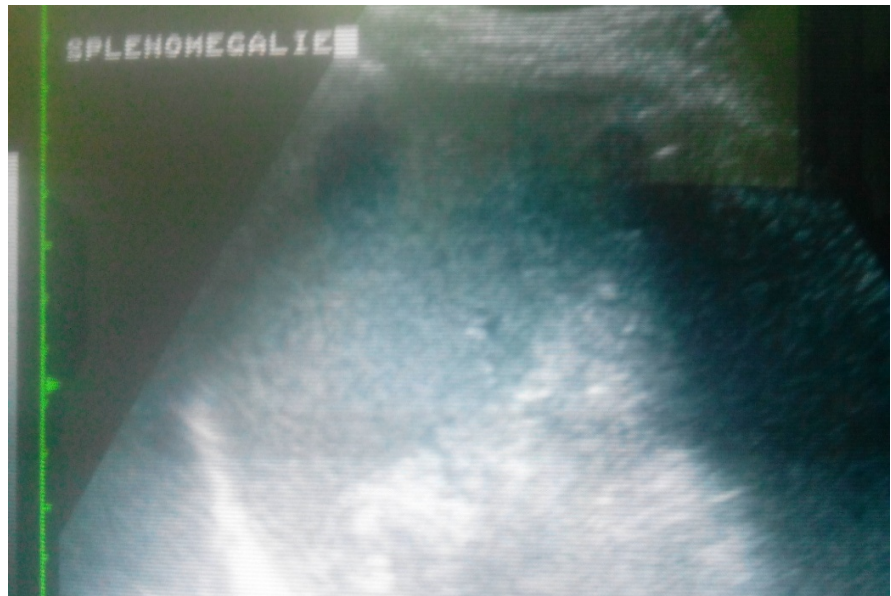


Figure 2. Ultrasound showing splenomegaly in our HCV+ patient.

urinary infection with Gram-negative bacillus. Blood tests for hepatitis B surface antigen (HBsAg) and total anti-HBc antibodies were negative.

Serology of HIV infection 1 and 2 was positive with all three tests used namely Abbott Determine, Immunocomb Bispot and Quick Check™. Blood CD4 lymphocytes count was 896 cells/mm³. However, the confirmation of HIV infection by qualitative and quantitative serologies by miniHIV 1/2 BIOMERIEUX laboratories as well as the search for viral RNA of HIV 1 and 2 performed by Real-Time Polymerase Chain Reaction (PCR) by electrochemiluminescence immunoassay (ECLIA) using Roche COBAS 8000 system was negative.

In addition, serology of viral hepatitis C performed in Brazzaville by the Immunocomb and Quick Step Ac HCV technique was positive. Confirmation of hepatitis C virus infection was obtained by Real-Time Polymerase Chain Reaction (PCR) by electrochemiluminescence immunoassay (ECLIA) using Roche COBAS 8000 system which detected viral RNA C evaluated at 20343 IU (4.31 log). The identified virus was type 4, the subtype was not specified. The Fibrotest-Actitest assessment of fibrosis found early fibrosis at the F2-A0 stage.

- **In summary:**

Mr KA.J. 61-year-old fisherman, polygamous, father of 8 children, reporting alcohol consumption about 100 g per circumstance, recently operated for bilateral hydrocele, had three months postoperative weight loss and polyarthralgias that led to the diagnosis of Chronic viral hepatitis C of genotype 4 in F2-A0 fibrosis.

He had a positive HIV serology by rapid diagnostic tests, but unconfirmed by real-time PCR with a CD4 cell count at 896 cells/mm³.

- **Therapeutic Aspects:**

Mr KA.J. received antibiotic treatment with ciprofloxacin 1g/day during 10 days as urinary tract infection therapy

In addition, he received a viral hepatitis C treatment by the combination of SOFOSBUVIR 400 mg/day with DAKLASTAVIR 60 mg/day for 12 weeks, *i.e.* 3 months from 03/12/2016 to 03/03/2017.

Then, pending the verification of the eradication of virus C, thus fearful of HIV coinfection to be re-verified, we put the patient on cotrimoxazole 860 mg/day for the prevention of opportunistic infections of HIV. The control of viral C replication at 3 months and at 6 months after stopping treatment confirmed the healing of viral C infection.

A last search for HIV RNA 1 and 2 by real-time PCR was always negative, which led us to stop administering Cotrimoxazole to the patient although the search for IgG viral hepatitis C antibodies by the Immunocomb and Quick Step Ac HVC remained positive and that of anti-HIV antibodies by the Abbot Determine technique remained positive.

At the end of the treatment and the check-up, the patient was declared hepatitis C cured and not HIV infected. He has returned to his village and is fine.

✓ **Discussion:**

Question: Is there any interference between immunoglobulin G anti-hepatitis C (HCV IgG) and immunoglobulin G anti-HIV (anti-HIV IgG)?

In infectiology, the purpose of serologies is to identify the infectious agent by detection of antibodies directed against the causative agent in the infected patient. Immunoglobulin M (IgM) antibodies allow early diagnosis of infection but lack specificity due to cross-reactions with other infectious agents and certain autoimmune diseases. Serologic evidence of infection is seroconversion by the presence of immunoglobulin G (IgG) specific antibodies against a tested antigen [7].

The diagnosis of HIV or HCV infection can be made by several techniques. To date there are rapid diagnostic orientation tests -and confirmatory tests [6] [7] [8] [9] [10].

TRODs are serological tests performed on whole blood, serum (plasma) or gingival fluid according to the manufacturer's instructions.

For the diagnosis of HIV infection, there are three (3) validated screening HIV tests ranging in sensitivity from 99.30% to 100% and specificity from 99.10% to 99.90%. To date, 20 validated types of Enzyme Linked Immunoassay (ELISA) confirmatory tests with a sensitivity of 100% and specificity ranging from 99.20% to 99.96% [10] [11]. HIV Ribonucleic Acid (RNA) research is performed using Real-Time Polymerase Chain Reaction (PCR) by electrochemiluminescence immunoassay (ECLIA) using Roche COBAS 8000 system with 100% Sensitivity and Specificity [12] [13].

For the diagnosis of hepatitis C virus infection, there are currently three validated rapid diagnostic orientation tests with sensitivity from 95.90% to 99.10% and specificity from 98.30% to 100% [14] [15] [16]. Confirmation of infection is provided by the 4th generation ELISA technique—and determination—of viral RNA and the genotype are obtained with the real-time PCR technique by elec-

trochemiluminescence immunoassay (ECLIA) using Roche COBAS 8000 system with 100% of specificity [17].

In Congo-Brazzaville in 2016:

✓ **For the diagnosis of HIV infection:** we had two quick tests:

Abbott DetermineR, Immunocomb Bispot and Quick Check™. The only 4th generation ELISA confirmatory technique available was mini VIDAS VIKIA HIV ½ from BIOMERIEUX laboratories. The search for HIV 1 and 2 viral RNA by real-time PCR techniques electrochemiluminescence immunoassay (ECLIA) using Roche COBAS 8000 system for our patients was not available, prompting us to send blood samples to the CERBA laboratory in Paris. Moreover we could not perform the confirmation test by Western Blot for three reasons: 1. non-availability in Congo-Brazzaville; 2. high cost; 3. The Western Blot only detects the anti-HIV 1 and 2 antibodies, it does not detect the viral particles (HIV antigen) whereas the test by the mini VIDAS VIKIA HIV 1/2 assay detects both HIV 1 and 2, the IgM antibodies, IgG antibodies P24 antigen and HIV antigen (viral particles). For these reasons, it was financially inaccessible for our patient to pay for Western Blot at the CERBA laboratory in Paris. Indeed with a high CD4 rate, a negative miniVIDAS test and a negative two-control viral load, we definitively concluded that MR KA.J. was HIV-negative

✓ **For the diagnosis of HCV infection:** we had the following rapid tests:

Immunocomb and Quick Step Ac HVC. The confirmation of infection by RT-PCR by electrochemiluminescence immunoassay (ECLIA) using Roche COBAS 8000 system, determination of genotype, hepatitis C virus subtype, and evaluation of fibrosis by Fibrotest-Actitest or fibroscan was not available; so we sent blood samples from our patients for analysis to the CERBA laboratory in Paris.

Our patient was tested positive for HVC by both rapid tests; Abbott Determine R, Immunocomb Bispot and Quick Check™ with a sensitivity and specificity of 100% and 99.40%, respectively. The matrix used was capillary whole blood on the finger whose chances of obtaining an exact result are less compared to the plasma [9]. Our patient is carrying a replicative viral C infection; did the presence of IgG anti-HCV antibodies positively cross-react with the two rapid tests for HIV? Tests are a non-automated diagnostic technique designed to give a fast result in 30 minutes maximum. Tests used for nearly 20 years worldwide are used for emergency tests in developing countries nowadays. However, in developing countries such as Congo-Brazzaville, screening tests are still useful tools for diagnosis of HIV infection and viral hepatitis B and C, because of their low cost and the simplicity of the technique. But it is important to remember that these tests are only for diagnosis orientation and not for the biological diagnosis, obliging any practitioner to seek confirmation before treatment initiation [8] [9].

Our patient false positive with HIV screening tests suggest low specificity these tests caused by viral hepatitis C. although we have not found previous studies of false HIV positive patient among VHC patients, the low specificity of HIV screening test reported with trypanosomiasis is a major argument support-

ing our results.. In the medical literature, it is -argued that a false positive for a serological test depends on the antibodies of HIV carrier-patient, but also on the characteristics of each test. For example, multi-pregnant women, multi-transfused and multi-transplanted patients develop HLA antibodies that react with ELISA or Western Blot test and give a false positive serology result.

Our patient being African and having many antecedents of infections including urogenital was certainly carrier of various immunoglobulins that could potentially react with the rapid tests. Moreover, among factors that can lead to a false positive result for HIV, we found in our patient chronic viral hepatitis C with F2 fibrosis, the presence of IgG antibodies could also have previously been in contact with leprosy, tuberculosis, malaria, tetanus toxin vaccination, chronic hepatitis of alcoholic origin [7] [14] [18] [19] [20]. However, it is knowledge that the use of HIV screening tests with low specificities has implications in public health including inclusion HIV negative people in ART programs and increase budgets in addition to inconveniences caused to patients.

3. Conclusion

The clinical case that we have just reported illustrates that it is still difficult for us (in Congo-Brazzaville) to adopt a conventional diagnostic approach for the management of human immunodeficiency virus or hepatitis B and C viruses infections. Rapid diagnostic orientation tests remain to this day useful tools in the diagnostic algorithm for viral infections in developing countries. However, scientific validation and by international and local health authorities of the must be required before they are made available to practitioners. The knowledge and the rigorous application of the diagnostic algorithms of viral infections by the practitioners as mentioned earlier will make it possible both to save resources and to take good care of the patients. Having said that, it is important to implement an integrated Hepatitis/HIV national program in Congo-Brazzaville.

References

- [1] Larsen, C., Pialoux, G., Salmon, D., *et al.* (2005) Prévalence des co infections par les virus des hépatites B et C dans la population VIH, France Juin 2004. BEH; 23: 109-112.
- [2] Patrick, Y. (2010) Prise en charge médicale des personnes infectées par le V I H : Recommandations du groupe d'experts, Rapport 2010, Paris, Ministère de la santé et des sports, La documentation française, 417 p.3.
- [3] Bossali, F., Taty-Taty, R., Houssissa, P., *et al.* (2012) Séroprévalence de la co-infection hépatite B, hépatite C et VIH chez les femmes accouchées à la maternité de l'hôpital Adolphe Sicé de Pointe-Noire en 2010. *J. Afr. Hépatol. Gastroentérol*, **6**, 315-319.
- [4] Matthews, P.C., A.M., Goulder, P.J.R. and Klenerman, P. (2014) Epidemiology and Impact of Coinfection with Hepatitis B and Hepatitis C Virus in Sub-Sahara Africa. *Journal of Clinical Virology*, **61**, 20-33. <https://doi.org/10.1016/j.jcv.2014.05.018>
- [5] Aghokeng, A.F., Mpoudi-Ngole, E., Dimodi, H. and Atem-Tambe, A. (2009). Inaccurate Diagnosis of HIV-1 Group M and O Is a Key Challenge for Ongoing

- Universal Access to Antiretroviral Treatment and HIV Prevention in Cameroun. *PloS One*, **4**, e7702. <https://doi.org/10.1371/journal.pone.0007702>
- [6] Lejon, V., Ngoyi, D.M., Ilunga, M. and Beelaert, G. (2010) Low Specificities of HIV Diagnosis Tests Caused by *Trypanosoma brucei gambiense* Sleeping Sickness. *Journal of Clinical Microbiology*, **48**, 2836-2839. <https://doi.org/10.1128/JCM.00456-10>
- [7] Lienhard, R. (2011) Pièges en sérologie infectieuse. *Rev Med Suisse*, **7**, 1964-1967.
- [8] Patrick, Y. (2010) Co-infections par le VIH et les virus des hépatites. Chap. 14. In *Prise en charge médicale des personnes infectées par le VIH*. 254-285.
- [9] HAS (2015) Autotests de dépistage du VIH: Information à l'intention des professionnels de santé et des associations, 54.
- [10] Haute Autorité de Santé (2011) Stratégies de dépistage biologique des hépatites virales B et C : recommandations en santé publique: Argumentaire, 114 p.
- [11] Haute Autorité de Santé (2011) Stratégies de dépistage biologique des hépatites virales B et C : recommandations en santé publique: Synthèse—avis des groupes de travail et de lecture et recommandation de la HAS, 33 p.
- [12] Haute Autorité de Santé (2014) Place des tests rapides d'orientation, diagnostique (TROD) dans la stratégie de dépistage des de l'hépatite C: Recommandation en santé publique, 106 p.
- [13] SFLS (2012) XIIIe Congrès National de la Société Française de Lutte contre le Sida Jeudi 25 et vendredi 26 octobre 2012.
- [14] Kania, D. (2010) Sérologies VIH indéterminées par utilisation des tests rapides pour le diagnostic de l'infection à VIH chez les femmes enceintes à Bobo-Dioulasso, Burkina Faso, Diplôme d'Etudes Approfondies (DEA), option Biologie Appliquée et Modélisation des systèmes biologiques, Institut du Développement Rural de Bobo-Dioulasso, 70 p.
- [15] Haute Autorité de Santé (2008) Dépistage de l'infection par le VIH en France: modalités de réalisation des tests de dépistages: Argumentaire, 198 p.
- [16] Nagalo Bolni Marius (2010) Diagnostic moléculaire, par RT/PCR, du VIH-1 et sécurité transfusionnelle, Diplôme d'Etudes Approfondies en Biotechnologie, Option: Génétique/Biologie Moléculaire, Université de Ougadougou, 104 p.
- [17] Haute Autorité de Santé (2014) Place des tests rapides d'orientation, diagnostique (TROD) dans la stratégie de dépistage des de l'hépatite C: Recommandation en santé publique, 106 p.
- [18] Pr Daniel Dhumeaux, *Prise en charge des personnes infectées par les virus de l'hépatite B ou de l'hépatite C: rapport de recommandations 2014*, 524 p.
- [19] Lacroix, N. (2013) Comparaison de l'acceptation des tests de dépistage rapide de l'hépatite C par voie capillaire chez deux populations de personnes fréquentant des structures de prévention et de soins de l'usage de drogues aux seuils d'exigence différents, Thèse de Doctorat en médecine, Université de Lorraine, 88 p.
- [20] Boislève, J.B. (2004) *L'essentiel de la biologie médicale*. 3rd Edition, JB Boislève, , 111 p.