

# Surgical Treatment of Calcaneal Comminuted Intrarticular Fractures: Long-Term Follow-Up

M. Haddad, Z. Horesh, M. Soudry, N. Rosenberg

Laboratory of Musculoskeletal Research, Orthopedic Department, Rambam-Health Care Campus, Haifa, Israel  
Email: [nahumrosenberg@hotmail.com](mailto:nahumrosenberg@hotmail.com)

Received 27 May 2014; revised 27 June 2014; accepted 27 July 2014

Copyright © 2014 by authors and Scientific Research Publishing Inc.  
This work is licensed under the Creative Commons Attribution International License (CC BY).  
<http://creativecommons.org/licenses/by/4.0/>



Open Access

---

## Abstract

There is a controversy whether the comminuted calcaneal fractures should benefit more from conservative or from surgical treatment. Aiming to contribute to this unsolved clinical question we reviewed the long-term outcome (up to 96 months) of in 44 patients (mean age 35 years) with 47 calcaneal fractures who were treated surgically. In these patients open reduction and internal fixation were performed using a calcaneal reconstruction plate. The functional outcome was measured according to the Rowe Score and the level of pain by Visual Analog Scale. The objective outcome was estimated by the current radiographs. The clinical results were good to excellent in 69% of patients. Poor outcome observed in one patient who developed Complex Regional Pain Syndrome in his foot. The radiographic evaluation showed satisfactory reconstruction (according to the Bohler angle measurements) in 35 of operated calcanei. These results indicate on the satisfactory outcome of surgical treatment in the majority of the patients who were diagnosed with comminuted fracture of calcaneus.

## Keywords

Calcaneus, Fracture, Surgical Treatment

---

## 1. Introduction

Descriptions of calcaneal fractures exist since 1839 when compression mechanism causing this type of fracture has been described [1]. In 1843 Malgaigne described this fracture and proposed a classification [1]. The treatment of these fractures has been evolved since then from conservative to surgical approach [1]-[5].

The initial publications of surgical treatment of calcaneal fracture were by Leriche [6]. He performed open

reduction and internal fixation of these fractures by metal staples and screws.

Over the years an unsatisfactory outcome of the closed reduction of these fractures became evident and surgical treatment by open reduction became more popular. Reports which compared conservative treatment vs. open reduction internal fixation showed a better outcome for the latter [6]-[10].

Several methods exist for internal fixation of calcaneal fractures, e.g. percutaneous, internal fixation, cannulated screws, plating and by use of special calcaneal plate [11] [12].

In the current study we report on series of patients with comminuted calcaneal fractures who were treated surgically by open reduction and internal fixation by plate and screws.

## 2. Materials and Methods

Between 1998 and 2006, 44 patients with 47 intrarticular comminuted calcaneal fractures were treated surgically. Three patients of this group sustained bi lateral fracture of the calcaneus. Thirty six fractures were caused after a fall from height, 8 fractures were as a consequence of a road accident, 2 fractures after a blast injury and one after sports injury.

The diagnostic criteria for surgical treatment were a displaced intra-articular fracture in patients without additional systemic clinical morbidity. This group of patients consisted of 6 women and 38 men in the age range of 20 - 66 years (mean 35 years).

The follow-up period was from 8 to 96 months (mean 42 months). 60% of the patients had more 4 years of follow up (**Table 1**).

Preoperatively the patients were evaluated radio graphically by a lateral and Harris views [15]. The radiographic diagnosis was according to the depression and the displacement of the fragments and according to the Boehler angle measurement from the lateral view radiographs (normal values in the range of 20° - 40°) [13]. Additionally a CT scan of the injured foot was done in all patients for detection of the depressed fragments. The CT scan evaluation was based on Sanders classification [14] that grades the calcaneal fractures according the number of the fragments and their displacement. Three calcanei were diagnosed with Sanders grade II fracture, thirty four calcanei had Sanders grade III fracture and ten calcanei with Sanders grade IV fracture indicating that all the fractures were intrarticular with comminution.

One surgeon (HZ) experienced in orthopedic trauma operated all these patients.

In all the patients the surgical procedure was postponed from 10 to 14 days post trauma, until foot swelling has been subsided.

The surgical approach for open reduction and internal fixation was performed using lateral approach, "L" shaped incision with full thickness subperiosteal flap was utilized. Using this surgical procedure is very important to prevent infections, peripheral nerve damage and skin necrosis.

Following the open reduction of the fracture and a calcaneal reconstruction locked plate was used for internal fixation. Tri calcium sulfate bone substitute (Osteoset™) was used to fill the created cavities adjacent to the fracture (**Figure 1**).

A simple elastic dressing was used after the operation. The rehabilitation started one week after the surgery, when the patients felt able to move actively their tibio-talar and the sub-talar joints, guided by physiotherapist. There was no weight bearing for 12 weeks.

In order to evaluate pain on the follow up we used the VAS (visual analogue scale) were the patient quantified

**Table 1.** Follow up distribution in the study group.

No. of calcanei operated	Years of follow up
13 (28%)	6 - 8 y
15 (32%)	4 - 6 y
10 (21%)	2 - 4 y
7 (15%)	1 - 2 y
2 (4%)	Less than 1 y
TOTAL 47	

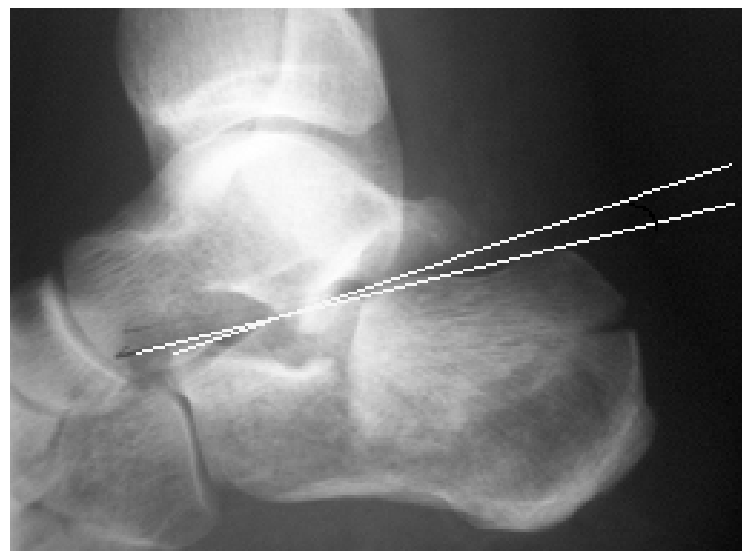his pain by giving a number from 0 to 10 (0—without pain, 10—severe pain).

The functional outcome was done according to the Rowe Score [15]. This score is divided to 5 categories: Pain, limp, limitation of activity, need for ambulation appliance and ability to perform work tasks. Points are given according to a scale. Score are given from zero, as a poor outcome, to 100, as an excellent result (Table 2).

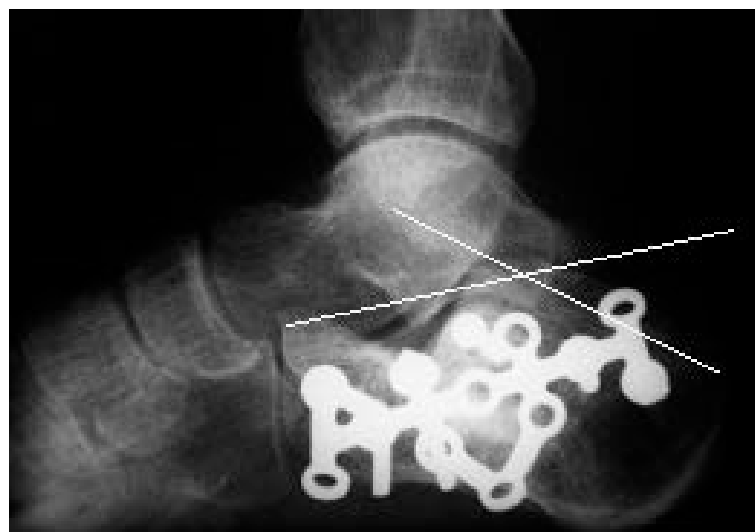
### 3. Results

After two years, 55% of the patients were free or with very low level of pain (VAS 0 - 2) and after 8 years this rate rose to 76% (Table 3).

The follow up by the Rowe score at the sixth month's visit, 74% had a fair or poor functional score. This score has been improved after two, and then four years. At the eighth year follow up, 69% declared an excellent



(a)



(b)

**Figure 1.** Example case. Radiographs of 30 years old men who sustained calcaneal fracture in his left foot. (a) Before the surgery; (b) Four years after surgery. A good restoration of the Boehler angle (the sharp angle between the two drawn lines) from  $10^\circ$  to  $38^\circ$  is evident after surgical treatment.

**Table 2.** The outcome determination by Rowe score [15].

Total Score	Outcome
90 - 100	Excellent
70 - 85	Good
40 - 65	Fair
<40	Poor

**Table 3.** Estimation of pain level by the Visual Analogue Scale (VAS) on the follow up of patients following surgery.

VAS	6 months	2 years	4 years	8 years
	No. of calcanei	No. of calcanei	No. of calcanei	No. of calcanei
10	4 (9%)	1 (2.5%)	0	0
8	12 (25%)	1 (2.5%)	0	0
6	12 (25%)	3 (7%)	2 (7%)	0
4	13 (28%)	13 (33%)	6 (19%)	3 (23%)
2	5 (11%)	12 (30%)	9 (29%)	4 (30%)
0	1 (2%)	10 (25%)	14 (45%)	6 (47%)
Total	47	40	31	13

or good outcome (**Table 4**).

The roentgenographic evaluation showed that the Boehler angle, which is an indicator for the calcaneal three dimensional distortion [13] [16], was corrected to a normal in 35 (74%) of calcanei (**Figure 1, Table 5**).

The width of the calcaneus, measured on the Harris view, was compared to the opposite side. Preoperatively in the majority of the cases a significant enlargement was noted. After the surgery, 83% of the calcanei had a width approximately similar (in the range of 10% of SD) to the opposite side (**Table 5**).

The main complications in this series of patients were:

- Local infection in 4 patients (8% of the study group). These patients were treated successfully with oral antibiotics. No deep infection was observed.
- Minor local sensory neurological deficit was found in 7 patients (17% of the study group). These patients suffered from hypoesthesia or anesthesia of the lateral side of the foot.
- Skin necrosis of the flap occurred in one patient. Coverage by a sural flap (musculo-cutaneous rotational flap from the soleus) [17] was done with excellent results.
- 3 patients had dehiscence of the wound after minimal local skin necrosis and were successfully treated locally.
- One patient suffered from severe pain intractable pain origination from the subtalar joints. After unsuccessful medical treatment, a subtalar arthrodesis was performed but a Complex Regional Pain Syndrome (CRPS) was developed in the operated foot, therefore this patient eventually underwent a below knee amputation.

## 4. Discussion

The preferred treatment of the intra-articular fractures of the calcaneus is still controversial. While the conservative treatment was the previous gold standard, open reduction and internal fixation by calcaneal plate became gradually more popular, although it is technically demanding. Recently more studies compared the two methods of treatment showing more advantage for the surgical treatment [5] [9].

In current report inclusion criteria for surgical treatment were of displaced intra-articular fracture, *i.e.* Sanders grade II, III and IV. In the previous reports these types of calcaneal fractures showed mostly unsatisfactory outcome when treated conservatively [6] [8].

**Table 4.** Follow up of the patients by the function evaluation (Rowe score).

Row Score	6 months	2 years	4 years	8 years
	No. of calcanei	No. of calcanei	No. of calcanei	No. of calcanei
Excellent	0	11 (27%)	5 (16%)	2 (15%)
Good	12 (26%)	13 (33%)	17 (55%)	7 (54%)
Fair	16 (34%)	9 (22%)	7 (23%)	3 (23%)
Poor	19 (40%)	7 (18%)	2 (6%)	1 (8%)
Total	47	40	31	13

**Table 5.** Calcaneal radiographs six months after surgery.

Boehler angle (deg)	<20	Normal	>40
25 < N < 40	9 (20%)	35 (74%)	3 (6%)
Enlargement %	<10%	Normal $\pm$ 10%	>10%
Harris view*	0	39 (83%)	8 (17%)

\*The calcaneal width in comparison to the unaffected foot.

The radiographic predictor of these fractures' outcome, *i.e.* the Boehler angle, was corrected in 35 cases (74%) in the present series and the calcaneal width, as measured radio graphically by the Harris view, was brought to normal in 39 (83%) of treated calcanei, indicating on satisfactory objective outcome in the majority of the patients following surgery. Additionally on the follow-up after 4 years almost 50% of the patients became pain free, and most of the others suffered moderate pain (VAS 2 - 4). The rate of pain relief rose to 77% of VAS of 2 or lower indicating slow but progressive improvement of pain. Severe pain was still noticed in 2 patients after two years of follow up. Of these two patients in one a devastating complication of CRPS has been developed.

Evaluation of functional outcome showed that almost 66% had excellent and good function after 4, 6 and 8 years post operatively (according to the Rowe score). These patients gained their rehabilitation gradually over first two postoperative years.

## 5. Conclusion

According to our results in a small series of patients with comminuted intrarticular calcaneal fractures, surgical treatment by open reduction and internal fixation using calcaneal plate brought a favorable functional outcome in the majority, around in two third of the study group, of patients in a long term. The serious complication rate was relatively low, and the majority of the complications were minor. We would like to emphasize the importance of the correct diagnosis of the involvement of the calcaneal articular surface in order to decide on the necessity for surgical treatment of these complicated fractures.

## References

- [1] Sanders, R. (2000) Displaced Intra-Articular Fractures of the Calcaneus. *The Journal of Bone and Joint Surgery*, **82A**, 225-250.
- [2] Herscovici Jr., D., Widmaier, J., Scaduto, J.M., Sanders, R.W. and Walling, A. (2005) Operative Treatment of Calcaneal Fractures in Elderly Patients. *The Journal of Bone and Joint Surgery*, **87A**, 1260-1264. <http://dx.doi.org/10.2106/JBJS.D.01765>
- [3] Huang, P.J., Huang, H.T., Chen, T.B., Chen, J.C., Lin, Y.K., Cheng, Y.M. and Lin, S.Y. (2002) Open Reduction and Internal Fixation of Displaced Intraarticular Fractures of the Calcaneus. *Journal of Trauma-Injury Infection & Critical Care*, **52**, 946-950. <http://dx.doi.org/10.1097/00005373-200205000-00021>
- [4] Macey, L.R., Benirschke, S.K., Sangeorzan, B.J. and Hansen, S.T. (1994) Acute Calcaneal Fractures: Treatment Options and Results. *The Journal of the American Academy of Orthopaedic Surgeons*, **2**, 36-43.

- [5] Sanders, R., Fortin, P., DiPasquale, T. and Walling, A. (1993) Operative Treatment in 120 Displaced Intraarticular Calcaneal Fractures. Results Using a Prognostic Computed Tomography Scan Classification. *Clinical Orthopaedics and Related Research*, **290**, 87-95.
- [6] Kundel, K., Funk, E., Brutscher, M. and Bickel, R. (1996) Calcaneal Fractures: Operative versus Nonoperative Treatment. *Journal of Trauma-Injury Infection & Critical Care*, **41**, 839-845. <http://dx.doi.org/10.1097/00005373-199611000-00012>
- [7] Dooley, P., Buckley, R., Tough, S., McCormack, B., Pate, G., Leighton, R., Petrie, D. and Galpin, B. (2004) Bilateral Calcaneal Fractures: Operative versus Nonoperative Treatment. *Foot & Ankle International*, **25**, 47-52.
- [8] Barla, J., Buckley, R., McCormack, R., Pate, G., Leighton, R., Petrie, D. and Galpin, R. (2004) Displaced Intraarticular Calcaneal Fractures: Long-Term Outcome in Women. *Foot & Ankle International*, **25**, 853-856.
- [9] Brauer, C.A., Manns, B.J., Ko, M., Donaldson, C. and Buckley, R. (2005) An Economic Evaluation of Operative Compared with Nonoperative Management of Displaced Intra-Articular Calcaneal Fractures. *The Journal of Bone and Joint Surgery*, **87A**, 2741-2749.
- [10] Buckley, R., Tough, S., McCormack, R., Pate, G., Leighton, R., Petrie, D. and Galpin, R. (2002) Operative Compared with Nonoperative Treatment of Displaced Intra-Articular Calcaneal Fractures: A Prospective, Randomized, Controlled Multicenter Trial. *Journal of Bone and Joint Surgery*, **84**, 1733-1744.
- [11] Babin, S.R., Graf, P., Katzner, M. and Schwingt, E. (1982) Reconstruction-ostéosynthèse par plaque vissée des fractures thalamiques du calcaneum. *Revue de Chirurgie Orthopédique et Réparatrice de l'Appareil Moteur*, **68**, 557-569.
- [12] Nehme, A., Chaminade, B., Chiron, P., Fabie, F., Tricoire, J.L. and Puget, J. (2004) Percutaneous Fluoroscopic and Arthroscopic Controlled Screw Fixation of Posterior Facet Fractures of the Calcaneus. *Revue de Chirurgie Orthopédique et Réparatrice de l'Appareil Moteur*, **90**, 256-264. [http://dx.doi.org/10.1016/S0035-1040\(04\)70102-6](http://dx.doi.org/10.1016/S0035-1040(04)70102-6)
- [13] Loucks, C. and Buckley, R. (1999) Bohler's Angle: Correlation with Outcome in Displaced Intra-Articular Calcaneal Fractures. *Journal of Orthopaedic Trauma*, **13**, 554-558. <http://dx.doi.org/10.1097/00005131-199911000-00007>
- [14] Daftary, A., Haims, A.H., and Baumgaertner, M.R. (2005) Fractures of the Calcaneus: A Review with Emphasis on CT. *Radiographics*, **25**, 1215-1226. <http://dx.doi.org/10.1148/rg.255045713>
- [15] Buckley, R.E. and Meek, R.N. (1992) Comparison of Open versus Closed Reduction Of Intraarticular Calcaneal Fractures: A Matched Cohort in Workmen. *Journal of Orthopaedic Trauma*, **6**, 216-222. <http://dx.doi.org/10.1097/00005131-199206000-00014>
- [16] Knight, J.R., Gross, E.A., Bradley, G.H., Bay, C. and LoVecchio, F. (2006) Boehler's Angle and the Critical Angle of Gissane Are of Limited Use in Diagnosing Calcaneus Fractures in the ED. *American Journal of Emergency Medicine*, **24**, 423-427.
- [17] Mueller, J.E., Ilchmann, T. and Lowatscheff, T. (2001) The Musculocutaneous Sural Artery Flap for Soft-Tissue Coverage after Calcaneal Fracture. *Archives of Orthopaedic and Trauma Surgery*, **121**, 350-352. <http://dx.doi.org/10.1007/s004020000238>