

# Symptomatic Trigeminal Neuralgia Pain Treatment Options—A Case Report

**Abed Rahman**

Anesthesiology and Pain Management, JHS Hospital of Cook County, Chicago, IL, USA

Email: [Arahman2@cookcountyhhs.org](mailto:Arahman2@cookcountyhhs.org)

Received 28 July 2015; accepted 27 September 2015; published 30 September 2015

Copyright © 2015 by author and Scientific Research Publishing Inc.

This work is licensed under the Creative Commons Attribution International License (CC BY).

<http://creativecommons.org/licenses/by/4.0/>



Open Access

---

## Abstract

**Background:** Severe pain is present in trigeminal neuralgia and may be devastating and debilitating. There are multiple modalities of nonsurgical techniques to help with pain and functionality. **Patient:** 47 year old male with 6 year history of facial pain due to trigeminal neuralgia. **Treated at outside institution with medical management.** **Intervention:** Left gasserian ganglion pulsed radiofrequency with acupuncture and biofeedback by pain psychologist. **Results:** >50% pain relief for greater than 12 months with improved quality of life. **Conclusions:** Trigeminal neuralgia may be one of the most challenging disorders to treat in the field of pain management due to the refractory and prolonged course of pain. The purpose of this article is to report the difficult treatment requiring true multidisciplinary treat to treat the severity of the patients pain. Due to his young age we opted for the pulsed radiofrequency as opposed to the thermal radiofrequency.

## Keywords

**Trigeminal Neuralgia, Pulsed Radiofrequency, Acupuncture, Biofeedback**

---

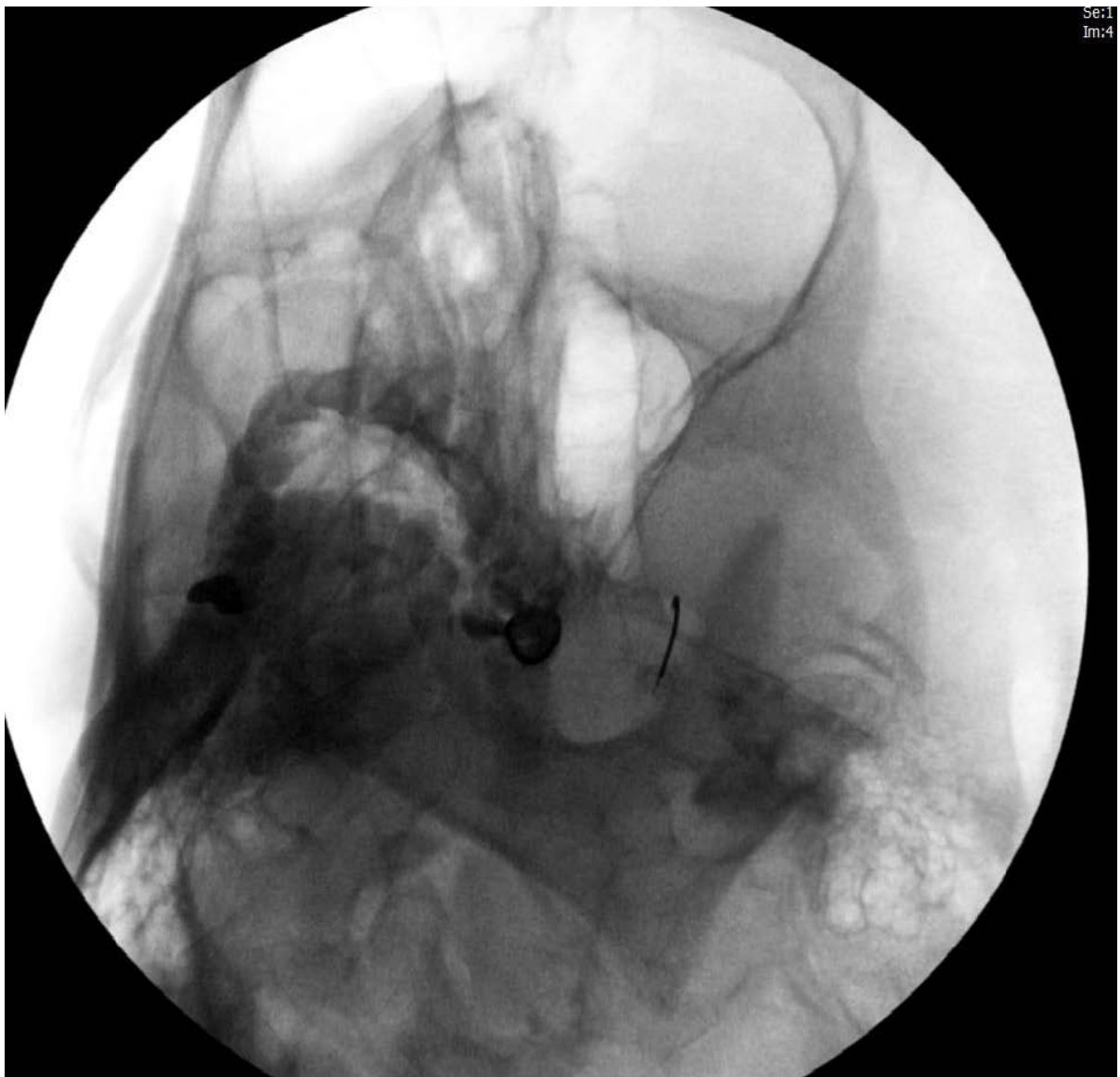## 1. Introduction

Treatment in trigeminal neuralgia (TN) must be adapted in each patient. Physicians and surgeon must be conscious of medical, interventional, surgical, and radiation treatment modalities to suggest ideal management. Despite the long history of trigeminal neuralgia in the medical literature there is no clear single treatment for all patients. The spectrum of treatment is based on severity and disability of the disease. It ranges from neuropathic agents and optimizing medications, gasserian ganglion injections, pulsed, thermal and chemical neurolysis, surgical options, radiation therapy, along with complementary and alternative treatment. Given the risks and benefits of the different treatments, patients opt for the less invasive alternatives.

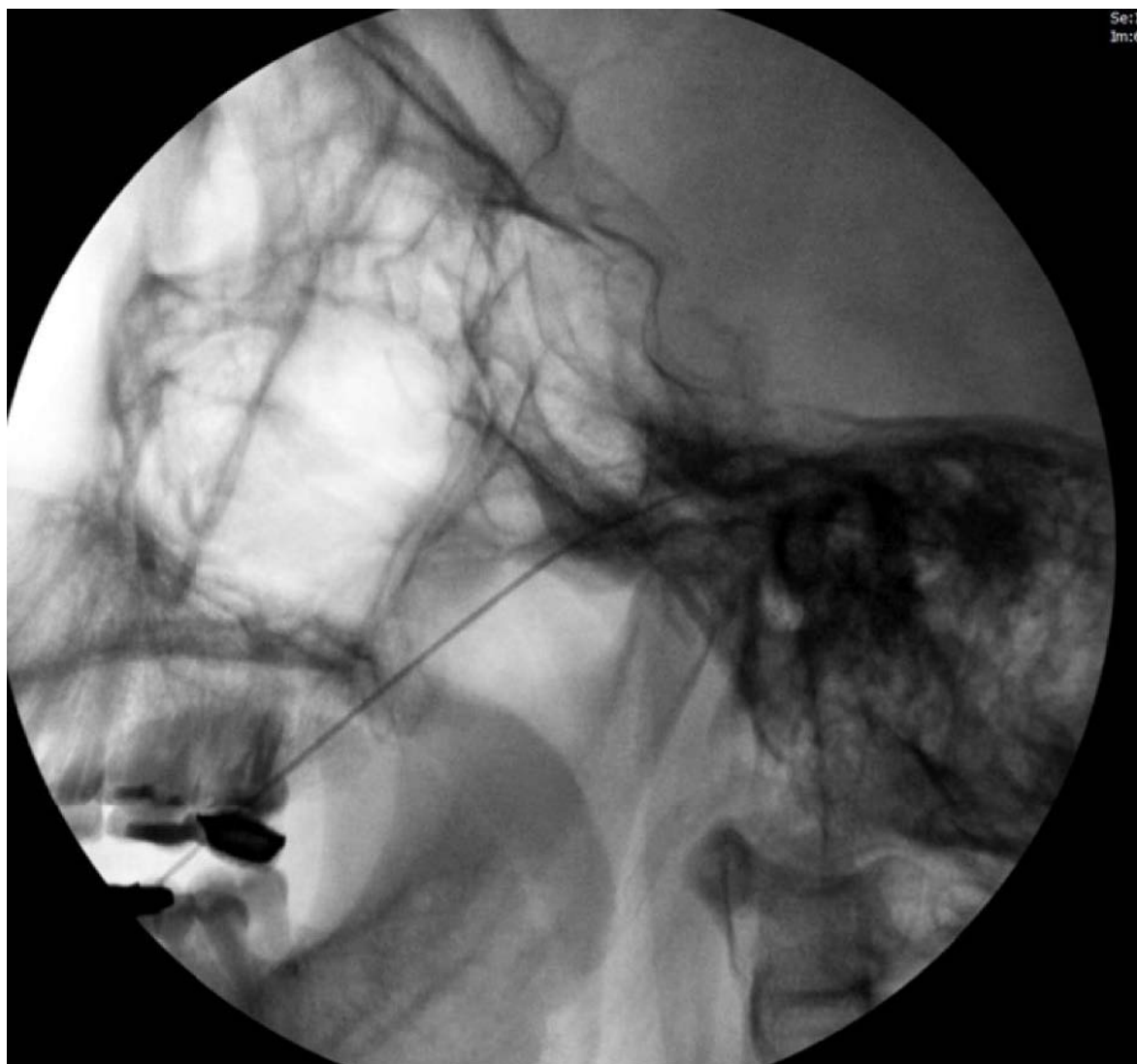
## 2. Case

Consent from patient to report case. A 47 year old male presents to the pain center with a 6 year history of left sided facial pain, diagnosed as trigeminal neuralgia by his neurologist. Since seeing his neurologist 5 years prior and being worked up for multiple sclerosis, his pain was treated mildly with maximal dosing of carbamazepine, baclofen, gabapentin and acetaminophen/hydrocodone. At the time, he reported his daily average pain using numerical rating scale [1] was 9.1/10. He was in constant severe pain and had been frequenting the emergency department of local hospitals every 2 - 3 months due to the pain requiring intravenous analgesics.

Given the patients severity of pain on the initial presentation a sphenopalatine block using a nasal applicator was used for immediate 40% relief for 2 days. He was at that time referred to the pain psychologist for cognitive biofeedback and to the acupuncturist. Over the next 14 months the patient underwent 2 left gasserian ganglion blocks with short term 2 month 80% relief. Finally, pulsed radiofrequency [2] of the left gasserian ganglion **Figure 1** & **Figure 2** utilizing fluoroscopy with 75% relief for the next 12 months. During the time of injections and afterwards he continued care with the pain psychologist and acupuncture. His average numerical rating scale on pain diary 4.2/10.



**Figure 1.** Left foramen ovale entry during pulsed radiofrequency [3].



**Figure 2.** Needle tip visualized within gasserian ganglia vicinity [4].

### 3. Discussion

Trigeminal neuralgia is a recognized disorder characterized by brief paroxysms or severe, unilateral, electric pain in the trigeminal distribution. The incidence is approximately 4 per 100,000 people [5].

It is typically seen in adults over the age of 50 with a slight increase in men over woman [6].

The disorder appears to arise from chronic, partial injury to the trigeminal sensory nerve root as it enters the brainstem [7]-[9].

In 5% to 10% of the cases, a phenomenon known as, symptomatic trigeminal neuralgia occurs. This results from causes such as multiple sclerosis or benign tumor (schwannoma, meningioma) in the cerebellopontine angle.

Trigeminal neuralgia is associated with brainstem demyelination in those with multiple sclerosis [10].

The diagnosis of trigeminal neuralgia is based on clinical history with specific criteria such as paroxysmal pain, confined to trigeminal pattern, unilateral, normal sensory exam and pain may be triggered by light touch [11].

Trigeminal neuralgia may be one of the most challenging disorders to treat in the field of pain management due to the refractory and prolonged course of pain. The purpose of this article is to report the difficult treatment requiring true multidisciplinary treat to treat the severity of the patient's pain.

Trigeminal neuralgia, also referred to as, tic douloureux requires medical and surgical treatments to achieve success [12]. A strong and sometimes overlooked treatment adjunct are the complementary and alternative medicine [13] [14]. Treatment typically starts with antiepileptic drugs, most commonly gabapentin, carbamazepine or oxcarbazepine. Baclofen may be added as an additional agent while titrating up to the desired therapeutic anticonvulsant level [15].

Surgical options range from injections to more invasive procedures. Initial steps as a pain physician is sphenopalatine injection, trigeminal nerve blockade followed by gasserian ganglion injection or pulsed radiofrequency [16].

Different forms of radiofrequency including pulsed, conventional, extended pulsed [13] have been attempted, as well as, chemical neurolysis.

Advanced surgical procedures are percutaneous retrogasserian radiofrequency lesion, posterior fossa microvascular decompression, gamma knife radiotherapy, these modalities may yield relief in up to 90% [17]-[19].

The combination of the injection, medical management by the neurologist, psychological treatment and acupuncture helped with the pain. Quality of life and activities of daily living were deemed to be “significantly” improved compared to prior to our treatment.

The case illustrates the need to reach out to other specialists and to incorporate alternative therapies early on in treatment for best outcomes.

#### 4. Summary

In summary, many treatments exist for trigeminal neuralgia. Each treatment option has risks, benefits, and varying efficacies in treating the disease. We have demonstrated, through this case report, that blockade of the gasserian ganglion through pulsed radiofrequency ablation should be considered as a potential treatment option in combination with other treatments when considering treatment options for patients who suffer from this debilitating and painful disease.

#### References

- [1] Brailo, V. and Zakrzewska, J.M. (2015) Grading the Intensity of Nondental Orofacialpain: Identification of Cutoff Points for Mild, Moderate, and Severe Pain. *Journal of Pain Research*, **8**, 95-104. <http://dx.doi.org/10.2147/JPR.S75192>
- [2] Thapa, D., Ahuja, V., Dass, C. and Verma, P. (2015) Management of Refractory Trigeminal Neuralgia Using Extended Duration Pulsed Radiofrequency Application. *Pain Physician*, **18**, E433-E435.
- [3] (2014) Patient Case Report Image. JHS Hospital of Cook County, Chicago.
- [4] (2014) Patient Case Report Image. JHS Hospital of Cook County, Chicago.
- [5] Zakrewska, J.M. (1997) Trigeminal Neuralgia. *Primary Dental Care*, **4**, 17-19.
- [6] Amols, W. (1969) Differential Diagnosis of Trigeminal Neuralgia and Treatment. *Headache*, **9**, 50-53. <http://dx.doi.org/10.1111/j.1526-4610.1969.hed0901050.x>
- [7] Bowsher, D. (1997) Trigeminal Neuralgia: An Anatomically Oriented Review. *Clinical Anatomy*, **10**, 409-415. [http://dx.doi.org/10.1002/\(SICI\)1098-2353\(1997\)10:6<409::AID-CA7>3.0.CO;2-J](http://dx.doi.org/10.1002/(SICI)1098-2353(1997)10:6<409::AID-CA7>3.0.CO;2-J)
- [8] Canavero, S., Bonicalzi, V. and Pagni, C.A. (1995) The Riddle of Trigeminal Neuralgia. *Pain*, **60**, 229-231. [http://dx.doi.org/10.1016/0304-3959\(94\)00196-L](http://dx.doi.org/10.1016/0304-3959(94)00196-L)
- [9] Carney, L.R. (1967) Considerations on the Cause and Treatment of Trigeminal Neuralgia. *Neurology*, **17**, 1143-1151. <http://dx.doi.org/10.1212/WNL.17.12.1143>
- [10] Kassirer, M.R. and Osterberg, D.H. (1987) Pain and Chronic Multiple Sclerosis: A Multimodal Approach. *Clinical Therapeutics*, **7**, 445-460.
- [11] White, J.C. and Sweet, W.H. (1969) Pain and the Neurosurgeon. 2nd Edition, Charles C Thomas, Springfield.
- [12] Brailo, V. and Zakrzewska, J.M. (2015) Grading the Intensity of Nondental Orofacial Pain: Identification of Cutoff Points for Mild, Moderate, and Severe Pain. *Journal of Pain Research*, **8**, 95-104. <http://dx.doi.org/10.2147/JPR.S75192>
- [13] Thapa, D., Ahuja, V., Dass, C. and Verma, P. (2015) Management of Refractory Trigeminal Neuralgia Using Extended Duration Pulsed Radiofrequency Application. *Pain Physician*, **18**, E433-E435.
- [14] Gronseth, G., Cruccu, G., Alksne, J., Argoff, C., Brainin, M., Burchiel, K., *et al.* (2008) Practice Parameter: The Diagnostic Evaluation and Treatment of Trigeminal Neuralgia (an Evidence-Based Review): Report of the Quality Stan-

- dards Subcommittee of the American Academy of Neurology and the European Federation of Neurological Societies. *Neurology*, **71**, 1183-1190. <http://dx.doi.org/10.1212/01.wnl.0000326598.83183.04>
- [15] Benzon, H.T., Rathmell, J.P., Wu, C.L., Turk, D.C. and Argoff, C.E. (2008) *Raj's Practical Management of Pain*. Fourth Edition, Mosby Elsevier, Philadelphia.
- [16] Tian, L.F. (2010) A Survey on Acupuncture Treatment of Trigeminal Neuralgia. *Journal of Traditional Chinese Medicine*, **30**, 68-76. [http://dx.doi.org/10.1016/S0254-6272\(10\)60018-0](http://dx.doi.org/10.1016/S0254-6272(10)60018-0)
- [17] Sweet, W.H. (1976) Controlled Thermocoagulation of Trigeminal Ganglion and Rootlets for Differential Destruction of Pain Fibers: Facial Pain Other than Trigeminal Neuralgia. *Clinical Neurosurgery*, **23**, 96-102.
- [18] Taha, J.M. and Tew Jr., J.M. (1997) Treatment of Trigeminal Neuralgia by Percutaneous Radiofrequency Rhizotomy. *Neurosurgery Clinics of North America*, **8**, 31-39.
- [19] Burchiel, K.J., Clarke, H., Haglund, M. and Loeser, J.D. (1988) Long Term Efficacy of Microvascular Decompression. *Journal of Neurosurgery*, **69**, 35-38.