



Neglected Dislocation of the Elbow: About 8 Cases and Review of Literature

Mohamed Fahsi*, Hamza Benameur, Othmane Hiba, Marwane Abouchane, Rachid Aitmouha, Mohamed Moujtahid, Ahmed Reda Haddoun, Mohamed Nechad

Department of Orthopaedic Surgery, Ibn Rochd Hospital, Casablanca, Morocco

Email: fahsiabdo@gmail.com, hamzabenameur@gmail.com, dr-othmane@hotmail.fr, abouchane123@gmail.com, aitmouharachid@gmail.com, m.moujtahid@gmail.com, a.hdoun@hotmail.com, m.nechad@gmail.com

Received 20 October 2015; accepted 7 November 2015; published 10 November 2015

Copyright © 2015 by authors and OALib.

This work is licensed under the Creative Commons Attribution International License (CC BY).

<http://creativecommons.org/licenses/by/4.0/>



Open Access

Abstract

The authors report eight cases of neglected dislocations of the elbow. The fracture-dislocations were included in our series. All patients benefited from a surgical reduction. In five cases, an internal fixation by K-wires was necessary. All patients benefited from physical therapy after removal of osteosynthesis material. After a mean follow-up of 20 months, we noted 50% of satisfactory functional results according to Mayo Elbow Performance Score. Neglected dislocations of elbow remain a rather frequent entity in developing countries. Its main cause is the negligence of patients and the recourse to traditional treatment. The prognosis of this injury remains reserved.

Keywords

Neglected, Dislocation, Elbow, Stiffness, Review

Subject Areas: Orthopedics

1. Introduction

Neglected dislocations of the elbow became exceptional in developed countries. However, they remain rather frequent in developing countries, because of the recourse of patients to the traditional medicine [1] [2], the misunderstanding of the gravity of the lesions and the difficulties of access to the specialized centers. They are defined as an untreated dislocation of the elbow dating 3 weeks or more [3]-[6]. The diagnosis of these injuries is obvious, in front of a deformed and stiff elbow with notion of old trauma of the elbow. The radiological examination confirms the diagnosis. The treatment is delicate because of the structural modifications that affect elbow. It constitutes a real therapeutic challenge for orthopedic surgeons.

*Corresponding author.

2. Materials and Methods

We report a retrospective study of eight cases of neglected dislocation of the elbow between January 2009 and December 2014. The raw data files were formatted in an excel spreadsheet. Our patients presented a dislocation of the elbow dating at least 3 weeks, fracture-dislocations were also included. The reduction was surgical in all cases. The post-operative fixation was performed by K-wires in 6 cases and by simple splint in the others. Three approaches were used: internal, external and combined. All patients were followed, wondered, examined clinically and radiologically. The mean follow-up was 20 months. We evaluated post-operative mobility, pain, stability of the elbow and resumption of the daily activity. We adopted the Mayo Elbow Performance Score to evaluate of our results (**Board 1**).

3. Results

The mean age of patients was 33 years (19 - 56). The majority of our patients were male (75%). Etiologies was dominated by the falls in 62.5% of cases, followed by the road accidents in 25% of cases then sports injuries in 12.5% of cases. Right upper limb was affected in 6 cases. The mean deadline of consultation was 57 days so two months after the trauma. 87.5% of patients were initially handled by traditional ways (Jbira, traditional massages). The clinical examination has noted, in our patients, a stiff elbow with flexion between 25° and 35°. In one case treated initially by Jbira in extension position, we have objective a stiffness in complete extension of the elbow. The radiography allowed us to determine the type of dislocation (**Figure 1**). The associated injuries (**Board 2**), intra-articular foreign bodies and the periarticular calcifications. CT-scan was realized for two of our

Board 1. Mayo elbow performance score.

Pain (max., 45 points)	
None (45 points)	
Mild (30 points)	
Moderate (15 points)	
Severe (0 points)	
Range of motion (max., 20 points)	
Arc > 100 degrees (20 points)	
Arc 50 to 100 degrees (15 points)	
Arc < 50 degrees (5 points)	
Stability (max., 10 points)	
Stable (10 points)	
Moderately unstable (5 points)	
Grossly unstable (0 points)	
Function (max., 25 points)	
Able to comb hair (5 points)	
Able to feed oneself (5 points)	
Able to perform personal hygiene tasks (5 points)	
Able to on shirt (5 points)	
Able to put on shoes (5 points)	

Board 2. Resume of our series results.

Cas	Age	Deadline (days)	Dislocation type	Associated fractures	Surgical approach	Fixation	Mayo score
1	29	21	Post	-	Paratricipital internal	splint	E
2	36	30	Post-Lat	Epitrochlea	Combined	H-U pinning	G
3	19	30	Post	Capitulum	Paratricipital internal	splint	G
4	32	21	Post	-	Combined	H-U pinning	G
5	21	90	Post	-	External	Combined pinning	F
6	45	60	Post	-	Combined	H-U pinning	F
7	30	90	Post	Epitrochlea	Combined	H-U pinning	F
8	56	120	Post	-	Combined	H-U pinning	P

H-U: humero-ulnar , (E) excellent, (g) good, (F) fair, (P) poor.

patients (Figure 2): it allowed to properly analyze the articular surface and the associated injuries, also to properly locate possible intra-articular foreign bodies. It helped us in orientation of therapeutic strategy.

All our patients were operated under loco-regional anesthesia. The surgical approach was combined (internal and external) in five cases, para-tricipital internal in two cases and by external approach in one case. After localization and neurolysis of the ulnar nerve, arthrolysis of the elbow, excision of periarticular osteoma and cleaning of surfaces and articular dimples, a reduction with confrontation of articular surfaces was realized. In two cases we did not realize fixation by K-wire, in five cases we realized a humero-ulnar fixation by K-wires and in one case a double K-wiring, humero-radial and humero-ulnar (Figure 3), no ligamentary repair was realized. The associated fractures were respected and immobilization was maintained during 4 to 6 weeks. The removing of k-wires was realized after 45 days. The post-operative suites were simple, no post-operative complication was found. The physiotherapy was maintained immediately after removing the immobilization. After an average follow-up of 20 months, the functional results were estimated by Mayo Elbow Performance Score based on 4 criteria: the pain, the mobility and the stability of the elbow as well as the resumption of the function of the upper limb. We objectified one excellent score, three good scores, three fair scores and one poor score.

4. Discussion

Neglected dislocations of the elbow considered rare in West are still frequent pathologies in developing countries. The delay of management of patients is often due to the initial recourse to traditional quacks [1]. These bonesetters use massages with forced manipulations and immobilization in extension which not only delays the diagnosis and the treatment, but also led to complications [7].

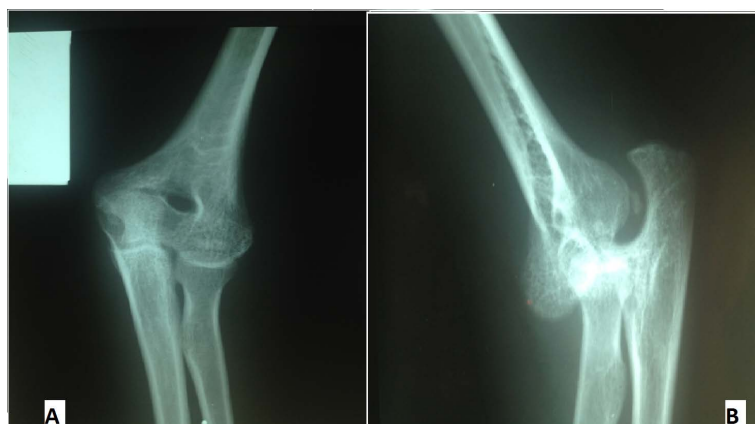

Figure 1. Face (A) and profile (B) X-ray showing a neglected dislocation of the elbow.

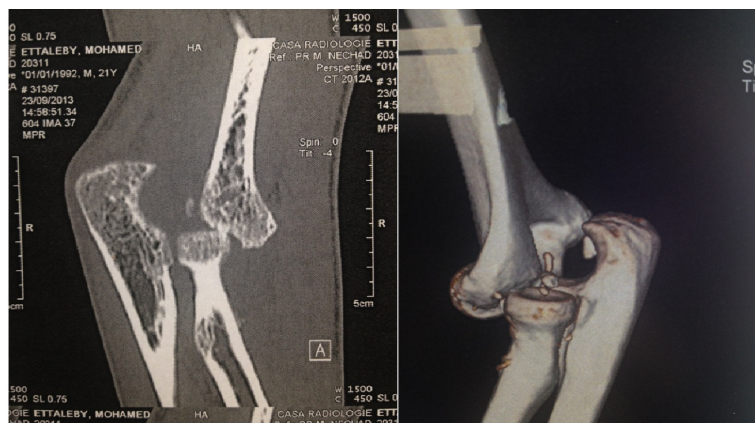


Figure 2. CT-scan of a neglected dislocation of the elbow presence of intra-articular foreign bodies.

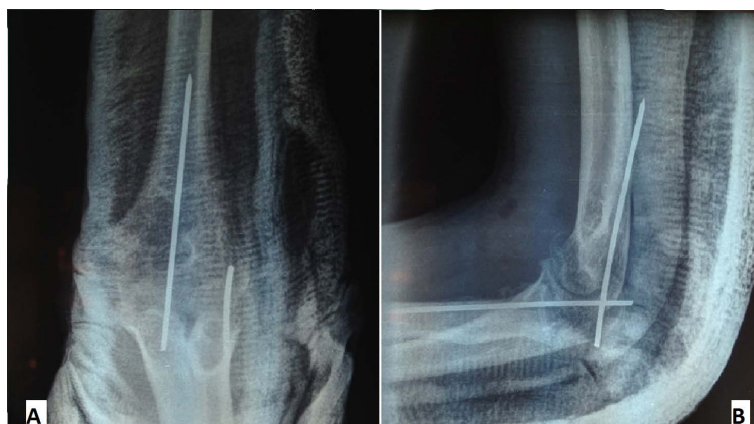

Figure 3. Postoperative X-ray control face (A) and profile (B) of a double k-wiring humero-radial and humero-ulnar.

Speed [8] and Cambell [9] reported the first studies led on this affection. Martini [10] reported in 1984 a series of 47 cases of neglected dislocation, only 25 cases were operated, he recommends the abstention in front of a stiffness on the verge of the functional adaptation and which can improve under physiotherapy. He also introduced the notion of functional stiffness when flexion of the elbow was situated between 80° and 90° and the not functional stiffness when flexion does not exceed 70° not allowing to assure the useful movements.

There seems to be a lack of consensus on treatment of dislocations of the elbow [11] [12]. Josefsson and coll. [13] indicated that there were no significant differences between the results of conservative and surgical treatment. One year later, in the same newspaper, Mehlhoff and coll. [14] reported a bad result profit after conservative treatment processing. Martini [10] prefers to abstain in front of a stiffness considered functional, what seems to us sensible especially with the high rate of bad results reported in the literature. Azmi *et al.* [15] reported 62.5% of bad results further to surgical reductions.

In the surgical treatment of these injuries, several technical processes can be used. The reduction with fixation in 90° of flexion by pinning after liberation of the joint. Several approaches are used whose choice depends on several elements: age of the injury, initial position of the elbow and the associated injuries. Then, a cleaning of the articular surfaces and the dimples is realized with excision of periarticular osteomas and intra-articular foreign bodies. In cases where the elbow is fixed in extension with retraction of the tricipital tendon, a plastic surgery to lengthen the latter with V-Y technic can be realized by posterior approach.

Masataka [16] reported in a series of 3 cases of neglected dislocations treated by posterior approach with reintegration or reconstruction of the ligament by using a transplant of the palmaris longus tendon. An early physiotherapy was maintained since second week on articulated orthosis. The results were excellent in all patients (mayo score of 97). A technique of stabilization by tendinous transplant taken in depends on the palmaris longus or the extensor carpi radialis longus, described in 1987 by Arafiles [17]. This technique allows an early mobilization of the elbow.

Jupiter [18] in 2002 reported five cases of neglected dislocations treated surgically then stabilized by an external fixation allowing an early passive mobilization. After a mean follow-up of 38 months, a stable and concentric reduction was obtained. Ait Essi *et al.* [19] reported a neglected dislocation of elbow in a teenager which was reduced with an enlargement of the great sigmoid cavity. Very good results were observed after six months of follow-up. The resection of the humeral pallet is also a part of the therapeutic arsenal of these injuries and seems to be superior for the pronosupination [20] but it is a mutilating technique which presents a risk of instability and decrease of the strength of the limb.

5. Conclusion

The forecast of these grave injuries remains reserved, several technical processes exist for the treatment processing. The techniques of reconstructions and ligamentary stabilization reported in the literature give better results by allowing an early mobilization, only way to prevent the stiffness of the elbow.

Declaration of Interest

The authors declare that there are no conflicts of interest.

References

- [1] Mehta, S., Sud, A., Tiwari, A. and Kapoor, S.K. (2007) Open Reduction for Late-Presenting Posterior Dislocation of the Elbow. *Journal of Orthopaedic Surgery (Hong Kong)*, **15**, 15-21.
- [2] Elzohairy, M.M. (2009) Neglected Posterior Dislocation of the Elbow. *Injury*, **40**, 197-200. <http://dx.doi.org/10.1016/j.injury.2008.05.034>
- [3] Freeman III, B.L. (1998) Old Unreduced Dislocations. In: Crenshaw, A.H., Ed., *Campbell's Operative Orthopaedics*, 9th Edition, Mosby, St. Louis, 2673-2674.
- [4] Mehta, S., Sud, A., Tiwari, A. and Kapoor, S.K. (2007) Open Reduction for Late-Presenting Posterior Dislocation of the Elbow. *Journal of Orthopaedic Surgery (Hong Kong)*, **15**, 15-21.
- [5] Naidoo, K.S. (1982) Unreduced Posterior Dislocations of the Elbow. *The Journal of Bone & Joint Surgery*, **64**, 603-606.
- [6] Rockwood, C.A. (1996) Treatment of Old Unreduced Posterior Dislocation of Elbow. In: Rockwood, C.A., Ed., 4th Edition, *Rockwood and Green's Fracture in Adults*, 4th Edition, Lippincott-Raven, Philadelphia, 975-976.
- [7] Coulibalya, N.F., Tiemdjoa, H., Sanea, A.D., Sarr, Y.F., Ndiaye, A. and Seyea, S. (2012) Posterior Approach for Surgical Treatment of Neglected Elbow Dislocation. *Orthopaedics & Traumatology: Surgery & Research*, **98**, 552-558. <http://dx.doi.org/10.1016/j.otsr.2012.03.006>
- [8] Speed, J.S. (1925) An Operation for Unreduced Posterior Dislocation of the Elbow. *Southern Medical Journal*, **18**, 193-198. <http://dx.doi.org/10.1097/00007611-192503000-00007>
- [9] Campbell, W.C. (1929) Malunited Fractures and Unreduced Dislocations the Elbow. *JAMA*, **92**, 122-128. <http://dx.doi.org/10.1001/jama.1929.02700280026009>
- [10] Martini, M., Benselama, R. and Daoud, A. (1984) Neglected Luxations of the Elbow. 25 Surgical Reduction. *Revue de Chirurgie Orthopédique et Réparatrice de l'Appareil Moteur*, **70**, 305-312.
- [11] Josefsson, P.O., Johnell, O. and Gentz, C.F. (1984) Long-Term Sequelae of Simple Dislocation of the Elbow. *The Journal of Bone and Joint Surgery, American Volume*, **66**, 927-930.
- [12] Ohno, Y., Shimizu, K. and Ohnishi, K. (2005) Surgically Treated Chronic Unreduced Medial Dislocation of the Elbow in a 70-Year-Old Man: A Case Report. *Journal of Shoulder and Elbow Surgery*, **14**, 549-553. <http://dx.doi.org/10.1016/j.jse.2004.08.006>
- [13] Josefsson, P.O., Gentz, C.F., Johnell, O. and Wendeberg, B. (1987) Surgical versus Non-Surgical Treatment of Ligamentous Injuries Following Dislocation of the Elbow Joint. A Prospective Randomized Study. *The Journal of Bone and Joint Surgery, American Volume*, **69**, 605-608.
- [14] Mehlhoff, T.L., Noble, P.C., Bennett, J.B. and Tullos, H.S. (1988) Simple Dislocation of the Elbow in the Adult. Results after Closed Treatment. *The Journal of Bone and Joint Surgery, American Volume*, **70**, 244-249.
- [15] Azmi, I., Razak, M. and Hyzan, Y. (1998) The Results of Treatment of Dislocation and Fracture-Dislocation of the Elbow: A Review of 41 Patients. *Medical Journal of Malaysia*, **53**, 59-70.
- [16] Majima, M., Horii, E. and Nakamura, R. (2007) Treatment of Chronically Dislocated Elbows: A Report of Three Cases. *Journal of Shoulder and Elbow Surgery*, **16**, e1-e4. <http://dx.doi.org/10.1016/j.jse.2006.09.003>
- [17] Arafies, R.P. (1987) Neglected Posterior of the Elbow. A Reconstruction Operation. *The Journal of Bone and Joint Surgery*, **69**, 199-202.
- [18] Jupiter, J.B. and Ring, D. (2002) Treatment of Unreduced Elbow Dislocations in the Hinged External Fixation. *The Journal of Bone and Joint Surgery, American Volume*, **84-A**, 1630-1635.
- [19] Ait Essi, F., Rafai, M., Largab, A. and Trafeh, M. (2005) Neglected Fracture-Dislocation of the Elbow: Surgical Reduction with Enlarging Osteoplasty of the Trochlear Notch. *Chirurgie de la Main*, **24**, 177-180. <http://dx.doi.org/10.1016/j.main.2005.04.006>
- [20] Di Shino, M., Breda, Y., Grimaldi, F.M., Lorthioir, J.M. and Merrien, Y. (1990) Surgical Treatment of Neglected Elbow Dislocations. Report of 81 Cases. *Revue de Chirurgie Orthopédique et Réparatrice de l'Appareil Moteur*, **76**, 303-310.