



Oncoplasty's Contribution in Breast Cancers: About 48 Cases

Amine Rafik, Mounia Douiri, Naima Bahechar, Abdessamad Chlihi

National Center of Burn and Plastic Surgery, Casablanca, Morocco

Email: Aminerafik8@gmail.com

Received 23 January 2015; accepted 8 February 2015; published 13 February 2015

Copyright © 2015 by authors and OALib.

This work is licensed under the Creative Commons Attribution International License (CC BY).

<http://creativecommons.org/licenses/by/4.0/>



Open Access

Abstract

Introduction: Oncoplasty has developed for 20 years in order to avoid potentially major deformations of conservative treatment. We report the results of our oncoplastic breast operations. **Patients and Methods:** We conducted a descriptive and retrospective study of 48 patients treated by oncoplastic technique in the national center of burn and plastic surgery in the U.H. IBN-ROCHD of Casablanca between 2011 and 2014. Patient and tumor characteristics, as well as information on the procedures and complications, were collected from clinical records. **Results:** Forty-eight cases were reviewed. The tumors were processed for the majority of invasive ductal carcinoma pT2. Seven patients had an inadequate surgical margin. About histology, the rate of recovery for non-positive margins was significantly lower in the CCI alone than that in other types. Morbidity was 14.5% and the average delayed to adjuvant treatment of 72 days. The symmetrization rate was 24%. In terms of oncological results, during a median follow-up of 22 months, the rate of local recurrences was 13%. **Conclusion:** The oncoplastic operations offer tools for breast conservation in patients and otherwise is destined for mastectomy or poor esthetic outcome. This study shows that the goal of surgical therapy is to identify patients who are suitable for oncoplastic surgery. Proper pre-operative evaluation and diagnosis, surgical planning, adequacy of resection, and pathological evaluation are essential.

Keywords

Oncoplastic Surgery, Breast Cancer, Breast-Conservation Surgery

Subject Areas: Clinical Trials, Epidemiology, Global Health, Gynecology & Obstetrics, Oncology, Public Health, Surgery & Surgical Specialties, Women's Health

1. Introduction

The oncoplastic surgery's purpose is the integration of the neo-breast in the body image; it allows the tumor's

exeresis while leaving the breast with normal curve thanks to a glandular reshaping [1]. However, it leads to volume reduction, source of asymmetry comparing to the other breast. Gestures of symmetrization (immediate or postponed) can be realized to improve the comfort if the patient wishes so.

Through this study, we aimed to estimate our experience about oncoplastic surgery and we wished to discuss practical questions: about the oncoplastic surgery's indications, about the carcinologic results, and about the morbidity.

2. Patients and Methods

From January 1st, 2011 till January 31st, 2014, we studied retrospectively all the patients admitted in the national center of burnt and plastic surgery in the U.H. IBN-ROCHD of Casablanca, treated by oncoplastic surgery.

The studied parameters concerned the operated population's characteristics, the tumors, the surgical techniques, the post-operating morbidity, the resumption's rates of positive margins, the node analysis' results, and the carcinological follow-up.

The statistical analysis of all the files' information was recorded in a Microsoft Excel file allowing the data analysis.

3. Results:

3.1. Population's Characteristics

From January 2011 till January, 2014, 48 patients were treated by oncoplastic surgery. All the patients had an average age of 44 years old (extremes: 22 - 68). The tumor's circumstances of discovery were clinical in 67% of the cases and infra clinical in 33% of the cases.

3.2. Tumors' Characteristics

The tumors' distribution in the quadrants of the breast found out mainly lower and external tumors (**Figure 1**).

The radiological tumoral average size was of 20.4 mm (extremes: 0 - 73 mm), while the oncoplastic surgery was suggested, for an average of 20.2 mm (extremes: 5 - 52 mm).

The anatomopathology was underlined in 97 % of the cases in preoperative (**Table 1**).

Tumors were unifocal in 83.3% of the cases, bifocal in 14.6 % of the cases, in these cases; tumors were in the same quadrant. We note one case of multifocal micro calcifications limited to a quadrant of the breast dealing with a ductal carcinoma *in situ*.

3.3. Surgery Techniques

We estimated our various techniques according to the glandular exeresis spot (**Table 2**).

3.4. Surgical Results

On the 48 oncoplastic surgery, the rate of resumption for positive margins sites was 14.5%. All the patients having a tumorectomy patch with positive margins had a surgical resumption by total mastectomy (MT). The anatomopathological analysis of there sumpted pieces found out infiltrating ductal carcinomas in seven cases.

The average duration of hospitalization was 3.5 days (extremes from 0 to 7 days). We had six post-operating complications: that is a rate of 12.5% of morbidity. As complication, we faced hematoma in three cases, an abscess in 1 case. A surgical resumption was necessary for 2 cases in front of the areola mamma enecrosis (nipple necrosis).

3.5. Oncological Results

Over an average follow-up of 22 months, without histological distinction, the local recurrence rate was 13%. The 5-year survival could not be calculated due to the lack of the study's retrospect.

4. Discussion

In 1990, German W. Audretsch Düsseldorf called oncoplastic surgery all surgical techniques, which combine a

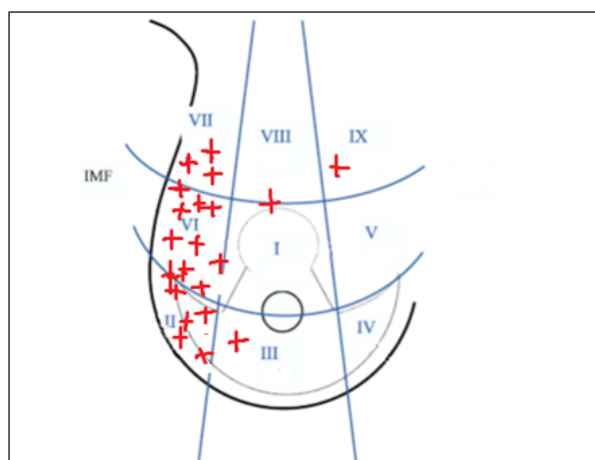


Figure 1. Distribution of tumor-quadrant diagram according to Mc Culey [2].

Table 1. Tumors characteristic's in our series (n = 48).

	Number (n)	Rate (%)
1) <u>Tumor's size:</u>		
• pT1a/b	10	20.8
• pT1c	21	43.7
• pT2	17	35.4
2) <u>Histological type:</u>		
• Ductal carcinoma	35	72.9
• Lobular carcinoma	13	27.1
3) <u>Lymph node dissection:</u>		
• N0	28	58.3
• N1	20	42.7
4) <u>Number of foci:</u>		
• One	40	83.3
• Two	7	14.6
• Multifocal micro calcifications	1	2.1

Table 2. Used operating techniques (n = 48).

	Number (n)	Rate (%)
External plasty	34	70.8
Superior pedicle or lower posterior	10	20.8
Round block	4	10.2

breast cancer conservative treatment to breast plastic surgery techniques [3]. It allows in some difficult circumstances to avoid performing a complete mastectomy when a simple conservative treatment will bring aesthetically unsatisfactory results. Apart from inflammatory cancers, multifocal cancers depend on total mastectomy [4]. All the other circumstances can potentially be indications for oncoplastic treatment. As long advocated by Clough, some tumor sites, such as lower quadrant or the central region, are excellent indications to avoid difficult sequelae to repair [5]. An indication of more accessory oncoplastic techniques is the gigantomastia, embarrassing for the patient's comfort, but it may increase the morbidity of radiotherapy, especially in the practice of overprinting (boost) [2]-[6]. In our series, the oncoplastic treatment was made mainly for large tumors (majority of P T2). Our data concerned patients at risk of significant glandular distortion as far as tumor's volume is concerned over the inadequate breast volume, or the tumor's relatively unfavorable localization (Figure 2).

The importance of healthy borders is correlated with the decrease of local recurrence [7]-[10].

In retrospective series, the rate of unhealthy sites varies from 8% to 18.9% of the cases [2] [11]-[13] for on-

coplastic surgery, while the rate of unhealthy sites varies between 15% and 20% for the standard conservative surgery. Our rate of positive margins after oncoplastic treatment (14.5%) seems comparable to the published series on oncoplastic surgery and those on conventional conservative treatments as well (Table 3).

It has been suggested to reduce the rate of positive margins, to make borders' extemporaneous evaluation [14]. In the series of Olsen *et al.*, extemporaneous evaluation, and per-operative resections helped to reduce the rate of secondary excision. This extemporaneous evaluation is the problem of feasibility. Returns to unhealthy margins were made by mastectomy in our series. The evaluation, as accurate as possible of the extension of the initial lesion (MRI), the caution regarding oncoplastic indications while the tumor is badly limited, and the quota of exclusively *in situ* or associated tumors, should limit the RBNS rate and the risk of secondary resumption.

The morbidity would be between 15% and 30% [15]-[17], a little bit higher than the conventional conservative surgery is, estimated at approximately 10% [12] [16] [18]. In addition, main complications underlined in the literature after oncoplasty are healing disorders, abscesses, hematomas, cases of partial or complete nipple necrosis. In our series, the complication rate was 12.5%. The average hospital stay was 3.5 days, less than in the study of Staub (5.2 days), or of Giacalone (4 days). These complications may require further surgery in less than 5% of the cases, mainly in case of hematoma, nipple pain [17] [19]-[22]. In our study, the rate of reoperation was 4.1% and was mainly for nipple necrosis.

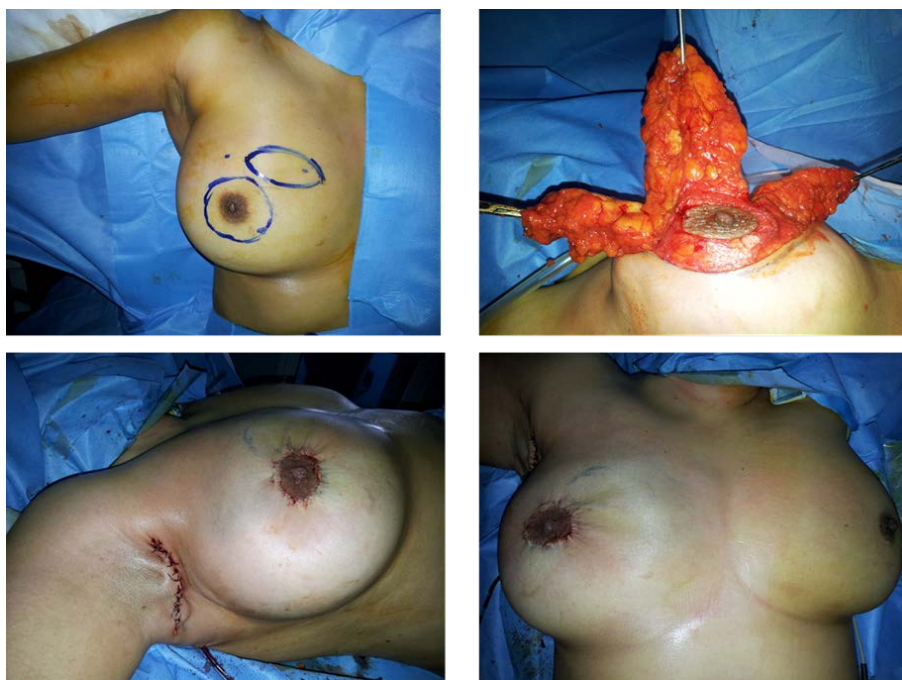

Figure 2. A 43-year-old woman with a palpable tumor at the upper medial quadrant of her right breast. An oncoplastic resection of 300 g was performed. Histology showed a ductal carcinoma and axillary lymph node status was 4/14. Immediate postoperative outcome is presented.

Table 3. Literature's results in the retrospective studies on oncoplasty.

Authors	Clough 2003	Rietjens 2007	Staub 2008	Fitoussi 2010	Tuomo 2010	Oscar 2012	Our study
Patients number	101	148	298	540	90	221	48
pT	-	pT2	pT2	pT2	pT1	20.5	pT2
RBNIS rate (%)	32%	9%	13.1%	18.9%	16.2%	12.7%	14.5%
Follow up (months)	-	74	52	49	26	30	22
Locale recurrence rate (%)	9.4%	3%	6.5%	6.8%	-	-	13%

5. Conclusion

For twenty years, the limits of conservative treatment have not ceased to be pushed in order to reduce the number of radical mastectomies, improve the surgical borders quality and reduce the aesthetic sequelae after radiotherapy treatment. Oncoplastic techniques help to avoid a mastectomy where simple conservative treatment is not doable. Our study shows that these techniques have convincing results as far as morbidity, resumption rates for unhealthy borders and oncological results are concerned.

Conflict of Interest

No conflict.

References

- [1] Meretoja, T.J., Svarvar, C. and Jahkola, T.A. (2010) Outcome of Oncoplastic Breast Surgery in 90 Prospective Patients. *The American Journal of Surgery*, **200**, 224-228. <http://dx.doi.org/10.1016/j.amjsurg.2009.09.026>
- [2] McCulley, S.J. and Macmillan, R.D. (2005) Therapeutic Mammoplasty-Analysis of 50 Consecutive Cases. *British Journal of Plastic Surgery*, **58**, 902-907. <http://dx.doi.org/10.1016/j.bjps.2005.03.007>
- [3] Cothier-Savey, I., Rimareix, F. and Belichard, C. (2011) Principes généraux de la chirurgie oncoplastique et de la reconstruction mammaire immédiate et différée. <http://www.em-premium.com.doc-distant.univ-lille2.fr/article/20722>
- [4] Clough, K.B., Nos, C., Fitoussi, A., Couturaud, B., Inguenault, C. and Sarfati, I. (2008) Séquelles esthétiques du traitement conservateur des cancers du sein: Une classification pour les reconstructions après tumorectomie. *Annales de Chirurgie Plastique Esthétique*, **53**, 88-101. <http://dx.doi.org/10.1016/j.anplas.2008.01.001>
- [5] Clough, K.B., Kaufman, G.J., Nos, C., Buccimazza, I. and Sarfati, I.M. (2010) Improving Breast Cancer Surgery: A Classification and Quadrant per Quadrant Atlas for Oncoplastic Surgery. *Annals of Surgical Oncology*, **17**, 1375-1391. <http://dx.doi.org/10.1245/s10434-009-0792-y>
- [6] Benelli, L. (1990) A New Periareolar Mammoplasty: The "Round Block" Technique. *Aesthetic Plastic Surgery*, **14**, 93-100. <http://dx.doi.org/10.1007/BF01578332>
- [7] Garrido, I., Gangloff, D., Trocard, P., Wagner, A., Rafii, A., Chopin, N., et al. (2006) Les bonnes indications de l'oncoplastie. *Oncologie*, **8**, 714-723. <http://dx.doi.org/10.1007/s10269-006-0495-y>
- [8] Veronesi, U., Cascinelli, N., Mariani, L., Greco, M., Saccozzi, R., Luini, A., et al. (2002) Twenty-Year Follow-Up of a Randomized Study Comparing Breast-Conserving Surgery with Radical Mastectomy for Early Breast Cancer. *New England Journal of Medicine*, **347**, 1227-1232. <http://dx.doi.org/10.1056/NEJMoa020989>
- [9] Wolmark, N., Wang, J., Mamounas, E., Bryant, J. and Fisher, B. (2001) Preoperative Chemotherapy in Patients with Operable Breast Cancer: Nine-Year Results from National Surgical Adjuvant Breast and Bowel Project B-18. *Journal of the National Cancer Institute Monographs*, **30**, 96-102. <http://dx.doi.org/10.1093/oxfordjournals.jncimonographs.a003469>
- [10] Rietjens, M., Urban, C.A., Rey, P.C., Mazzarol, G., Maisonneuve, P., Garusi, C., et al. (2007) Long-Term Oncological Results of Breast Conservative Treatment with Oncoplastic Surgery. *Breast*, **16**, 387-395. <http://dx.doi.org/10.1016/j.breast.2007.01.008>
- [11] Staub, G., Fitoussi, A., Falcou, M-C. and Salmon, R-J. (2008) Résultats carcinologiques et esthétiques du traitement du cancer du sein par plastie mammaire. 298 cas. *Annales de Chirurgie Plastique Esthétique*, **53**, 124-134. <http://dx.doi.org/10.1016/j.anplas.2007.05.012>
- [12] Berry, M.G., Fitoussi, A.D., Curnier, A., Couturaud, B. and Salmon, R.J. (2010) Oncoplastic Breast Surgery: A Review and Systematic Approach. *Journal of Plastic, Reconstructive & Aesthetic Surgery*, **63**, 1233-1243. <http://dx.doi.org/10.1016/j.bjps.2009.05.006>
- [13] Naveau, A., Kane, A. and Rimareix, F. (2012) Place de l'oncoplastie dans le traitement des cancers du sein traités par chimiothérapie néo-adjuvante. *Cancer du sein: Surdiagnostic, surtraitement*. Springer, Paris, 396-397.
- [14] Spear, S.L., Pelletiere, C.V., Wolfe, A.J., Tsangaris, T.N. and Pennanen, M.F. (2003) Experience with Reduction Mammoplasty Combined with Breast Conservation Therapy in the Treatment of Breast Cancer. *Plastic & Reconstructive Surgery*, **111**, 1102-1109. <http://dx.doi.org/10.1097/01.PRS.0000046491.87997.40>
- [15] Fisher, B., Anderson, S., Bryant, J., Margolese, R.G., Deutsch, M., Fisher, E.R., et al. (2002) Twenty-Year Follow-Up of a Randomized Trial Comparing Total Mastectomy, Lumpectomy, and Lumpectomy Plus Irradiation for the Treatment of Invasive Breast Cancer. *The New England Journal of Medicine*, **347**, 1233-1241. <http://dx.doi.org/10.1056/NEJMoa022152>
- [16] Pezner, R.D., Tan, M.C., Clancy, S.L., Chen, Y-J., Joseph, T. and Vora, N.L. (2013) Radiation Therapy for Breast

- Cancer Patients Who Undergo Oncoplastic Surgery: Localization of the Tumor Bed for the Local Boost. *American Journal of Clinical Oncology*, **36**, 535-539. <http://dx.doi.org/10.1097/COC.0b013e318256efba>
- [17] Yang, S.H., Yang, K.H., Li, Y.P., Zhang, Y.C., He, X.D., Song, A.L., et al. (2008) Breast Conservation Therapy for Stage I or Stage II Breast Cancer: A Meta-Analysis of Randomized Controlled Trials. *Annals of Oncology*, **19**, 1039-1044. <http://dx.doi.org/10.1093/annonc/mdm573>
- [18] Achard, E. and Salmon, R.J. (2007) Reduction Mammoplasty in Breast Cancers of the Lower Quadrants. *Bulletin du Cancer*, **94**, 225-228.
- [19] Kaur, N., Petit, J-Y., Rietjens, M., Maffini, F., Luini, A., Gatti, G., et al. (2005) Comparative Study of Surgical Margins in Oncoplastic Surgery and Quadrantectomy in Breast Cancer. *Annals of Surgical Oncology*, **12**, 539-545. <http://dx.doi.org/10.1245/ASO.2005.12.046>
- [20] Losken, A., Styblo, T.M., Carlson, G.W., Jones, G.E. and Amerson, B.J. (2007) Management Algorithm and Outcome Evaluation of Partial Mastectomy Defects Treated Using Reduction or Mastopexy Techniques. *Annals of Plastic Surgery*, **59**, 235-242. <http://dx.doi.org/10.1097/SAP.0b013e31802ec6d1>
- [21] Olson, T.P., Harter, J., Muñoz, A., Mahvi, D.M. and Breslin, T. (2007) Frozen Section Analysis for Intraoperative Margin Evaluation during Breast-Conserving Surgery Results in Low Rates of Re-Excision and Local Recurrence. *Annals of Surgical Oncology*, **14**, 2953-2960. <http://dx.doi.org/10.1245/s10434-007-9437-1>
- [22] Iwuchukwu, O.C., Harvey, J.R., Dordea, M., Critchley, A.C. and Drew, P.J. (2012) The Role of Oncoplastic Therapeutic Mammoplasty in Breast Cancer Surgery—A Review. *Surgical Oncology*, **21**, 133-141. <http://dx.doi.org/10.1016/j.suronc.2011.01.002>

Scientific Research Publishing (SCIRP) is one of the largest Open Access journal publishers. It is currently publishing more than 200 open access, online, peer-reviewed journals covering a wide range of academic disciplines. SCIRP serves the worldwide academic communities and contributes to the progress and application of science with its publication.

Other selected journals from SCIRP are listed as below. Submit your manuscript to us via either submit@scirp.org or **Online Submission Portal**.

