



Neurological Pain as a Result of Mouthwash Usage—A Case Report

Ali Nankali

Adult Oral Health Centre, Queen Mary University, London, UK

Email: a.nankali@qmul.ac.uk, ali@nankali.co.uk

Received 24 July 2014; revised 10 September 2014; accepted 14 October 2014

Copyright © 2014 by author and OALib.

This work is licensed under the Creative Commons Attribution International License (CC BY).

<http://creativecommons.org/licenses/by/4.0/>



Open Access

Abstract

Pain in pharynx is one of the leading complaints raised by patients with the common diagnosis pointing to: sore throat, odynophagia, pharyngitis and tonsillitis [1]. Recently, an interesting case of a 47-year-old patient (male-dentist) who claimed to have acquired a sudden sharp pain in pharynx (throat) location was observed. The absurd strength of the pain prevented the patient to even hold short-length verbal communications. The preliminary examinations by a general practitioner (GP) failed to conclude anything from the examinations; therefore the patient was referred for further investigation by specialists. The additional tests and examinations such as laryngoscopy and MRI did not suggest any leads to an appropriate diagnosis either. Inadvertently, the patient had noticed a strong correlation between the pain and the daily mouthwash dose. This was later investigated further and confirmed by the patients' trial methods. Conclusion: In this case report, it is suggested that mouthwash may contaminate the oral soft tissue and cause a neurological pain.

Keywords

Chlorhexidine, Cetylpyridinium Chloride, Zinc Chloride, Throat Pain, Neurological Pain

Subject Areas: Dentistry, Otorhinolaryngology

1. Introduction

What was known?

Chlorhexidine and other chloride containing mouthwashes are regarded as the safest widespread type amongst other mouthwashes and are rarely associated with any related allergies or complications. It has not yet been determined exactly what component of the mouthwash could be the main source to the reported allergies; however a number of researches on this matter are being carried out [2].

Chlorhexidine's large and complicated molecule structure demonstrates different properties including anti-

bacterial effects (**Figure 1**).

Designated studies show that the antibacterial property of the chlorhexidine either alone or in junction with other substances is one reason of its high demand within dental industry [1] [2]-[5].

Cetylpyridinium chloride (CPC) and zinc chloride are other types of chloride containing substances that are used to reduce plaque and calculus. Oil-containing mouth rinses with zinc chloride, sodium fluoride and 0.05% cetylpyridinium chloride have been recognized to provide superior clinical benefits; they demonstrate increase in plaque and gingivitis reductions over 6 months.

2. Case Report

The patient was a 47-year-old male dentist lecturer at university with a history of frequent sudden sharp pains which were piqued during long speeches. The pain originally appeared during winter period after having a cold. The patient initially postponed his visit to the general surgery, as he believe the pain was simply generated by the cold suffered at the time. However, the concern was triggered once the pain persisted after two weeks since the cold was fully cured. Therefore, he made an appointment to see his medical general practitioner (GP). The GP insisted upon the patients blood tests after continuously reaching a dead end following numerous unsuccessful speculations. Fortunately for the patient, the blood test results did not highlight any abnormalities. Based on the negative results, the GP had decided to refer the patient for an examination by an ears-nose-throat (ENT) specialist in East Surrey Hospital, Redhill.

The Medical History was performed very deeply and the involved medical general practitioners could not find any old related sign or symptom to the presented claim. It also was demonstrating that nobody in patient family suffered similar pain according to the patients' best knowledge.

Intro-oral clinical examination completed by an ENT specialist did not detect any clinical aberrations either, and therefore patient was recommended a laryngoscopy on the same visit. The laryngoscopy would allow for explicit visuals of the vocal cords with its surrounded tissue. During the procedure the amount of nasal anesthetic spray had to be increased significantly by the ENT specialist as the expected affect from the first attempt did not fully deliver. After 40 minutes, the practitioner began the examination process and insert the laryngoscop through the nasal cavity. Alas, this examination attempt had also failed to demonstrate any pathology on the considered location. ENT specialist was only able to highlight a slight redness area which was swollen to a small degree.

A few months of suffered unclassified unceasing pain, serious concern was raised by the patient and he scheduled to meet the GP for the third time to discuss further. Patient insisted on a new referral to be examined by another ENT specialist to obtain second opinion.

During this period the characteristic of pain remained unchanged, however it began to have a substantial impact on the patients' career.

After a 1.5 month waitlisting period the patient was finally seen by another specialist (ENT) at the Barts Hospital in London. They also immediately carried out a laryngoscopy procedure and the report was identical to the former one. Therefore, the specialist decided to perform an MRI at the London Royal Hospital.

The MRI images failed to indicate on any diagnosis and as a result, professionals were left perplexed by the complexity of this particular case. Repeating the examinations after two months was the only suggested option they had.

The insufferable pain to gather with other complications had prompted the patient to begin his own medical research and investigation.

He began by investigating the medical and dental published articles he thought they may relate whilst carefully monitoring the level of pain on day to day basis. Unfortunately the articles did not point to any conclusions;

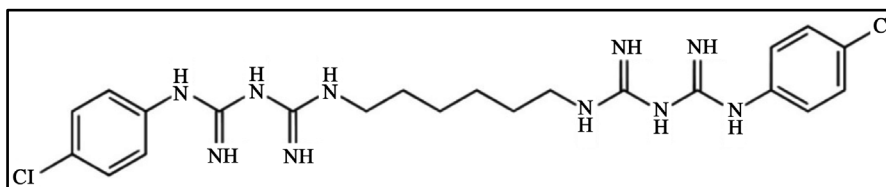


Figure 1. Molecular structure of chlorhexidine.

however, the pain analysis had gripped for his attention.

During a week the frequency of the appearing pain was declined noticeably, whilst in the following week the pain attacks were recorded only on specific conditions. The progress had motivated the patient to endure his investigation even though there were no solid conclusions to be made. However, a few weeks later the pain had gained its former momentum and put the patient back to square one.

With no results, the patient constructed an appropriate systematic strategy to review the occurrences during the examination period. The studies suggested the following facts:

- History started with a simple cold;
- Due to the nature of the teaching role the patient had decided to control the cold by doubling the frequency of mouthwash usage;
- After 2 - 3 weeks a new type of pain was detected with different types of characteristics;
- Patient maintained the elevated usage of the mouthwash;
- The frequency of pain attacked steadily increased;
- The clinical examinations were not successful;
- Specialists failed to diagnose the condition;
- MRI images were not able to provide any additional information;
- Patient finished his mouthwash;
- For one and half week, he gurgled a water-salt solution instead of the mouthwash liquid;
- Patient noticed a significant improvement;
- Patient purchased a mouthwash a few days after;
- The pain had returned but on this occasion with a non tolerable strength;
- The frequency of pain attacks increased;
- ...
- In addition no any other medication such as painkillers were used;
- There were no any signs of other diseases.

The facts had put the mouthwash into prospective and thus its theory was leading the investigation. The used mouth swash by patient is called “Aquaresh” and label displays the following ingredients: Aqua, Glycerin, PEG-60 Hydrogenated Castor Oil, Sodium Citrate, Aroma, Zinc Chloride, Sodium Fluoride, Cetylpyridinium Chloride, Methylparaben, Propylparaben, Sodium Saccharin, CI 42051, Contains: Sodium Fluoride [6].

It was decided to put the mouthwash treatment and on halt immediately, the results finally were successful and displayed an improvement in the patients’ condition.

Having gathered the appropriate analysis he decided to fully stop the mouthwash routine for a period of 3 weeks. The patients assumptions were confirmed once the pain finally disappeared. As a further study and out of sheer curiosity, he started to use the liquid again, and experienced the same symptoms. The correlation between the condition and the pain proved the root cause to be the mouthwash and so he concluded to stop using it for at least 3 months.

The graph one is designed to show the relation between the frequency of appeared pain and the frequency of mouthwash usage (**Graph 1**).

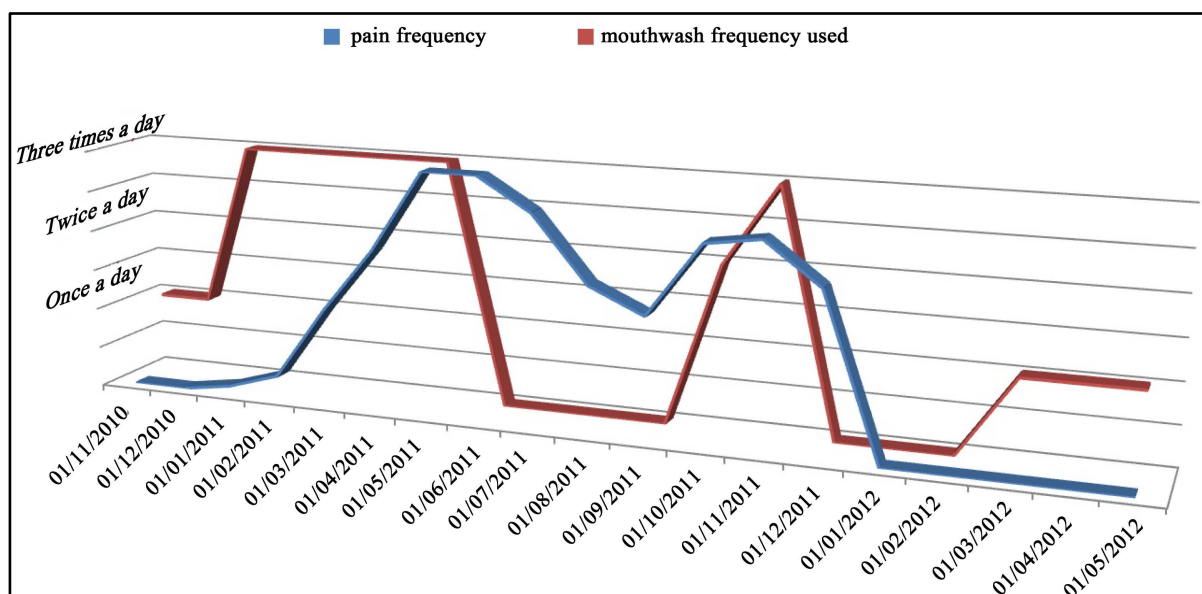
After this period, the patient began to use the mouthwash again on daily recommended basis and no pain attacks were recorded.

It has to be emphasised, the patient was a regular user of “Aquaresh” and he did not experience any drawbacks prior to this case.

3. Discussion

It is suggested that as a result of an increase to the daily amount of the mouthwash used, active mouthwash substances such as chlorhexidine may accumulate in the soft tissue. This explanation can be accepted as a cause to the reason why the soft tissue was observed with slight redness whilst being swollen. Furthermore, the contaminated soft tissue by another substance could be a possible reason of lower effect of normal anesthetics dose which was tried for the laryngoscopy process.

Although using proved trail and errors method established the direct relation between the mouthwash component and the pain, the study did not found exactly which of the mouthwash component caused the discussed neurological symptoms.



Graph 1. The relation between the frequency of appeared pain and the frequency of mouthwash usage.

4. Conclusion

A more thorough lab-based investigation should be performed to determine the exact advantages and withdraws of various mouthwashes widely available on the market. The results should then peruse the market providers to reconsider their labels and provide clear information especially in regards to daily dose limits for regular users along with the potential symptoms if the suggested measurements are abused.

References

- [1] Peltekis, G., Palaskas, D., Anyfantakis, D., Symvoulakis, E.K. and Kyrmizakis, D.E. (2012) Severe Throat Pain in Patients with Negative Oropharyngeal Examination: Four Case, Reports and Overview of the Literature. *Folia Medica (Plovdiv)*, **54**, 57-61. <http://dx.doi.org/10.2478/v10153-011-0098-2>
- [2] Chopra, V., Chopra, H. and Sharma, A. (2013) Allergic Urticaria: A Case Report of Rare Skin Allergy with a Common Mouthwash. *Indian Journal of Dermatology*, **58**, 85. <http://dx.doi.org/10.4103/0019-5154.105323>
- [3] Attin, R., Tuna, A., Attin, T., Brunner, E. and Noack, M.J. (2003) Efficacy of Differently Concentrated Chlorhexidine Varnishes in Decreasing Mutans Streptococci and Lactobacilli Counts. *Archives of Oral Biology*, **48**, 503-509. [http://dx.doi.org/10.1016/S0003-9969\(03\)00093-1](http://dx.doi.org/10.1016/S0003-9969(03)00093-1)
- [4] Matthijs, S. and Moradi Sabzevar, M. (2003) Chlorhexidine Varnishes in Dentistry. *Revue Belge de Medecine Dentair*, **58**, 9-20.
- [5] Herrera, D. (2013) Chlorhexidine Mouthwash Reduces Plaque and Gingivitis. *Evidence-Based Dentistry*, **14**, 17-18. <http://dx.doi.org/10.1038/sj.ebd.6400915>
- [6] Cortelli, S.C., Cortelli, J.R., Wu, M.M., Simmons, K. and Charles, C.A. (2012) Comparative Antiplaque and Antigingivitis Efficacy of a Multipurpose Essential Oil-Containing Mouthrinse and a Cetylpyridinium Chloride-Containing Mouthrinse: A 6-Month Randomized Clinical Trial. *Quintessence International*, **43**, e82-e94.