

Resistant Tremors and Unexplained Weight Loss Could Also Be a Sign of HIV

Mohammed Hamdy Ibrahim¹, Shivram Kumar², Janhavi Sirsat², Mohamed Khalid³,
Kiran Kumar³

¹Department of Neurology, GMC Hospital, Ajman, UAE

²Gulf Medical University, Ajman, UAE

³Department of Internal Medicine, GMC Hospital, Ajman, UAE

Email: mohamedhamdy_neuro2007@yahoo.com

Received 4 May 2015; accepted 27 July 2015; published 30 July 2015

Copyright © 2015 by authors and Scientific Research Publishing Inc.

This work is licensed under the Creative Commons Attribution International License (CC BY).

<http://creativecommons.org/licenses/by/4.0/>



Open Access

Abstract

This case study is done to show a different type of presentation of a HIV (Human Immunodeficiency Virus) patient. Neurological symptoms in HIV are normally due to Progressive Multifocal Leukoencephalopathy (PML) which is a reactivated infection caused by John Cunningham virus (JC virus). The disease causes fatal demyelination of the central nervous system (CNS). This case presented a 51-year-old Nigerian man who complained of resistant tremors and unexplained weight loss. The patient was suspected to have HIV when a MRI scan revealed T2/FLAIR hyper intensity of white matter which was a sign of PML. HIV ELISA was done and came back with a positive result. PML presenting in the form of tremors is very rare and more research is required to focus on the neurological presentation of HIV.

Keywords

Human Immunodeficiency Virus, Tremors, Progressive Multifocal Leukoencephalopathy

1. Introduction

According to WHO, “a case of HIV is defined as an individual with a HIV infection irrespective of clinical stage (including severe or stage 4 clinical disease, also known as AIDS) confirmed by laboratory criteria according to country definitions and requirements” [1]. WHO also states that “the human immunodeficiency virus (HIV) is a retrovirus that infects cells of the immune system, destroying or impairing their function. As the infection progresses, the immune system becomes weaker, and the person becomes more susceptible to infections” [2]. HIV is diagnosed based on positive HIV antibody test for two different antigens. It can additionally be diagnosed by

positive virological test for the HIV antigens [1].

In HIV, neurological symptoms mostly arise due to a disease called Progressive Multifocal Leukoencephalopathy (PML). Progressive Multifocal Leukoencephalopathy (PML) is fatal demyelinating disease of the central nervous system caused by the reactivation of JC polyomavirus in immunocompromised individuals. The JC virus (John Cunningham virus) causes demyelination by causing lysis of the oligodendrocytes [3]. The lytic lesions are detected by the T2 weighted MRI of the white matter of the affected brain [4]. Incidence of PML has increased with the appearance of acquired immune deficiency syndrome (AIDS) or use of potent immunosuppressive agents in multiple sclerosis or Crohn's disease [5].

This case study is done to show a different presentation of HIV in the form of neurological symptoms.

2. Case Presentation

A 51-year-old Nigerian man presents to the hospital with complaint of tremors resistant to medication and unexplained weight loss for the past 3 months. No significant past, family or social history.

On examination vitals were found to be normal. He is alert, oriented, conscious and stable. General inspection revealed a lean male in no distress with no signs of jaundice, dehydration or peripheral edema. Respiratory examination revealed bilateral equal air entry. Cardiovascular examination revealed normal S1 and S2 heart sounds. Cranial Nerve System (CNS) examination revealed intact sensation with a power of 5/5. The neurological examination also revealed bilateral coarse static tremors, bilateral brisk deep tendon reflex, bilateral post Babinski sign and bilateral positive rombergism.

Complete Blood Count (CBC), serum electrolytes and Renal Function Test (RFT) were normal. Erythrocyte Sedimentation Rate (ESR) was raised to 60 mm/hr. Prostatic specific antigen (PSA) was normal. Ultrasound of the Abdomen showed no significant findings and Chest X-ray showed Bronchitis. Magnetic Resonance Imaging (MRI) of the brain with contrast was done and revealed patchy confluent T2/FLAIR hyper intensity in the right lentiform nucleus, bilateral parieto-occipital and right inferior cerebellar peduncle indicating possibility of Progressive Multifocal Leukoencephalopathy (Figure 1).

HIV was suspected and a HIV Enzyme-Linked Immunosorbent Assay (ELISA) test was done which came back positive.

Anti-HIV treatment was started. Propranolol 40 mg twice a day was also given for the tremors.

The patient returned to Nigeria for follow up tests and treatment of HIV.

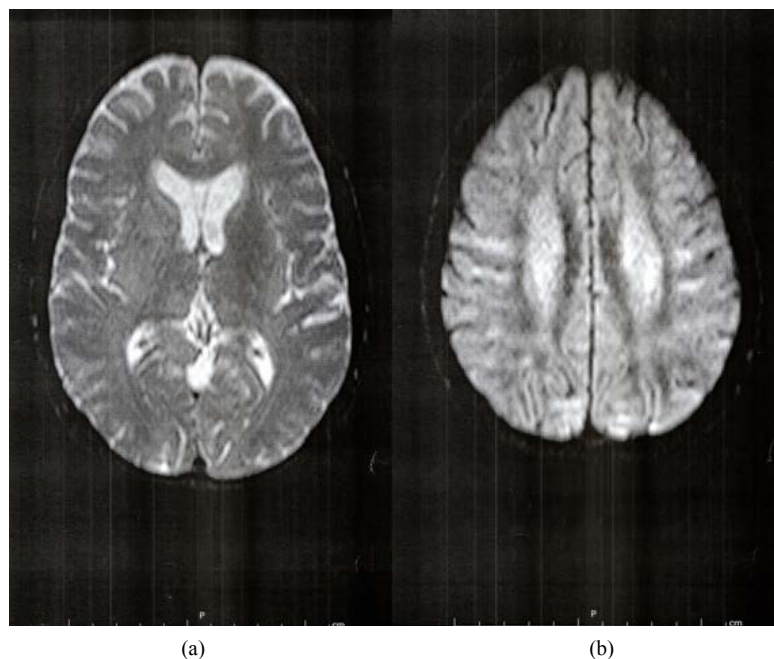


Figure 1. MRI brain with contrast showing T2/FLAIR hyper-intensity of white matter.

3. Discussion

According to a study, patients with PML initially presented with cognitive impairment, apallic state, movement disorders, visual impairment and paralysis [6].

Another study stated that movement disorders are identified in 3% of HIV patients but prospective follow up shows 50% of AIDS patients developing tremors, Parkinsonism and other extra pyramidal features. The study also states that tremors and hemiballism-hemichorea are the most common hyperkinesias normally caused in HIV positive patients due to opportunistic infections [7]. Although HIV patients develop tremors over the course of the disease, it is very rare that tremor is the first presenting complaint.

Sporer B, *et al.* showed a HIV patient presenting with progressive, persistent tremors. A MRI scan revealed bilateral hyper intensities in the mesencephalon, posterior pons and cerebellar peduncles and a CSF PCR revealed positive JC virus DNA. Hence, it was diagnosed as a posterior fossa tremor due PML lesions in that part of the brain [8]. Another study stated that movement disorders can be an initial manifestation of HIV but, dopaminergic dysfunction and predilection of the HIV infection affecting the subcortical structures was believed to be the underlying cause of the movement disorders [9]. Our study shows a similar etiology of tremor as that of the study done by Sporer *et al.*

The presentation of HIV in the form of resistant tremors and unexplained weight loss is very uncommon and the various etiologies are still not clearly understood and for this reason more research needs to be done to get a deeper understanding of the etiology and pathophysiology of tremors in HIV patients.

4. Conclusion

The patient in this case had presented with a history of only resistant tremors and weight loss. MRI of the brain revealed T2/FLAIR hyper-intensity indicating a possibility of a progressive multifocal leukoencephalopathy. HIV ELISA was done as a result which revealed to be positive. Studies have suggested that tremors can occur as a complication of AIDS and PML to be the cause of it. However, very few studies have shown tremor as an initial presentation of HIV and one study suggests it to be due to the dopaminergic dysfunction. More evidence-based research is required to get a clear understanding of the etiology and pathophysiology of tremors when it presents as one of the first symptoms in a HIV patient.

References

- [1] <http://www.who.int/hiv/pub/guidelines/HIVstaging150307.pdf>
- [2] http://www.who.int/topics/hiv_aids/en/
- [3] Korálnik, I.J. (2004) New Insights into Progressive Multifocal Leukoencephalopathy. *Current Opinion in Neurology*, **17**, 365-370. <http://dx.doi.org/10.1097/00019052-200406000-00019>
- [4] Nived, O., Bengtsson, A.A., Jönsen, A. and Sturfelt, G. (2008) Progressive Multifocal Leukoencephalopathy—The Importance of Early Diagnosis Illustrated in Four Cases. *Lupus*, **17**, 1036-41.
- [5] Berger, J.R. and Korálnik, I.J. (2005) Progressive Multifocal Leukoencephalopathy and the Use of Natalizumab—Unforeseen Consequences. *The New England Journal of Medicine*, **353**, 414-416. <http://dx.doi.org/10.1056/NEJMe058122>
- [6] Sakai, M., Inoue, Y., Aoki, S., Sirasaka, T., Uehira, T., Takahama, S., *et al.* (2009) Follow-Up Magnetic Resonance Imaging Findings in Patients with Progressive Multifocal Leukoencephalopathy: Evaluation of Long-Term Survivors under Highly Active Antiretroviral Therapy. *Japanese Journal of Radiology*, **27**, 69-77.
- [7] Cardoso, F. (2002) HIV-Related Movement Disorders. *CNS Drugs*, **16**, 663-668. <http://dx.doi.org/10.2165/00023210-200216100-00002>
- [8] Sporer, B., Seelos, K., Asmus, F., Boetzel, K. and Pfister, H.-W. (2005) Posterior Fossa Tremor Induced by HIV-Associated Progressive Multifocal Leukoencephalopathy. *European Neurology*, **53**, 96-97. <http://dx.doi.org/10.1159/000085507>
- [9] Tse, W., Cersosimo, M.G., Gracies, J.M., Morgello, S., Olanow, C.W. and Koller, W. (2004) Movement Disorders and AIDS: A Review. *Parkinsonism & Related Disorders*, **10**, 323-324. <http://dx.doi.org/10.1016/j.parkreldis.2004.03.001>