

Reconstruction Using a Free Vascularized Fibular Graft after Frozen Autograft Reconstruction for Osteosarcoma of the Distal Tibia: A Case Report

Seigo Suganuma, Kaoru Tada, Norio Yamamoto, Toshiharu Shirai, Katsuhiko Hayashi, Akihiko Takeuchi, Hiroyuki Tsuchiya

Department of Orthopaedic Surgery, Graduate School of Medical Science, Kanazawa University, Kanazawa, Japan.
Email: suganumaseigo1978@yahoo.co.jp

Received September 4th, 2012; revised October 8th, 2012; accepted November 10th, 2012

ABSTRACT

Recently we have been performing biological reconstruction for malignant bone tumors of the extremities using frozen autografts. Here we present a case treated with free vascularized fibular graft (FVFG) after this method. A 23-year-old man developed osteosarcoma in his left distal tibia. There was nonunion after frozen autograft reconstruction, which we treated with FVFG. Twenty-four months later, bridging between the host bone and the frozen autograft was achieved. Our department has achieved bone union in almost all cases, but we sometimes encounter cases of nonunion after this method because of delayed blood supply. In these instances, reconstruction using FVFG may represent an attractive choice for salvage treatment.

Keywords: Free Vascularized Fibular Graft; Frozen Autograft Reconstruction; Malignant Bone Tumor

1. Introduction

Recently there has been much progress in multidisciplinary treatment for malignant bone tumors including chemotherapy, radiation therapy and immunotherapy. Therefore, long-term survival can be expected in patients with malignant bone tumors of the extremities and importance has begun to be placed on preservation of functions in the affected extremities. Since January 1999, our department has been performing biological reconstruction in patients with malignant bone tumors of the extremities [1]. Our method involves reconstruction using tumor-bearing autologous bone graft treated with liquid nitrogen. Here we report a case of osteosarcoma of the distal tibia that was treated with frozen autograft reconstruction and subsequent reinforcement with a free vascularized fibular graft (FVFG).

2. Case Report

The patient was a 23-year-old man. He had pain in his left ankle joint without cause, and he consulted a nearby hospital. At the time, a malignant bone tumor was possible. Therefore, he was introduced to our hospital (Figure 1). He was diagnosed with an osteosarcoma of his left distal tibia by the needle biopsy. Then, he underwent preoperative chemotherapy with the K-2 protocol [2]

and subsequent frozen autograft reconstruction (Figure 2). At operation his distal tibia with the tumor was resected before freezing. The excised portion was subsequently frozen in liquid nitrogen for 20 minutes, thawed

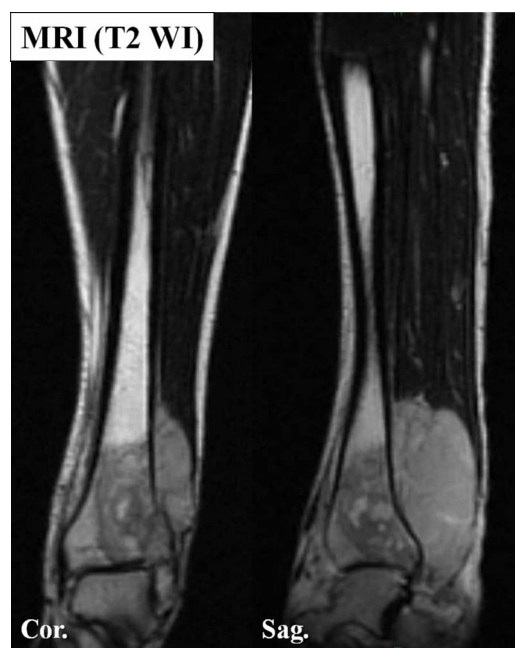


Figure 1. MRI showing osteosarcoma at the left distal tibia.

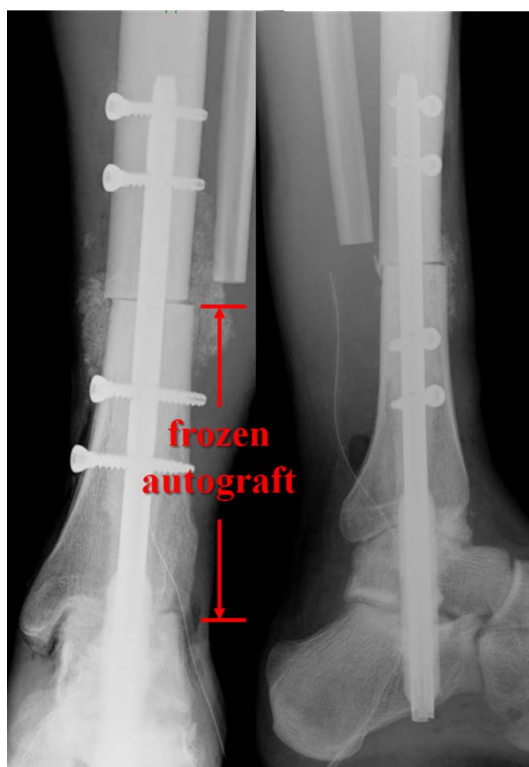


Figure 2. Tumor excision and subsequent frozen autograft reconstruction.

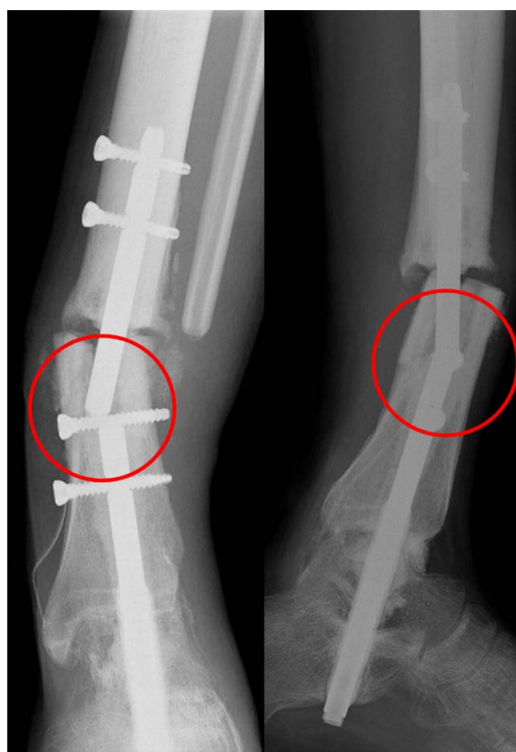

Figure 3. Broken intramedullary nail at 16 months post-operatively.

at room temperature for 15 minutes, then distilled water for 10 minutes and then replaced with reconstruction using an intramedullary nail. However, this broke 16 months postoperatively (**Figure 3**), prompting conversion to plate fixation and an autologous iliac bone graft. There was a nonunion and the plate broke 8 months after fixation (**Figure 4**). Thus, reconstruction was performed using an FVFG. On the left side, a 16 cm segment of the fibula with peroneal artery and vein was harvested. This was then inserted into the right tibial marrow as an inlay graft. Internal fixation using an NCB Distal Femur System (Zimmer, Warsaw, IN) was also performed (**Figure 5**). The peroneal artery and vein were anastomosed to the anterior tibial artery and vein by end-to-end anastomosis. Twenty-four months after the most recent surgery, bridging between the normal bone and the frozen autograft was achieved (**Figure 6**). Remodeling of the frozen autograft is not yet complete, but the patient is able to walk bearing full weight. International Society of Limb Salvage (ISOLS) score was 83.3%.

3. Discussion

Various procedures are used in reconstruction after malignant bone tumor resection including those involving a vascularized bone graft, allograft, recycled autograft (such as autoclaved bone [3], pasteurized bone [4,5],

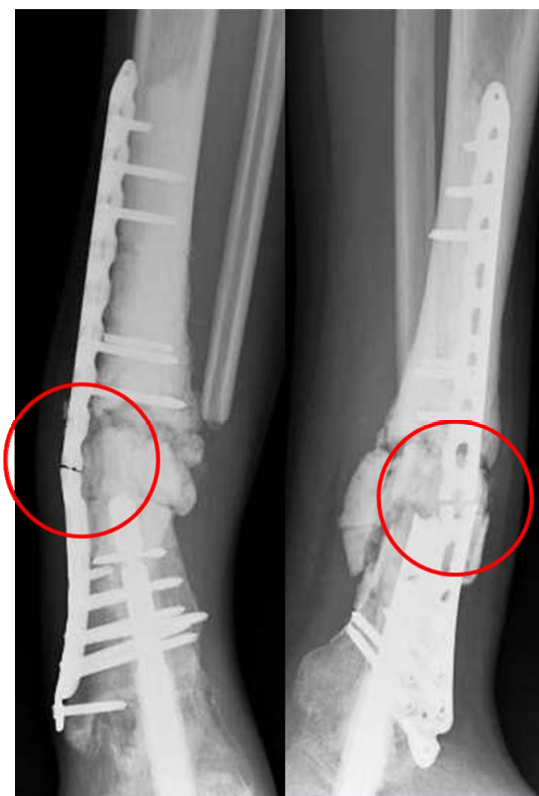

Figure 4. Nonunion and a broken plate 8 months after plate fixation.

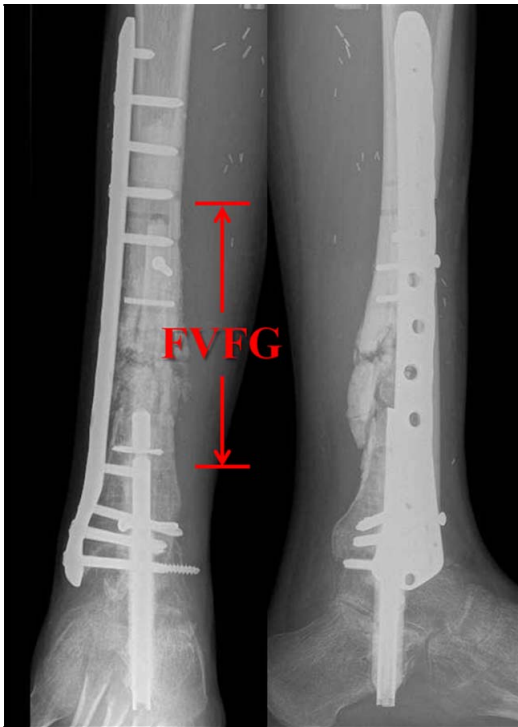

Figure 5. An FVFG was inserted into the right tibial marrow as an inlay graft, and internal fixation using an NCB distal femur system (Zimmer, Warsaw, IN) was also performed.

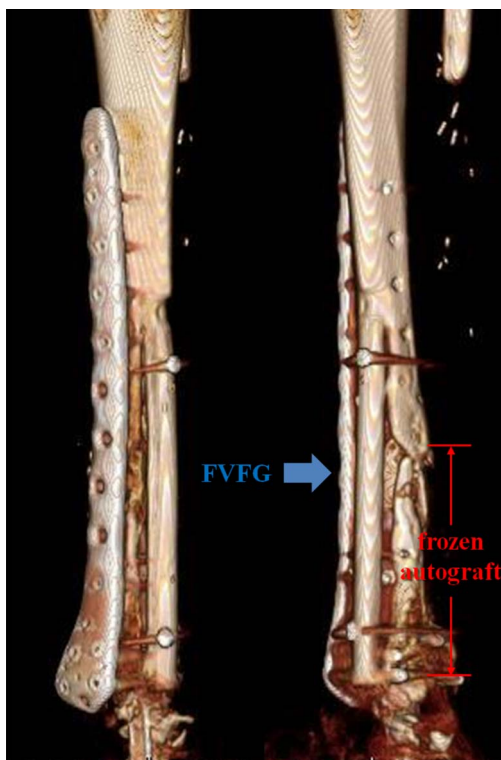


Figure 6. Bridging between the normal bone and the frozen autograft is achieved by 24 months.

irradiated bone [6], and liquid nitrogen-treated bone [1]), prosthesis, and distraction osteogenesis. Allografts are used widely, but are difficult to obtain in some Asian countries for socioreligious reasons, especially in Japan. Currently, for diaphyseal or epiphyseal reconstruction where a defect exceeds 15 cm, we perform aggressive reconstruction using bone treated with liquid nitrogen. In reconstruction using a frozen autograft treated with liquid nitrogen, the bone is exposed or the bone is resected with the tumor and then treated with liquid nitrogen. The tumor cells are killed and no regrowth of tumor is seen using this procedure [7]. The resulting bone is used as a material for reconstruction to fill the defect [1,8]. This reconstruction method is indicated for osteoblastic tumor cases with sufficient bone strength, while prosthetic or allograft reconstruction should be used for osteolytic lesions. The advantages of this method are as follows [8-11]. 1) The techniques are relatively easy and strict temperature control is unnecessary. 2) Liquid nitrogen is inexpensive. 3) The recycled bone is osteoconductive and osteoinductive. 4) Reattachment of soft tissue is easier than attachment of prosthesis. 5) There is immune enhancement or activation after cryotherapy, so-called “cyroimmunity”. Thus, it is thought that the biological activity of the treated bone is preserved at the level of the host bone.

In general, when reconstruction is performed using recycled bone, the delay in revascularization to the recycled bone can result in nonunion and fracture of the recycled bone. Tsuchiya *et al.* reported that when a bone treated with liquid nitrogen was used, bone union and revascularization occurred faster than in bones treated using other methods [8,12-14]. Tanzawa *et al.* histologically examined liquid nitrogen-treated bones removed after grafting. They found that a small area of the bone showed active osteocytes and osteoblasts in a specimen retrieved five months after implantation and osteocytes and osteoblasts were observed in broad portions of frozen bones retrieved more than one year after implantation in three cases, indicating the onset of osteogenesis in the frozen bone at an early stage [14]. However, there are rare cases of nonunion as seen in our patient when liquid nitrogen-treated bone is used. So, what can we do for such cases? Sunagawa *et al.* reported that a vascularized bone graft might aid in the revascularization and osteogenesis of an adjacent liquid nitrogen treated bone in a canine model [15]. Sugiura *et al.* used a combination of a pasteurized autologous bone graft and an FVFG and were able to prevent pseudoarthrosis [16]. To our knowledge there has not been any report that has shown successful bone union using a combination of liquid nitrogen-treated bone graft and FVFG. An FVFG may be able to prevent resorption of bone graft leading to a “bridging

effect” until revascularization, to promote bone union, revascularization of adjacent bones, and to resist infection. When such characteristics are taken into consideration, hybrid-type reconstruction in which a frozen autograft as the rigid structure is reinforced with a vascularized bone graft may be useful. Our department has achieved bone union between a frozen autograft and host bone in 92.8% of cases [1]. Therefore, we do not need to consider one-stage reconstruction with a frozen autograft and FVFG. We consider reconstruction using FVFG may represent an attractive choice for salvage treatment.

4. Conclusion

Reconstruction using FVFG after frozen autograft reconstruction is useful as salvage treatment.

REFERENCES

- [1] H. Tsuchiya, S. L. Wan, K. Sakayama, N. Yamamoto, H. Nishida and K. Tomita, “Reconstruction Using an Autograft Containing Tumor Treated by Liquid Nitrogen,” *British Editorial Society of Bone and Joint Surgery*, Vol. 87, No. 2, 2005, pp. 218-225. [doi:10.1302/0301-620X.87B2.15325](https://doi.org/10.1302/0301-620X.87B2.15325)
- [2] H. Tsuchiya, K. Tomita, Y. Mori, N. Asada and N. Yamamoto, “Marginal Excision for Osteosarcoma with Caffeine Assisted Chemotherapy,” *Clinical Orthopaedics*, Vol. 358, 1999, pp. 27-35. [doi:10.1097/00003086-199901000-00005](https://doi.org/10.1097/00003086-199901000-00005)
- [3] N. Asada, H. Tsuchiya, K. Kitaoka, Y. Mori and K. Tomita, “Massive Autoclaved Allografts and Autografts for Limb Salvage Surgery: A 1 - 8 Year Follow-Up of 23 Patients,” *Acta Orthopaedics*, Vol. 68, No. 4, 1997, pp. 392-395. [doi:10.3109/17453679708996184](https://doi.org/10.3109/17453679708996184)
- [4] J. Manabe, A. R. Ahmed, N. Kawaguchi, S. Matsumoto and H. Kuroda, “Pasteurized Autologous Bone Graft in Surgery for Bone and Soft Tissue Sarcoma,” *Clinical Orthopaedics*, Vol. 419, 2004, pp. 258-266. [doi:10.1097/00003086-200402000-00042](https://doi.org/10.1097/00003086-200402000-00042)
- [5] K. Sakayama, T. Kidani, T. Fujibuchi, J. Kamogawa, H. Yamamoto and T. Shibata, “Reconstruction Surgery for Patients with Musculoskeletal Tumor, Using a Pasteurized Autogenous Bone Graft,” *International Journal of Clinical Oncology*, Vol. 9, No. 3, 2004, pp. 167-173. [doi:10.1007/s10147-004-0391-7](https://doi.org/10.1007/s10147-004-0391-7)
- [6] N. Araki, A. Myoui, S. Kuratsu, N. Hashimoto, T. Inoue, I. Kudawara, T. Ueda, H. Yoshikawa, N. Masaki and A. Uchida, “Intraoperative Extracorporeal Autogenous Irradiated Bone Grafts in Tumor Surgery,” *Clinical Orthopaedics*, Vol. 368, 1999, pp. 196-206. [doi:10.1097/00003086-199901000-00024](https://doi.org/10.1097/00003086-199901000-00024)
- [7] N. Yamamoto, H. Tsuchiya and K. Tomita, “Effects of Liquid Nitrogen Treatment on the Proliferation of Osteosarcoma and the Biomechanical Properties of Normal Bone,” *Journal of Orthopaedic Science*, Vol. 8, No. 3, 2003, pp. 374-380. [doi:10.1007/s10776-002-0626-3](https://doi.org/10.1007/s10776-002-0626-3)
- [8] H. Tsuchiya, H. Nishida, P. Srisawat, T. Shirai, K. Hayashi, A. Takeuchi, N. Yamamoto and K. Tomita, “Pedicled Frozen Autograft Reconstruction in Malignant Bone Tumors,” *Journal of Orthopaedic Science*, Vol. 15, No. 3, 2010, pp. 340-349. [doi:10.1007/s00776-010-1458-0](https://doi.org/10.1007/s00776-010-1458-0)
- [9] M. Hayashi, H. Tsuchiya, T. Otoi, B. Agung, N. Yamamoto and K. Tomita, “Influence of Freezing with Liquid Nitrogen on Whole-Knee Joint Grafts and Protection of Cartilage from Cryoinjury in Rabbits,” *Cryobiology*, Vol. 59, No. 1, 2009, pp. 28-35. [doi:10.1016/j.cryobiol.2009.04.002](https://doi.org/10.1016/j.cryobiol.2009.04.002)
- [10] H. Nishida, N. Yamamoto, Y. Tanzawa and H. Tsuchiya, “Cryoinmunology for Malignant Bone and Soft-Tissue Tumors,” *International Journal of Clinical Orthopaedics*, Vol. 16, No. 2, 2011, pp. 109-117. [doi:10.1007/s10147-011-0218-2](https://doi.org/10.1007/s10147-011-0218-2)
- [11] H. Tsuchiya, K. Sakurakichi, T. Yamashiro, K. Watanabe, Y. Inoue, N. Yamamoto and K. Tomita, “Bone Transport with Frozen Devitalized Bone: An Experimental Study Using Rabbits and a Clinical Application,” *Journal of Orthopaedic Science*, Vol. 9, No. 6, 2011, pp. 619-624. [doi:10.1007/s00776-004-0836-x](https://doi.org/10.1007/s00776-004-0836-x)
- [12] T. Kubo, T. Sugita, S. Shimose, K. Arihiro, H. Tanaka, H. Nobuto, K. Tanaka and M. Ochi, “Histological Findings in a Human Autogenous Pasteurized Bone Graft,” *Anticancer Research*, Vol. 24, No. 3B, 2004, pp. 1893-1896.
- [13] K. Hayashi, H. Tsuchiya, N. Yamamoto, H. Minato and K. Tomita, “Histological Examination of Autoclaved Bone Removed 12 Years after It Was Transplanted,” *Journal of Orthopaedic Science*, Vol. 10, No. 4, 2005, pp. 1006-1011. [doi:10.1007/s00776-005-0903-y](https://doi.org/10.1007/s00776-005-0903-y)
- [14] Y. Tanzawa, H. Tsuchiya, T. Shirai, K. Hayashi, Z. Yo and K. Tomita, “Histological Examination of Frozen Autograft Treated by Liquid Nitrogen Removed after Implantation,” *Journal of Orthopaedic Science*, Vol. 14, No. 6, 2009, pp. 761-768. [doi:10.1007/s00776-009-1392-1](https://doi.org/10.1007/s00776-009-1392-1)
- [15] T. Sunagawa, A. T. Bishop and K. Muramatsu, “Role of Conventional and Vascularized Bone Grafts in Scaphoid Nonunion with Avascular Necrosis: A Canine Experimental Study,” *American Society for Surgery of the Hand*, Vol. 25, No. 5, 2000, pp. 849-859. [doi:10.1053/jhsu.2000.8639](https://doi.org/10.1053/jhsu.2000.8639)
- [16] H. Sugiura, M. Takahashi, K. Nakanishi, Y. Nishida and Y. Kamei, “Pasteurized Intercalary Autogenous Bone Graft Combined with Vascularized Fibula,” *Clinical Orthopaedics and Related Research*, Vol. 456, 2000, pp. 196-202. [doi:10.1097/01.blo.0000246565.03833.73](https://doi.org/10.1097/01.blo.0000246565.03833.73)