

Osteomyelitis of the Skull Base—A Case Report

D. S. Deenadayal, B. Naveen Kumar, B. Vyshanavi*

Department of ENT, Yashoda Hospital, Secunderabad, India

Email: *vyshnavi.jajee@gmail.com

How to cite this paper: Deenadayal, D.S., Kumar, B.N. and Vyshanavi, B. (2018) Osteomyelitis of the Skull Base—A Case Report. *International Journal of Otolaryngology and Head & Neck Surgery*, 7, 139-142. <https://doi.org/10.4236/ijohns.2018.74016>

Received: December 13, 2016

Accepted: July 1, 2018

Published: July 4, 2018

Copyright © 2018 by authors and Scientific Research Publishing Inc.

This work is licensed under the Creative Commons Attribution International License (CC BY 4.0).

<http://creativecommons.org/licenses/by/4.0/>



Open Access

Abstract

Here we report a patient with uncontrolled diabetes, who presented with giddiness and fall due to an episode of seizure. On evaluation with CT and MRI scans, he was found to have pan sinusitis with erosions of the skull base in the floor of sphenoid near lateral recess. PET-CT showed evidence of increased metabolism. He was operated upon by functional endoscopic sinus surgery and debridement of lesion near skull base. The histopathological examination revealed evidence of inflammation with no granulomas or fungal elements or tubercle bacilli. No organisms were grown in microbiological cultures. He started on empirical antibiotics for 3 months and showed improvement. We are reporting this case due to rarity to skull base osteomyelitis.

Keywords

Skull Base, Osteomyelitis, Infection, Cranial Neuropathy

1. Introduction

Osteomyelitis is defined as an inflammatory condition of the bone that commences as an infection of the medullary cavity, rapidly involving the Haversian systems, and eventually involving the periosteum of the infected areas [1].

Osteomyelitis of the skull base is a potentially life threatening condition if it is not diagnosed and treated early. Despite the availability of antibiotics, the occurrence of osteomyelitis is still prevalent in developing countries. Osteomyelitis can be primary osteomyelitis due to hematogenous spread or secondary due to contiguous spread. Most cases of osteomyelitis are of bacterial origin with pseudomonas being the etiological factor while fungal etiology has been attributed in rare cases.

Skull base osteomyelitis is rare. It usually presents with chronic headache with symptoms of associated sinusitis or headache. Diagnosis is established mainly by gallium or Tc 99 scans which also helps to identify the resolution of infection.

CT scan would show demineralization of the bone. Morbidity and mortality can be significantly reduced by early diagnosis and treatment. The mortality rate for this condition is 53% [2]. We are reporting this case due to rarity of occurrence.

2. Case Report

A 48 year old male was first seen at the casualty with complaints of giddiness, fall, loss of consciousness with generalised tonic clonic seizures. He was managed at ER with the appropriate therapy by neurologist. The neurologist identified pansinusitis with permeative lesions of the skull base, middle cranial fossa and referred the patient to us for further management. He is a known diabetic since 10 years with uncontrolled hyperglycemia.

A Complete ENT evaluation was done. Pre operative CT (**Figure 1**) and MRI brain were done which showed pan sinusitis with erosions of the skull base in the floor of sphenoid near lateral recess. MRI brain contrast imaging was done which showed similar findings and the lesion was enhancing with contrast (**Figure 2**). PET CT scan showed increased metabolism suggestive of inflammatory activity. Thereafter patient was taken up for functional endoscopic sinus surgery and debridement of floor of osteomyelitic segment in the floor of sphenoid and lateral recess.

Intraoperative findings showed disease in floor of sphenoid and lateral recess which was debrided and the tissue was sent for routine HPE/Microbiology and

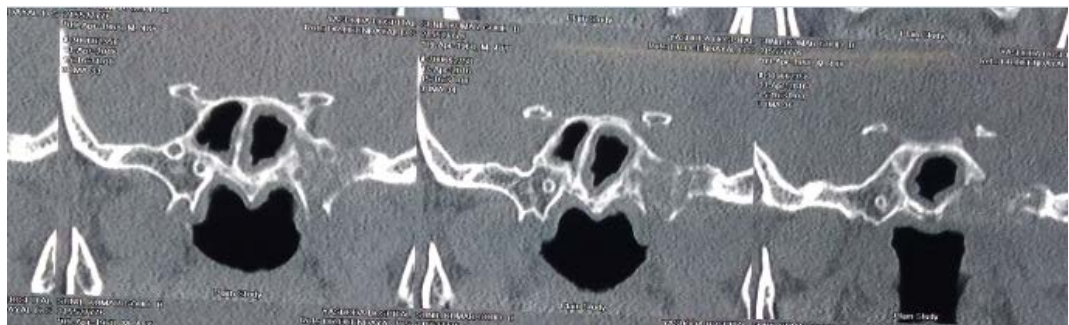

Figure 1. CT scan plain images [Coronal bone cuts] showing erosion of the skull base at the floor of sphenoid and lateral recess.

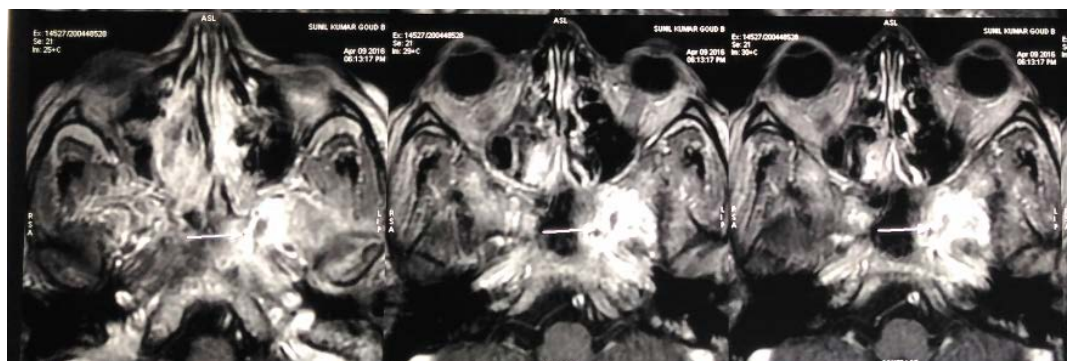


Figure 2. MRI Brain contrast showing evidence of an enhancing lesion in the base of skull near sphenoid sinus and lateral recess.

to rule out TB.

Postoperatively the patient was comfortable with no symptoms. HPE was negative for malignancy and showed evidence of acute inflammatory tissue. But no granulomas or fungal elements or tubercle bacilli were identified. No organisms were grown in microbiological cultures. Microbiology showed negative granuloma and fungus. TB tissue PCR was negative. Patient was advised prolonged antibiotic therapy initially starting with IV antibiotics piperillin-tazobactam (4.5 g IV TID) and IV metronidazole (100 ml IV TID) for 4 weeks. Patient was kept on prolonged course of ciprofloxacin 700 mg BD for 1 month and 500 mg BD for 1 month. Post-operatively, the patient was comfortable and had no new complaints.

Post operative PET Scan done 2 months later showed marginal reduction in the metabolic activity.

3. Discussion

We report a case of osteomyelitis of floor of the sphenoid sinus extending up to the lateral recess. Skull base osteomyelitis can present with headache and a variable combination of cranial neuropathies, most often a combination of VI and lower cranial nerve (CN) neuropathies [3]. Our patient did not present with typical features of headache nor did he have symptoms of chronic sinusitis. Patient presented with giddiness and fall due generalized tonic clonic seizures which is probably due to associated inflammation of the meninges. Etiological factor in this patient could not be identified despite sending the sample of debrided tissue for fungal culture, bacteriological culture and tissue PCR for tuberculosis. Patient responded to antibiotic therapy and surgery. Post operative scan showed improvement with reduction in the metabolic activity. This patient was advised antibiotics for a period of 3 months. Some authors have advised antibiotic therapy for a period of 6 months in patients with chronic osteomyelitis [4].

The imaging findings of osteomyelitis are not specific and can mimic skull base malignancies. Thus accurate histological diagnosis is all the more important [3]. MRI is superior to CT scan for early diagnosis of skull base osteomyelitis. MRI is more useful than CT for soft tissue discrimination and in assessing the extent of disease in all the plains [5]. CT scan with bone windows gives a better idea regarding the extent of bone erosion. Thus both these investigations are complimentary to each other and aid in diagnosis and surgical planning. If CT or MRI results are inconclusive, then a bone scan with high inflammatory markers would be highly suggestive of skull base osteomyelitis.

Skull base osteomyelitis can lead to a number of complications like cranial neuropathy, cavernous sinus thrombosis, meningitis. The infection can spread further leading to brain parenchymal involvement [6]. Cranial nerve involvement occurs due to the proximity of the clivus to the brain stem, basal cisterns, cavernous sinus, and skull-base foramina. But our patient did not have any

cranial nerve palsy.

As described in literature the treatment of choice is debridement with prolonged antibiotic therapy.

We report this case due to rarity of occurrence and no identifiable cause could be found.

4. Conclusion

Skull base osteomyelitis is quite rare. Early identification and treatment reduces the chances of cranial nerve palsy and mortality.

References

- [1] Prasad, K.C., Prasad, S.C., Mouli, N. and Agarwal, S. (2007) Osteomyelitis in the Head and Neck. *Acta Oto-Laryngologica*, **127**, 194-205. <https://doi.org/10.1080/00016480600818054>
- [2] Chandler, J.R., Grobman, L., Quencer, R. and Serafini, A. (1986) Osteomyelitis of the Base of the Skull. *Laryngoscope*, **96**, 245-251. <https://doi.org/10.1288/00005537-198603000-00003>
- [3] Clark, M.P.A., Pretorius, P.M., Byren, I. and Milford, C.A. (2009) Central or Atypical Skull Base Osteomyelitis: Diagnosis and Treatment. *Skull Base*, **19**, 247-254. <https://doi.org/10.1055/s-0028-1115325>
- [4] Strumas, N., Antonyshyn, O., Caldwell, C.B. and Mainprize, J. (2003) Multimodality Imaging for Precise Localization of Craniofacial Osteomyelitis. *Journal of Craniofacial Surgery*, **14**, 215-219. <https://doi.org/10.1097/00001665-200303000-00015>
- [5] Nq, J., Connolly, D.J., Rittley, C.D. and Mordekar, S. (2007) Skull Base Osteomyelitis Leading to Lateral Medullary Syndrome in a Child. *European Journal of Paediatric Neurology*, **11**, 111-114. <https://doi.org/10.1016/j.ejpn.2006.11.003>
- [6] Chang, P.C., Fischbein, N.J. and Holliday, R.A. (2003) Central Skull Base Osteomyelitis in Patients without Otitis Externa: Imaging Findings. *American Journal of Neuroradiology*, **24**, 1310-1316.